MOUNTAIN SPOTTED FEVER

S. BURT WOLBACH

BOSTON

(From the Laboratories of Bacteriology and Pathology of Harvard University Medical School and the Pathological Department of the Peter Bent Brigham Hospital, Boston)

Reprinted from
THE JOURNAL OF MEDICAL RESEARCH, VOLUME XLI.,
No. 1, pp. 1-197, November, 1919

BOSTON
MASSACHUSETTS
U.S.A.

RC 182.S7 H83

Columbia University
in the City of New York

College of Physicians and Surgeons

Reference Library

DUPLICATE
HX00013064

STUDIES ON ROCKY MOUNTAIN SPOTTED FEVER.*

S. Burt Wolbach, Boston.

(*From the Laboratories of Bacteriology and Pathology of Harvard University Medical School and the Pathological Department of the Peter Bent Brigham Hospital, Boston.*)

CONTENTS.

I. Introduction 3

II. Historical Review 4

III. Distribution, Incidence and Mortality 12

IV. Clinical Description 22
1. Definition.
2. Seasonal incidence.
3. Incubation.
4. Symptoms and course. Onset.
5. Temperature.
6. Pulse and respiration.
7. Eruption.
8. Nervous symptoms.
9. Gastro-intestinal symptoms.
10. The urine.
11. The blood.
12. Complications.
13. Types of the disease.
14. Treatment.

V. Previous Work on the Pathology 35
1. Gross pathology.
2. Microscopic pathology.
3. Attempts to demonstrate a parasite.

VI. Immunity 39

* Received for publication July 18, 1919.

VII. The Rocky Mountain Spotted Fever Tick 40
1. Nomenclature.
2. The classification and external anatomy of ticks.
3. Hosts of *Dermacentor venustus.*
4. Biology of *Dermacentor venustus.*
5. Susceptibility of wild mammals to Rocky Mountain Spotted Fever.
6. Infected ticks in nature.

VIII. History and Identity of the strains of virus used 55
1. History.
2. The identity of the strains used.

IX. The Experimental Transmission of Rocky Mountain Spotted Fever by Ticks 62
1. Transmission.
2. The care and feeding of ticks.
3. The intermittent feeding of adult ticks.

X. Dissection and Internal Anatomy of Ticks 67
1. The dissection of ticks.
2. Internal anatomy of *Dermacentor venustus.*
(*a*) The intestinal diverticulæ.
(*b*) The Malpighian tubes.
(*c*) The salivary glands.
(*d*) The female reproductive organs.
(*e*) The brain.
(*f*) The male reproductive organs.

XI. Technic 75
1. Giemsa stain formula.
2. Technic of making smear preparations from ticks and animals.
3. Histological technic.

XII. The Parasite 78
1. The parasite in mammals.
2. The parasite in the tick.
3. The parasite in the eggs of ticks.
4. Summary.
5. Nature of the parasite.
6. Attempts at cultivation.

XIII. Experiments to prove the specificity of the Parasite . . 89
1. Adult ticks proved to be infective.
2. Ticks infected as nymphs, some of which were proved to be infective in the adult stage.
3. Control ticks. Nymphs proved non-infective. First series.
4. Control ticks. Nymphs proved non-infective. Second series.
5. Adult control ticks, proved non-infective.
6. Adult control ticks, not tested.

XIV. Properties of the virus 115
1. Filterability.
2. Resistance to glycerine.
3. Resistance to bile.
4. Resistance to dessication.
5. Preservation in defibrinated and citrated blood.
6. Resistance to heat.
7. Resistance to freezing.

XV. Rocky Mountain Spotted Fever in experimental animals, 120
1. The disease in guinea-pigs.
2. The disease in rabbits.
3. The disease in monkeys.

XVI. Summary of the Pathology in Man 132

XVII. Case Reports 137

XVIII. Summary 179

XIX. Bibliography 187

XX. Description of Plates 193

I. INTRODUCTION.

The studies which have led to this report were undertaken at the joint request of the Montana Department of Health and the Montana State Board of Entomology. The results of original investigations have been outlined in three brief reports in the Journal of Medical Research (xxxiv, No. 1; xxxv, No. 1; and xxxvii, No. 3).

The purpose of this report is to give in detail the protocols upon which the conclusions in regard to etiology are based and to describe the pathology of the disease. Because no recent summary of the many interesting and perplexing features of the disease and connected problems exists, and because of the difficulty of access to the early literature, I have made an effort to include a comprehensive review of all subjects relating to Rocky Mountain spotted fever.

It seems strange that this disease has received so little attention from competent medical investigators. Until the brilliant work of Ricketts it remained a disease of mystery, and to him belongs great credit for discovering the mode of transmission and clearly outlining the work to be pursued which will lead to its complete clarification and prevention.

The occurrence of the disease in sparsely settled mountainous regions restricted to the northwest portion of the United States is largely responsible for the lack of progress towards its solution. It is a disease which could not be studied in well-organized clinics, and even at the present time no complete clinical study has been made. Great credit, however, is due to the pioneer physicians of Montana and Idaho for accurate bedside observations and for their eager coöperation with those who came from a distance to investigate.

With the increasing population of the states afflicted and rising land values, economic considerations will accelerate research. Many difficult and challenging problems present themselves for solution. The transmission by ticks explains the seasonal prevalence and gross distribution of the disease, yet the maintenance of the virus in nature, its great variation in virulence in closely adjacent regions, and its complete absence in tick-infested regions immediately adjacent to infected localities remain unsolved, while the last named is a veritable puzzle where the contrast is so marked as in the case of the east and west sides of the Bitter Root Valley.

II. HISTORICAL REVIEW.

Rocky Mountain spotted fever has without doubt existed in Idaho and Montana ever since the first settlements by white men. There is probable authenic information regarding two cases which occurred in the Bitter Root Valley in 1873, one mentioned by Wilson and Chowning,[68] and one by Stiles.[63] Neither Wilson and Chowning, nor Stiles could obtain evidence that the disease occurred among Indians prior to the coming of white settlers. McCullough,[37] of Missoula, Mont., writing in 1902, says that the Indians were subject to the disease. He mentions the names "black fever" and "blue disease," which the early white inhabitants of the Bitter Root Valley applied to the disease. Michie and Parsons[38] seem to have been more successful in tracing the occurrence back to the Indians. "An old Indian chief of these tribes [Nez Perce and Flathead], who lived many years in the

valley, tells us that at certain times of the year [spring] the Bitter Root Valley was visited by evil spirits, and that it was particularly hazardous to visit certain canyons at this time, as, for instance, Lo Lo Canyon. It is now well known that tick fever appeared very soon after the advent of the first warm days of spring. We also know that there are localities in the valley which are heavily infected, — for example, west of Florence. The connection between facts known at the present day and the statements made by the old Indian chief would indicate that the disease existed in the Bitter Root Valley at least seventy-five years ago. However, there is no authentic report of a case so far back, and there are no records of cases having existed among the Indians."

The early history of the disease is therefore seen to be vague and unreliable. Anderson[1] has tabulated cases, some reported by Wilson and Chowning,[68] occurring in western Montana from 1885 to 1903, but it is evident from the scanty literature that the disease was not common enough to attract much attention until about 1890 to 1895, or during the first period of settlement by whites. That Indians are not immune and occasionally die from the disease is shown in the reports collected by Fricks[21] from Wyoming physicians, in which numerous cases are recorded, with several deaths, chiefly among the Shoshone Indians.

The first written account is in the report of the Surgeon-General of the Army for 1896, by W. W. Wood,[69] then major and surgeon. This account contains no personal observations by Surgeon Wood. It contains data furnished by eight Idaho physicians, C. L. Sweet, W. D. Springer, R. M. Fairchild, G. Collister, T. C. Bowers, J. K. Dubois, D. W. Figgins and H. Zipf; and from their descriptions a very fair account of the clinical course of Rocky Mountain spotted fever may be derived. All regarded "spotted fever" as a distinct disease of unknown cause. It is of interest to note that they apparently regarded the source of the virus as out of doors, and the disease as restricted to the spring months. Dubois suggested the name "exanthesis rosalia arthrodynia." The various appearances of the rash were well described, and

Bowers noted a "sanguineous exudate" into or beneath the corium. As all the cases reported came from Idaho, mostly from the neighborhood of Boisé and from the Snake River Basin, the mortality was stated as low, "very seldom fatal" by Zipf, two to three per cent by Fairchild, and four to five per cent in old age and one per cent or less in children by Collister.

In 1899 an admirable account of "spotted fever" was published by E. E. Maxey,[33] based on cases occurring in Idaho. He defined the disease as "an acute, endemic, non-contagious, but probably infectious febrile disease, characterized clinically by a continuous moderately high fever, severe arthritic and muscular pains, and a profuse petechial or purpural eruption in the skin, appearing first on the ankles, wrists and forehead, but rapidly spreading to all parts of the body." Maxey's account of the signs, symptoms and course of the disease remains one of the best written. He did not mention the occurrence of cases in Montana. Of the pathology nothing was known at that time. Under etiology he discussed the seasonal incidence — spring months — and the characteristics of infected localities, their proximity to the mountains, streams and melting snow, and concluded that the causative agent was in the water or soil over which it ran, — a belief still held by inhabitants who refuse to accept the fact of tick transmission. Prognosis favorable, sums up his estimate of the mortality of the disease in Idaho.

Although a much more deadly type of "spotted fever" had been recognized for many years in the Bitter Root Valley, the first account of the disease in that region was published in July, 1902, by McCullough[37] (Wilson and Chowning's[67] preliminary report was also published in the same month). His description is brief and applies to the more virulent disease of the locality, and he quotes the following series of cases, one near Victor of sixteen cases with twelve deaths, one near Stevensville of forty cases with thirty deaths, and his own experience with thirty-six cases in a period of twelve years with a mortality of seventy-five per cent.

At this date, 1902, the disease was recognized in Montana as a serious obstacle to the settlement of valuable agricultural lands in the Bitter Root Valley. There was complete ignorance of all factors, except that of season and locality, regarding transmission. Water from melting snow and the rotting sawdust of lumber camps were supposed to carry and engender the cause of the disease. Physicians dreaded the care of cases because of their absolute helplessness in treatment, and the settlers because of the deadly and mysterious nature of the disease.

The first serious investigation was begun in this year by Wilson and Chowning,[68] who were engaged by Dr. H. F. Longeway, Secretary of the Montana State Board of Health, "to investigate the nature, causation and means of prevention of the disease," and their work, while leading to some erroneous conclusions as to etiology, contributed many valuable facts, particularly as to pathology and epidemiology, and furnished provocative stimulus for subsequent research. They obtained records of one hundred and twenty-six cases with a mortality of eighty-seven per cent, and made the first post-mortem examinations and study of the blood during life. They called attention to the occurrence of the disease in Nevada and Wyoming. Most important, however, was their conclusion that the disease is transmitted by the wood tick of the locality, then identified as a new species of *Dermacentor* by Stiles. This conclusion was based partly upon shrewd and sound observations of individual case histories and the epidemiology of the disease, and upon the finding of a supposed intracorpuscular protozoan parasite, a *Piroplasma* identified as similar to that known to be the cause of Texas fever in cattle and transmitted by a tick. Their illustrations depict bodies unlike any known inclusion or artefact in human blood, and convincingly similar to known types of *Piroplasma*, or *Babesia*, yet this part of their work did not prove valid and their findings are still unexplained. This "organism" was named by them "*Pyroplasma hominis*" and the disease "*Pyroplasmosis hominis*." Similar parasite-like bodies were

seen by them in the blood of the burrowing squirrel or ground-squirrel, *Sphermophilus* (Citellus?) *columbianus*, and this animal was accordingly regarded as a third host of "*Pyroplasma hominis*" — a supposition in accordance with distribution, seasonal habits and tick-host capacity of the burrowing squirrel. They made experimental inoculations into pigeons and rabbits, and found in the blood of the latter the piroplasma-like bodies. They noted little in the way of disease symptoms in the rabbit, but, as enlargement of the spleen was found in two which were autopsied, it is evident that they did, in the light of recent work with rabbits, transmit the disease to this animal.

The first Federal participation in the study of Rocky Mountain spotted fever began in 1903, when Passed Assistant Surgeon John F. Anderson, of the Public Health and Marine Hospital Service, was detailed by Surgeon-General Wyman to make investigations in Montana. Anderson[1] confirmed the finding of *Piroplasmata* in the blood of patients, and supported the tick transmission theory of Wilson and Chowning. He noted the occurrence of the disease in Oregon in addition to the other states previously mentioned, — Montana, Idaho, Nevada and Wyoming. The title of his report — "Spotted Fever (Tick Fever) of the Rocky Mountains — a New Disease" — marks the acceptance of the present nomenclature; Wilson and Chowning used the same expression, "spotted fever" or "tick fever of the Rocky Mountains," it being clear to all that this eruptive fever was restricted to and peculiar to the Rocky Mountain states.

The tick transmission theory aroused considerable local opposition in Montana, partly from an honest disbelief on the part of physicians who occasionally failed to get evidence of tick bites from their cases, and chiefly from those interested in the economic development of the infected localities. This impression I gained from my visit to Montana in 1917, while Ashburn[2] in 1905, speaking of the tick theory, says: "Economically, I think it is safe to say it has been more disastrous to the infected region than the disease itself. Ticks are so common it is nearly impossible for a man working

out of doors to avoid their bites, while at the same time they, if causing the disease, constitute a cause so tangible and real that the dissemination of this hypothesis excited a fear closely akin to terror. Land values were affected, probably a majority of the people on the west bank of the Bitter Root River desiring to sell and nobody willing to buy. Sawmills have been unable to procure a sufficiency of hands, and some families have sacrificed their property in order to get away as soon as possible. People who formerly frequented that region for business or pleasure could in most instances not now be induced to go there, except on most urgent business, during the tick season."

In the spring of 1904, Ch. Wardwell Stiles, Chief of Division of Zoölogy, Hygienic Laboratory, United States Public Health and Marine Hospital Service, was detailed by Surgeon-General Wyman to study the disease "from a zoölogical point of view." The special purpose of his detail was to "trace the life cycle of the parasite ('*Piroplasma hominis*') which has been described as the cause of the disease, to study the tick which was supposed to transmit it, and to trace the disease in the burrowing squirrel in which it was thought to originate." The report of Stiles[63] contained the most complete summary of knowledge of the disease that had been written. His refutations of all of Wilson's and Chowning's conclusions were so emphatic that they savored of scorn. In the first place, he, aided by Captain Ashburn, could not demonstrate the *Piroplasma* in blood preparations made by them from typical cases or in slides sent by Wilson and Chowning. Chowning, in person, was unable to demonstrate the parasites to Stiles in the blood of a typical case. In the second place, Stiles could not find the parasites in the blood of inoculated rabbits and failed to transmit the disease to rabbits in three tests from three different typical cases. Maintaining as he did that the tick theory was a secondary hypothesis "based upon the idea that 'spotted fever' is caused by a protozoan," Stiles may have been justifiably prejudiced by his failure to find the protozoan and made hazardous use of analogy in disposing of the tick theory.

The climatological observations made by him are interesting in the light of our present knowledge of the habits of the tick (*Dermacentor venustus*). Stiles noted that the incidence of cases was highest during the first warm days of spring, and decreased later when the snow had melted. The retirement of ticks during the hot days of July apparently escaped Stiles's notice, for he concluded that "such as the data are, they tend to support rather than to negative the popular idea that the melting of snow has some direct or indirect connection with the development of cases; or at least they tend to show that conditions which favor the melting of snow also favor the appearance of cases of spotted fever."

Captain Ashburn in 1905 stated with force his belief in the disproof of the tick transmission theory. While Stiles was justified in not accepting as proved Wilson's and Chowning's deductions in regard to tick transmission, and advanced equally logical contrary evidence, subsequent research has proved the correctness of the tick theory, the susceptibility of rabbits and the importance of the ground squirrel as a host of the virus of spotted fever.

Properly organized laboratory investigation of Rocky Mountain fever began in the spring of 1906, when H. T. Ricketts, of the University of Chicago, went to Montana. At the same time Passed Assistant Surgeon W. V. King, of the Public Health and Marine Hospital Service, was detailed to investigate the disease in Nevada, and these two brilliant workers coöperated for a time along lines of research directed by Ricketts. Ricketts speedily announced the transmission, by inoculation of blood from human cases, of the disease to monkeys and guinea-pigs with the production of characteristic symptoms and lesions and fatal effect.

In July of the same year King [28] and Ricketts [48] independently transmitted the disease to guinea-pigs by means of the tick (*D. venustus*). Thus in a few months the methods of investigation of this disease were blocked out. In the investigation of the disease for several years following Ricketts remained preëminent and pursued his work with brilliancy and keen foresight.

A period also followed of work done by the United States Public Health Service in the study of the biology of the tick and of methods of tick control as leading to the most direct means of prevention of the disease. Of the workers engaged, King, McClintic, Rucker and Fricks, several exhibited considerable heroism in exposing themselves to the disease, and McClintic contracted the disease in the summer of 1912, while at work in the Bitter Root Valley, and died. During this time the state of Montana supported in part the work of Ricketts, and under the leadership of Professor R. A. Cooley conducted valuable investigations in part in coöperation with the Federal Bureau of Entomology, upon the problems of tick control.

To return to the work of Ricketts and his assistants (Contributions to Medical Science, by Howard Taylor Ricketts. Univ. of Chicago Press, 1911) between 1906 and 1919, we have to record the establishment of most of the facts now known about the transmission of the disease. The transmission by ticks, the demonstration of infective ticks in nature, the hereditary passage of the virus through generations of ticks, and important facts regarding immunity, were the product of his work. He also saw the microörganism which is now shown to be the cause of the disease, but unfortunately confused it with bacteria which may be present in non-infective ticks.

Remarkable transmission experiments with ticks on man were made in 1905 by L. P. McCalla,[35] of Boisé, Ida., but were not published until 1908. McCalla removed a tick from a spotted-fever patient, and with consent of the subjects of the experiments, allowed it to feed for forty-eight hours upon the arm of a man and immediately after removal upon the leg of a woman, where it remained attached over ten hours but under twenty-four hours. In the case of the man there was an incubation period of nine days, when a typical case of spotted fever of "medium severity" ensued, with the fever lasting "about eight or nine days." The incubation period in the woman was three days. The fever, rising to 101° F., lasted four or five days and was accompanied by a

rash, and the case was regarded as a typical "mild case." These experiments, antedating the transmission experiments of Ricketts and King, are the only recorded instances of tick transmission from man to man.

III. DISTRIBUTION, INCIDENCE AND MORTALITY.

The distribution of Rocky Mountain spotted fever is that of its carrier, the wood tick *Dermacentor venustus*, although as yet no case has been reported from New Mexico. (Maps

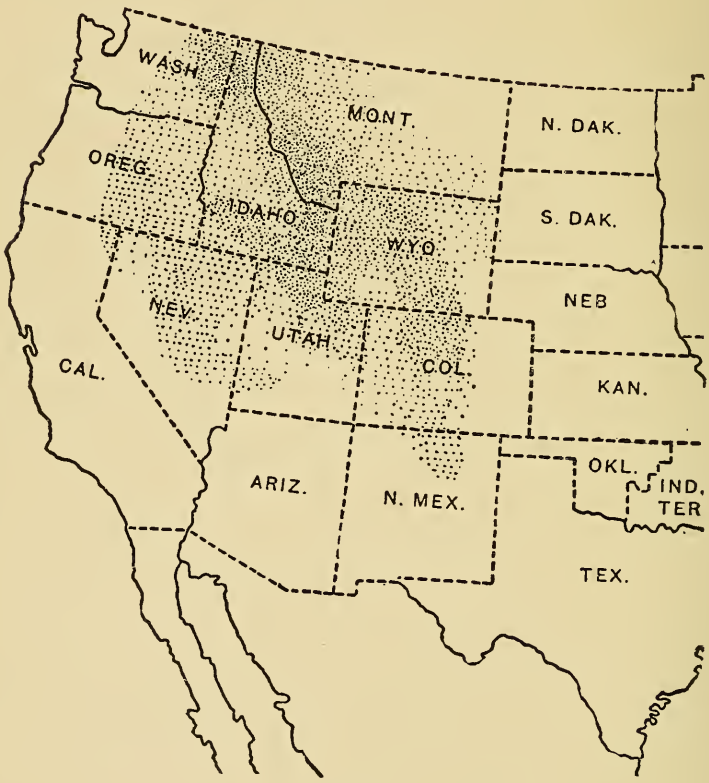

MAP 1.

Map showing the distribution of the Rocky Mountain spotted fever tick (*Dermacentor venustus*). The degree of shading indicates the relative abundance of the tick in different sections.

Reproduced from Hunter and Bishopp. United States Department of Agriculture, Bureau of Entomology, Bulletin No. 105.

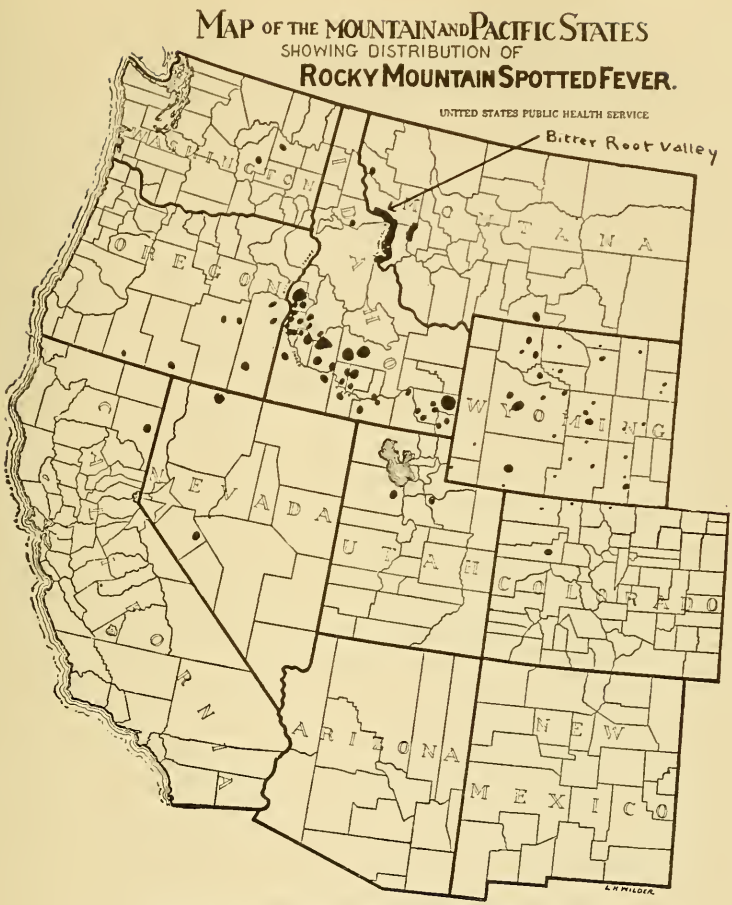

The dots indicate areas of infection reported previous to 1915.

MAP 2.

Reproduced from United States Public Health Reports, xxx, 3, 1915.

1 and 2.) The states in which cases have unquestionably originated are Idaho, Montana, Nevada, Oregon, Utah, Wyoming, California, Colorado and Washington. It has been asserted that the disease occurs in Alaska, but I can find no proof of this. Two cases were reported from South Dakota in 1915 (U. S. Public Health Reports).

It is not possible in general to determine whether the disease is spreading over wider territories from year to year,

as in some states the disease is not reportable and no wholly reliable records are obtainable from any source from any state. Anderson,[1] in 1903, records cases from Montana, Idaho, Nevada, Wyoming and Oregon. Stiles [63] in 1905 adds Utah and possibly Alaska. In 1911 cases were reported from California in the Public Health Reports, but Kelly[29] has shown that the disease was recognized there as early as 1903. Washington appeared as a source of spotted-fever cases in the Public Health Reports for 1914, and Colorado in 1915. This sequence probably has no significance, as the sparsely settled conditions of these states and the remoteness of the infected regions from large towns would tend to prevent the reporting of such few cases as may have occurred in earlier years. However, in Montana, in the spring of 1915, the disease appeared suddenly in several counties in the eastern part of the state, where its presence certainly would have been known had it existed prior to that time. The mortality in eastern Montana is much lower than in the Bitter Root Valley, but higher than in Idaho. Cooley's[11] conclusion that the disease is spreading in Montana seems warranted and it will be interesting to follow further developments in this and other infected states.

The distribution of cases in the various states is characteristically restricted to certain localities. This is shown strikingly by the Maps 3 and 4, taken from the Public Health Reports for January 15, 1915. Idaho furnishes the best example, where the grouping of cases in certain counties in the Snake River Valley clearly indicates the presence of definite foci of infection. In Montana prior to 1915 the disease was practically restricted to the west side of the Bitter Root Valley, and although it has since appeared in eastern Montana, the east slope of the Bitter Root Valley remains free of the infection. Some of the factors probably responsible for this peculiarly focal distribution of the virus in nature will be discussed in another portion of this paper. One thing seems certain, which is that the reservoir of the virus is some animal other than man.

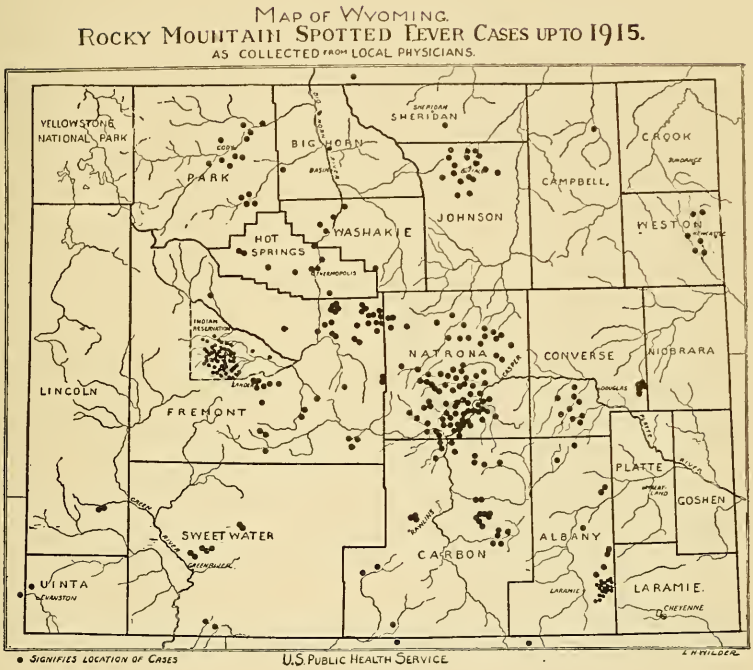

MAP 3.

Map showing distribution of Rocky Mountain spotted fever cases in Wyoming.

Reproduced from United States Public Health Reports, xxx, 3, 1915.

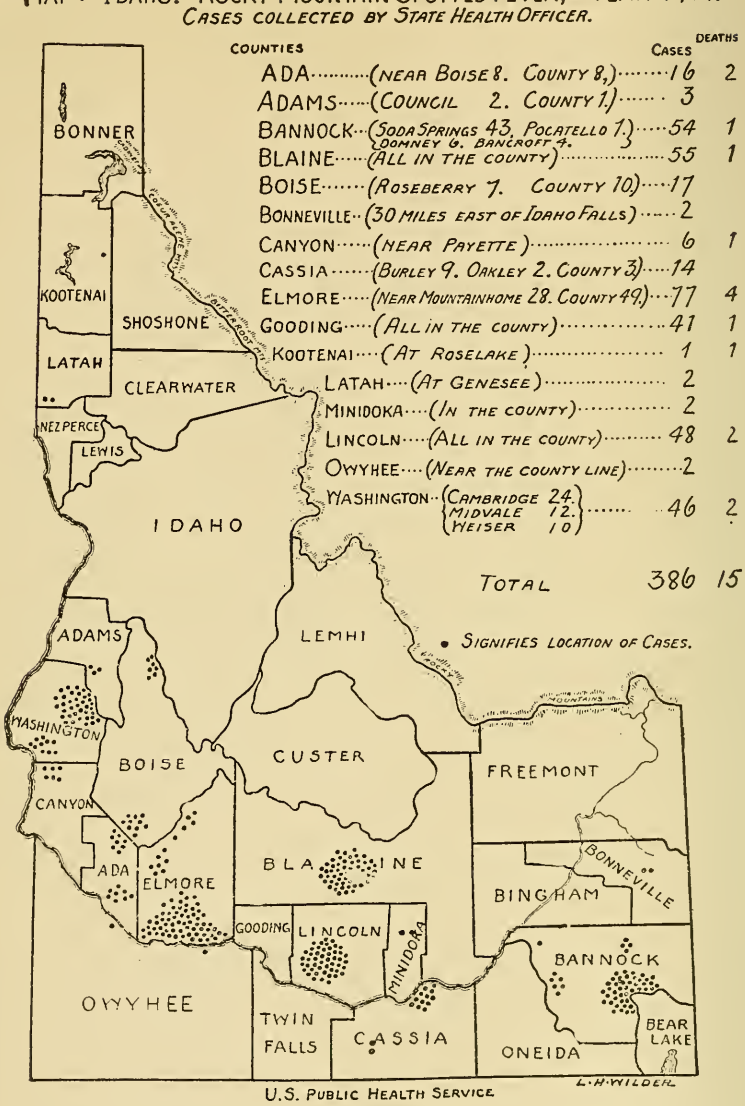

MAP 4.

Map showing distribution of Rocky Mountain spotted fever cases in Idaho in 1914.

Reproduced from United States Public Health Reports, xxx, 3, 1915.

Wilson and Chowning,[68] in 1903, had obtained histories of one hundred and twenty-six cases which occurred in Montana since 1885, with eighty-seven deaths, a mortality of about sixty-nine per cent, including all ages and both sexes. Their table is worth reprinting here.

	Males.			Females.			
	Died.	Recovered.	Total.	Died.	Recovered.	Total.	Total Both Sexes.
Under five years	4	4	8	5	0	5	13
Five to ten years	5	1	6	4	3	7	13
Ten to twenty years	5	3	8	5	6	11	19
Twenty to thirty years	13	4	17	3	4	7	24
Thirty to forty years	19	5	24	7	4	11	35
Forty to fifty years	6	2	8	1	1	2	10
Fifty to sixty years	2	1	3	1	1	2	5
Sixty to eighty years	4	0	4	2	0	2	6
Age not stated	1	0	1	0	0	0	1
Total	59	20	79	28	19	47	126

The age incidence in this table is probably to be explained on other grounds than that of susceptibility. In the first place, in all newly settled districts the young outnumber the old, and again, as the disease is contracted out of doors, occupations calling for exposure necessarily call for the young and vigorous. Stiles[63] collected eleven cases in the Bitter Root Valley in 1904, with nine deaths. Maxey,[34] in 1908, estimated the number of cases occurring annually in Idaho as over three hundred and seventy-five. In 1907 there were three hundred and sixty-three cases reported to the Idaho State Board of Health from about one half of the physicians of the state who responded to the inquiry. The mortality was estimated as 4.86 per cent; in certain localities, however, the mortality may have been higher, and in his conclusions Maxey states that the mortality varies from 4.8 to 11.4 per cent. These figures are, upon consideration of the character of the data offered, obviously mere approximations. The Idaho disease is stated to be rarely fatal in children and adults, and quite fatal in the aged.

The following table of cases in the Bitter Root Valley, from 1885 to 1911 inclusive, representing data collected by Wilson and Chowning, Anderson, Stiles and McClintic, was compiled by Assistant Surgeon-General Rucker.[58]

United States Public Health Reports, xxvii, No. 36, 1912.

Year.	Cases.	Deaths.	Case Fatality Rate Per Cent.
1885	1	1	100
1886	1	1	100
1887	0	0	0
1888	3	1	33.3
1889	3	3	100
1890	1	1	100
1891	6	4	66.6
1892	3	1	33.3
1893	4	2	50
1894	0	0	0
1895	3	3	100
1896	6	6	100
1897	6	5	83.3
1898	3	2	66.6
1899	23	14	60.8
1900	12	9	75
1901	14	10	71.4
1902	21	15	71.4
1903	14	9	64.2
1904	11	9	81.8
1905*	..	..	....
1906*	..	..	...
1907	..	..	....
1908	12	5	41.6
1909	28	13	46.4
1910	19	14	73.6
1911	16	6	37.5
1912	1	1	100
Date not known	4	2	50

* The Third Biennial Report of the Montana State Board of Health gives ten deaths between June 30, 1905, and June 30, 1906. No data can be found covering the spring of 1905 and for the year of 1907.

The following data (R. A. Cooley) are available from Montana[12] (Montana State Board of Entomology, Third Biennial Report).

Cases in the Bitter Root Valley.

Year.	Ravalli County.	Missoula County.	Total.
1913	0	0	11
1914	6	4	10
1915	3	5	8
1916	5	1	6
1917	5	1	6
1918	2	1	3

Cases in other localities in Montana.

Eastern Counties.	1915.	1916.	1917.	1918.
Custer	8	1	..	..
Dawson	6	4	2	..
Rosebud	5	1	..	..
Big Horn	1	..	..	..
Fallon	2	..	..	..
Musselshell	..	2	2	..
Yellowstone	..	1	3	..
Fergus	..	1	3	..
Phillips	..	1	..	..
Stillwater	..	..	2	..
Scattering cases.				
Carbon	3	1	1	2
Gallatin	2	..	..	..
Cascade	1*	..	..	..
Madison	..	..	2	1
Total	28	12	15	3

* This case originated in Idaho.

The mortality of these cases is not given; however, in the Public Health Reports compiled by Fricks,[19, 24] we find for Montana the following statistics: 1917, twenty-five cases, no deaths recorded; 1916, nineteen cases with six deaths; 1915, thirty-eight cases, no deaths recorded; 1914, ten cases, no deaths recorded; 1913, eight cases with seven deaths; 1912, twelve cases with nine deaths; 1911, seventeen cases with six deaths. The Federal figures are obviously less accurate than those of the state, as frequently I have been able to ascertain the double reporting of a single case. According to

Michie and Parsons[38] there were in 1912 eight cases in Montana, with seven deaths. Of the twenty-two cases in eastern Montana in 1915, there were two deaths (Cooley[11]). Of the six cases in the Bitter Root Valley in 1917, five died.

The following table of cases includes all those reported in the Public Health Reports since 1911, when the first records of Rocky Mountain spotted fever appear. The mortality statistics are very irregularly and probably inaccurately stated, and the reason is probably the desire of each community to conceal the fatalities. This intention becomes obvious to any one upon residence for a time in such a region. The Public Health Reports data have been verified, and in several instances corrected by consultation of the State Board of Health Reports of Nevada, Washington, Montana, Oregon, Idaho and Utah.

The California statistics for 1911 to 1915, inclusively, are taken from the report of F. L. Kelly,[29] to whom I am also indebted for the 1917 and 1918 figures (personal communication).

From Michie and Parsons[38] we learn that there were in Nevada twenty-one cases between 1911 and 1914 inclusive, without fatality.

If we take the years 1916 and 1915, for which we have the most complete returns, we find a total of 295 cases for 1916 and 563 cases for 1915. These figures undoubtedly are probably far below the true number. Hunter and Bishopp[27] regard 750 cases a year with seventy-five deaths as a conservative estimate.

The mortality rate is impossible to determine. In the Bitter Root Valley the percentage is probably above seventy, as estimated by Wilson and Chowning.[68] Estimated for all other states in the years 1916 and 1915, where deaths have been recorded, it is, for 1916, 12.93 per cent and for 1915, 7.15 per cent. The discrepancies between these figures illustrate the absurdity of attempting to calculate the mortality from the published data. It is probably safe to say that the mortality outside of the Bitter Root Valley averages somewhere between 7.15 and 13.0 per cent.

	1918.	1917.	1916.*	1915.	1914.	1913.	1912.	1911.	1910.
Nevada		13	20 2 deaths.	8	9 No deaths.	6 1 death+?.	11	14	
Washington		5	3	8	2 1 death.	6 1 death+?.	3		
Colorado		6	5 1 death.	14					
Montana	6	21	19 6 deaths.	37 8 deaths.	12 7 deaths.	11†	12 9 deaths.	17 6 deaths.	11 deaths.
Wyoming		13	26 8 deaths.	59 8 deaths.	26 4 deaths.	4 4 deaths.			
Oregon		2	26 4 deaths.	29 6 deaths.	6 3 deaths.	9 deaths.			
California	3	4	11	11 2 deaths.	2	2	3 1 death.	3 1 death.	
Idaho			151 11 deaths.	360 10 deaths.	386 15 deaths.	258 8 deaths.	197 6 deaths.	334 9 deaths.	223 8 deaths.
Utah‡		15	34	35 4 deaths.					
South Dakota				2					

* These figures are from Fricks' report, Pub. H. Report, September 21, 1917.
† Of eight cases reported by Fricks, Pub. H. Bull., February 20, 1914, there were seven deaths.
‡ Utah — Personal communication from T. B. Beatty, M.D., state health commissioner.

It is impossible to dismiss the subject of incidence and mortality without the comment that the Federal Public Health Reports records of Rocky Mountain spotted fever are valueless and that, as given in recent years, can fulfill no purpose whatsoever.

There are also marked discrepancies between the figures for certain years as published by Fricks,[19,24] and those by Kelly[29] for California, and those for Montana in the Third Biennial Report of the State Board of Entomology. In the face of such differences, I have chosen the latest report on the cases for the years in question, such figures being in most instances the highest and presumably, therefore, the most complete.

IV. CLINICAL DESCRIPTION.

1. Definition. — In 1899 Maxey[33] defined "Rocky Mountain spotted fever" as "an acute endemic, non-contagious but probably infectious febrile disease, characterized clinically by a continuous, moderately high fever, severe arthritic and muscular pains, and a profuse petechial or purpural eruption in the skin, appearing first on the ankles, wrists and forehead, but rapidly spreading to all parts of the body."

In view of the researches here presented, the following definition becomes more appropriate: An acute specific infectious endangeitis, chiefly of the peripheral blood vessels, transmitted by a tick, *Dermacentor venustus*, and characterized by onset with chill, continued fever, severe pains in bones and muscles, headache and a macular eruption becoming petechial, which appears first on wrists, ankles and back, then over the whole surface of the body.

2. Seasonal incidence. — The disease occurs almost wholly in the spring months corresponding to the period of activity of the ticks. The first cases appear usually in March after the melting of the snow, and the number of cases increases as the number of active adult ticks increases. May and June are the months of greatest incidence. Few cases occur

during July, while very rarely a case occurs in August, September and October. These late cases are probably contracted at high altitudes, from ticks which have emerged late from hibernation following melting of the snow.

3. Incubation. — In McCalla's[35] experiment upon two humans, the incubation periods were three and nine days. Stiles[63] records four cases where the onset of the disease occurred once on the fifth day, twice on the sixth day and once on the seventh day after the discovery of the tick. In many guinea-pig experiments I have found the shortest incubation period to be between three and four days after attachment of the tick, the longest period seven, the usual period from four to five days. As Ricketts and Moore[39] showed that the average duration of feeding necessary for a tick to infect is about ten hours (the shortest period being about two hours) and as the guinea-pig is probably more susceptible than man, incubation periods in man reported as less than three days are probably incorrect.

Wilson and Chowning[68] give two to eight days (five cases of two days, one each of three, five, six, seven and eight days, two cases determined as between the second and fifth days). Anderson,[1] three to ten days; Ashburn,[2] two to eight days; Stewart and Smith,[62] five to seven days; Rucker,[58] three to ten days; Fricks,[23] two to twelve days, usually four to seven days; and Michie and Parsons,[38] three to eight days.

Three to twelve days are probably the limits of the incubation period. It is certain that most cases develop between the fourth and eighth days after discovery of the feeding tick.

4. Symptoms and course. Onset. — The onset of the disease is usually accompanied by a chill, though there may be a few days of *malaise* with loss of appetite accompanied by chilly sensations before a frank chill occurs. This latter mode of onset is more common in Idaho than in Montana, and must be in some way related to the less fatal course of the disease in Idaho. There is nothing peculiar in the behavior of the lesion caused by the bite of an infected tick as compared

with that of a non-infected tick. From the start there are severe general pains referred to the bones and muscles, back and joints. Pains in the calf muscle and large joints and lumbar region of the back are the most prominent. Headache is common and is usually severe. The face is flushed, the conjunctivæ injected, the tongue white and coated, with moist red tip and edges and there is constipation. The patient is usually ill enough to take to his bed on the second day of symptoms. There may be epistaxis, and there usually is photophobia. A very common symptom is a short cough without sputum, evidently due to bronchial irritation.

5. Temperature. — The temperature before the initial chill is not high; there is a slight evening rise only. After the

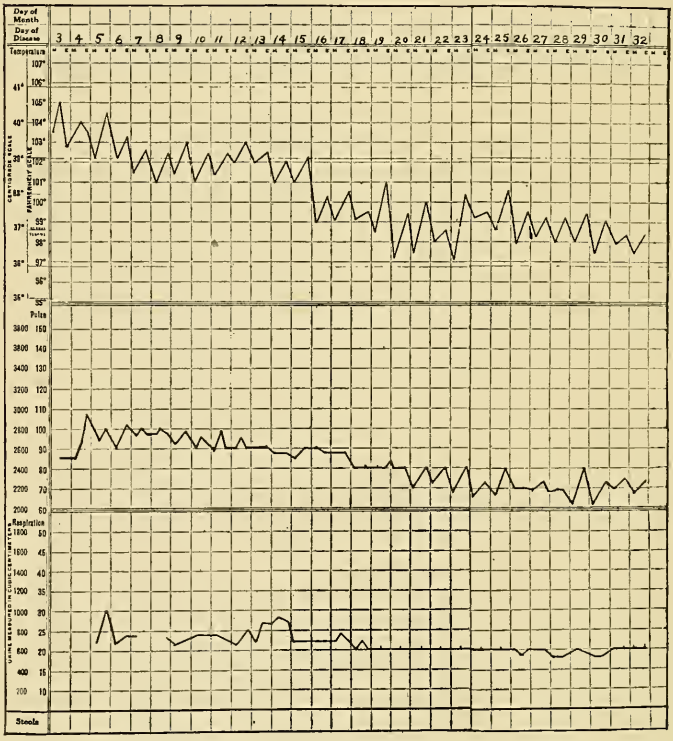

Charts of temperature, pulse and respiration from a case of Rocky Mountain spotted fever with recovery. Male, Albert M., age 16. From Michie and Parsons.

chill the temperature rises fairly rapidly and reaches 102° F. to 104° F. in the second day, and continues to rise gradually to a maximum of 104° F. to 105° F. during the second week. In severe cases, in the Bitter Root Valley, the temperature reaches 106° F. to 107° F. and may remain this high until death. The maximum temperature is reached more quickly in the virulent Montana cases than in the Idaho type of the disease.

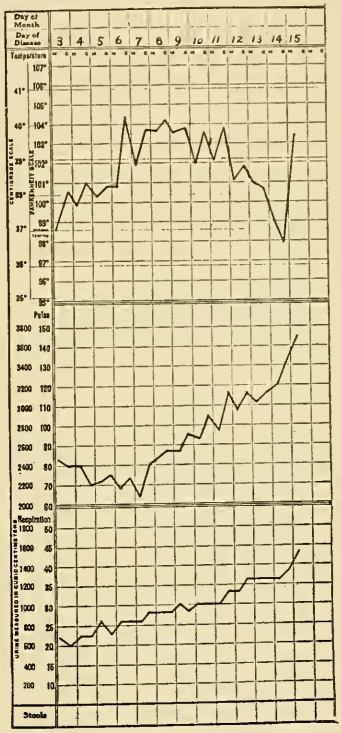

Charts of temperature, pulse and respiration illustrating a fatal case of Rocky Mountain spotted fever. Case CXX., male, E. M., age 28. Reproduced from data published by Anderson.

The maximum temperature persists during the second week of the disease, with slight morning drops. In cases which recover, the temperature begins to lower at about the end of the second week and falls by lysis so that normal temperature is reached on about the end of the third week. The

temperature may go to 98° F. or below for a few days after recovery. In fatal cases the temperature may drop to normal or subnormal and then rise eighteen to twenty-four hours before death. Death in the severe cases such as occur in the Bitter Root Valley usually takes place between the sixth and twelfth days of the disease, or from three to seven days after the eruption appears. Thus, in ninety-six fatal cases where data are available, seventy-nine died between the sixth and twelfth days of the disease (Stiles[63]). Fifty-three of seventy-two fatal cases died between the third and seventh days of the rash.

6. Pulse and respiration. — The pulse at first is full and strong, but gradually loses volume and strength and increases in rapidity out of proportion to the temperature. The same applies to the respirations, which become very rapid and shallow in severe cases. The pulse ranges from 110 to 140 and may reach 150 a few days before death. A pulse of 120 with a temperature of 102° F. is not uncommon. The respirations usually are from thirty to forty a minute but may rise to sixty before death. A rapid increase in rate of pulse and respiration is of decidedly bad prognostic significance.

7. Eruption. — The rash appears usually on the third, fourth or fifth day of fever, most often on the third day. It may show as early as the second or as late as the seventh day of temperature. There is very marked uniformity in the statements of all authors in respect to the development and characteristics of the rash. It shows first on the wrists, ankles and back, then forehead, arms, legs and chest, and lastly upon the abdomen, where it is always least marked. It takes about twenty-four to thirty-six hours for the efflorescence of the rash, though later than this the palms of the hands, soles of the feet, the scalp and the mucosa of the cheeks, palate, pharynx and fauces may become sites of the eruption. With the coming of the rash the general aches and pains ameliorate but the temperature is not appreciably affected.

The rash consists at first of rose-colored macules not elevated, in size from less than one to four or five millimeters in diameter and disappearing upon pressure. Rarely the skin is tender at the sites of the spots. The spots soon become deep red or purplish and increase in size, often becoming confluent, thus giving a diffuse marbled appearance to the skin. After several days' duration some of the spots no longer disappear upon pressure (sixth to tenth day of the disease) and then the rash becomes distinctly petechial in character. In severe cases areas of cutaneous and subcutaneous hemorrhage of considerable size occur, and frequently the skin assumes a glazed appearance in the second week of the disease. A peculiarly dusky reddish or bluish mottling of the skin of the thighs may occur, and is due to stasis of blood in the subcutaneous vessels.

If the rash does not become confluent, the thickly distributed, discrete red or reddish-brown spots give an appearance to the skin which several Idaho physicians have compared to the markings of a turkey's egg.

Icterus appears in the second week of the disease, but is never very marked.

The rash begins to disappear with the subsidence of fever but the site of the petechiæ is long indicated by pigment spots. In severe cases, in the third week, necrosis of the skin of certain dependent parts frequently occurs. As will be seen from the pathology of the disease, this necrosis is secondary to occlusion of blood vessels, and is therefore necessarily a late effect and accordingly is more common in Idaho than in the Bitter Root Valley. The skin necrosis is most common of the scrotum, prepuce, fingers, toes and lobes of the ear. Necrosis also may affect the soft palate (Stewart and Smith[62]).

Desquamation follows recovery, and extends over the whole body, but is slight except where the skin lesions were most marked. In exceptional cases casts over sites of large hemorrhages from the palms and soles may be formed (Stewart and Smith[62]). Maxey[33] describes on the palms and soles the common formation of discrete, white areas of dead epidermis,

corresponding to areas of cuticular hemorrhages, which on being picked off leave shallow depressions in the skin. Lesions indicating the former sites of the petechiæ may persist for weeks and months and become demonstrable after chilling the skin, or after severe exercise or a hot bath. It is incorrect to speak of this as a persistence of the rash — the effect is undoubtedly due to cicatrices and local obliteration of the capillaries of the skin.

8. Nervous symptoms. — Restlessness and insomnia are very common throughout the disease, and are among its most distressing features. Hyperesthesia is frequent and often very severe, the slightest touch, movement of the bed or even the weight of the bedclothes may cause extreme pain.

Delirium is usual in severe cases during the height of the fever and coma usually precedes death by a few hours to a day. Convulsions and muscular rigidity and opisthotonos are very rare conditions reported.

9. Gastro-intestinal symptoms. — Constipation is present from the onset, and persists throughout the disease. Vomiting may occur during the onset and again late, preceding a fatal termination. As a rule, the appetite and digestion are affected as in any febrile disease, and both may be good during the first week.

Sordes and coated tongue occur as in other febrile diseases.

10. The urine. — The urine is reduced in amount to about one half normal. It is high colored and may contain small amounts of albumin. Casts of various sorts are often present, granular, and occasionally blood casts are found.

In two cases in which I examined the urine no albumin was present. Maxey[8] states he never found albumin in his large experience.

In general, the urine shows the characteristics common to severe fevers without especial renal involvement.

11. The blood. — There are but few records of blood counts in the literature, and no complete record exists of any one

case. This is due naturally to the difficult conditions surrounding the cases in rural and often remote districts and to the fact that most cases arrive at hospitals late in the course of the disease.

A few facts, however, are established. There is only a slight leucocytosis — the white count in uncomplicated cases does not go above 12,000. The red cells decrease in number as the disease progresses and may fall below 3,500,000 before death.

There is a striking increase in large mononuclear leucocytes, apparently exclusive of large lymphocytes and so-called "transitional cells." I have found phagocytic cells in the circulation shortly before death. The eosinophiles are decreased and may be entirely absent in some preparations.

Most observers report the blood as being darker and less fluid than normal. Michie and Parsons[38] state that the coagulation time is increased.

The hemoglobin becomes slightly reduced.

As the number of blood observations is so small, I present the data as published.

Anderson[1] gives the average of the differential white cell counts in two cases; the age, sex and day of disease are not stated.

	Per Cent.
Polymorphonuclear leucocytes	77.7
Large mononuclear leucocytes	11.4
Small lymphocytes	10.0
Eosinophiles	0.9

He also gives the red and white cell counts and hemoglobin estimation of several cases included in the chart of Wilson and Chowning.

Michie and Parsons[38] report the presence of myelocytes and nucleated red cells and the presence of leucocytes in severe cases which they are unable to classify. They regard the "Arneth Index" as a reliable guide to the patient's condition, and present the following table of blood counts from two cases.

A sudden increase of leucocytes late in the disease is regarded by them as a serious sign.

CASE 1. Westerman. Fatal. Death on May 20, 1912.

Arneth count.

Date.	Group. I.	II.	III.	Index.	IV.	V.
May 15, 1912	7	47	33	70	12	1
May 16, 1912	7	53	33	76.5	6	1
May 17, 1912	5	58	35	80.5	2	0
May 18, 1912	9	61	22	81	8	0
May 19, 1912	6	57	34	80	2	1
May 20, 1912	5	60	31	80.5	2	2

Leucocyte count.

May 15, 1912	11,800	May 18, 1912	3,000
May 16, 1912	11,000	May 19, 1912	1,000
May 17, 1912	6,000	May 20, 1912	28,000

Differential count.

	Dates — May, 1912. 15.	16.	17.	18.	19.	20.
Large lymphocytes	6	3	4	0	2†	4
Small lymphocytes	2	3	1	0	0	2
Large mononuclears	19	11	27	11	15	25
Polymorphonuclear neutrophiles,	65	75	47	68	55	32
Transitionals	5	4	11	17	16	18
Eosinophiles	1	1	0	0	0	0
Mast cells	0	1	0	0	0	0
Unclassified	1	2	5	2	10	15
Myelocytes	2	0	5	2	2	4
Nucleated red cells	0	0	0	P*	P*	P*

* Present.

† Leucocytes were extremely scarce on May 19, 1912, and the above count is based on forty cells after one hour's search.

CASE 2. Male, aged 24 years. A typical fatal case, death on the ninth day.

Differential count.

	Eighth Day. Per Cent.	Ninth Day. Per Cent.
Large lymphocytes	8	2
Small lymphocytes	5	4
Large mononuclears	20	11
Polymorphonuclear neutrophiles.	34	45
Transitionals	26	19
Eosinophiles	2	0
Mast cells	2	2
Unclassified	3	8
Myelocytes	0	1
Nucleated red cells	Present.	Present.

Leucocyte count: May 7, 11,800; May 8, 7,120; May 9, 16,000.

Wilson's and Chowning's table showing red and white cell counts and hemoglobin estimates.

			Day of Disease.														
Case.	Age.	Sex.	2d.	4th.	5th.	6th.	7th.	8th.	9th.	10th.	11th.	12th.	13th.	14th.	15th.	16th.	17th.
89	34	F.								4,200,000 14,000 60%	Died.						
94	5	F.	4,500,000 12,000 50%							Died.							
107	4	M.				4,100,000 12,000 50%			Died.								
115	8	F.													Convalescent.	4,720,000 4,500 80%	4,824,000 4,450 90%
116	18	F.			4,920,000 7,400 90%		4,600,000 7,600 80%	Died.									
117	34	M.							4,368,000 7,800 60%	Died.							
118	40	M.					4,576,000 7,300 70%		3,820,000 8,000 50%			3,920,000 8,500 60%	Convalescent on twenty-first day.				
120	30	M.						4,744,000 4,800 90%	4,722,000 6,900 87%	4,700,000 85%	4,458,000 77%	3,672,000 75%	Died.				
122	30	F.						4,380,000 7,600 75%	4,723,000 10,040 70%	4,452,000 8,400 66%		60%	3,772,000 62%		4,200,000 62%	Convalescent.	
123	31	M.							3,408,000 75%	Died.							
124	33	M.		4,100,000 65%													

To these counts, I have the following of my own to add:

CASE 1. Woman, aged 26 years. Died on the ninth day of the disease.

	Sixth Day of Disease.	Seventh Day of Disease.
White count	7,300	7,300
Red count		5,008,000
Differential count.		
Polymorphonuclear leucocytes	81.2%	54.0%
Large lymphocytes	10.4%	26.5%
Small lymphocytes	3.9%	8.7%
Large mononuclear leucocytes	4.4%	8.0%
Eosinophiles	0.0%	2.2%

CASE 2. Man, aged 75 years. Fifth day of disease, second day of rash, one day before death.

Polymorphonuclear leucocytes	28.6%
Large lymphocytes	23.8%
Small lymphocytes	35.8%
Large mononuclear leucocytes	11.3%
Eosinophiles	0.0%
Blasts	1.0%

CASE 3. Man, aged 31 years. Died on the eighth day of the disease.

	Sixth Day.	Seventh Day.
Polymorphonuclear leucocytes	85.4%	87.0%
Large lymphocytes	6.2%	7.2%
Small lymphocytes	2.6%	3.5%
Large mononuclears	5.8%	2.6%
Eosinophiles	0.0%	0.0%
Blasts	Present.	Present.

CASE 4. Man, young adult. Died on ninth day of disease.

Blood counts on third day of disease.

Red cells	5,400,000
White cells	10,000
Polymorphonuclear leucocytes	87%
Hemoglobin	80%

The most striking feature of the blood picture is the increase in large mononuclear leucocytes. In Case 2, cells with inclusions of red cells and lymphocytes were found the day before death, and there is excellent evidence from the histological study of all my cases to show that one source of the large mononuclear leucocytes in the circulation in these cases is from the vascular endothelium. In all cases the polymorphonuclear leucocytes frequently contained small basic

staining bodies (Döhles' inclusions, Münch. Med. Wochenschr., July 23, 1912) common in scarlet fever and some other infections.

12. Complications. — Pneumonia is the one complication, and it is not frequent. Broncho-pneumonia, hypostatic pneumonia and lobar pneumonia have been reported in a few cases.

13. Types of the disease. — It is possibly justifiable to speak of a mild and a severe type of Rocky Mountain spotted fever, in view of the great difference between the mortalities of Idaho and Montana cases. However, as in other regions the mortality is intermediate between that of Idaho and Montana, this distinction should be used with caution, particularly as in some localities in Idaho the mortality is quite high. In all other respects the disease in Idaho and Montana is identical, although because of the lesser virulence in Idaho the late effects, such as necrosis of the skin, are more often seen.

No solution of the cause of the consistent difference in mortality of cases from these two regions has been found. Theoretical considerations point to a solution in the different types of mammalian hosts other than man, and opportunities for rapid mammalian passage of the virus.

14. Treatment. — There is no specific treatment. The fever should be treated by the general measures employed in other continued fevers. Cold bathing should be employed to reduce temperature and to allay nervous symptoms, with observation of the same precautions used in typhoid and typhus fevers. Antipyretic drugs should be avoided.

The diet should be nutritious, easily digestible and liberal, particularly in the first stages of the disease, in order to keep up the strength of the patient. As the kidneys and alimentary tract escape lesions, there is no reason against a liberal diet until the time when nausea occurs as a result of the general intoxication. It would even seem advisable to force the diet in the early days of the disease. A liberal liquid intake is

indicated also, in order to increase the output of urine. The bowels should receive attention from the start of the disease, and a daily movement secured by aperients or enemata.

The modern use of digitalis in pneumonia might well be followed in anticipation of circulatory changes late in the disease. A few doses of digitalis at the onset of the disease in order to "digitalize" the heart is therefore recommended, to be followed by further administration of the drug when the pulse rate becomes over rapid.

Since the restlessness, hyperesthesia and insomnia undoubtedly are of great importance in the production of exhaustion, hypnotics should be given in amount sufficient to insure adequate rest for the patient. Morphine and hyoscine may be recommended, and I can think of no deleterious action of these drugs that overweighs the importance of their action. In general, the therapeutic measures employed should be directed towards conserving the strength of the patient and allaying discomfort, thus insuring the most favorable circumstances for the natural forces of the body against the infection.

The various drugs which have been employed without beneficial action are quinine, the coal-tar products, calcium sulphide, creosote, various forms of arsenic including atoxyl, salvarsan and sodium cacodylate and sodium citrate injections. Salvarsan and atoxyl are decidedly deleterious in their effect.

The efforts of Ricketts and his associates, Heinemann and Moore,[25] to produce an immune serum in horses have given indication of possible success, but the work was not continued long enough to demonstrate the value of such a serum. The intravenous administration of human serum or blood from an individual who has recovered from the disease one or two years previously is theoretically worth trying in districts where the mortality is high. To be effective the serum or blood should be given early in the disease and in as large amounts as possible. In two cases, Cases 1 and 3 of my series, blood transfusions were tried, but in both instances late in the disease, and without beneficial results.

V. PREVIOUS WORK ON THE PATHOLOGY.

The number of post-mortem examinations recorded is small and not as large as a casual inspection of the literature would suggest, because several authors have each reported the same cases.

Wilson and Chowning[68] report a summary based upon eight autopsies, and Anderson[1] one based upon seven cases. Anderson's cases are included among Wilson's and Chowning's cases, and presumably most of them represent the work of the latter authors. There were six autopsies by Ricketts[56] (Carpenter Lecture) summarized by Le Count,[30] and one by Michie and Parsons. Stiles[63] and Ashburn[2] each report post-mortem results from cases in the series of Wilson and Chowning or Anderson. As far as can be determined, fifteen autopsies have been made, all upon Bitter Root Valley cases.

1. Gross pathology. — Wilson and Chowning, and Anderson, noted the early onset of intense rigor mortis. The only constant distinctive gross lesions are those of the skin and enlargement of the spleen. The musculature of the body, peritoneal, pleural and pericardial cavities are normal. The heart may show minute hemorrhages into the epicardium, and as a rule the right side of the heart is distended with blood — the left side contracted. The lungs, beyond hypostasis and, occasionally, terminal pneumonia, are normal.

The spleen is reported as markedly enlarged in all cases, and may weigh from two to four times the normal. Wilson and Chowning, and Anderson, report the spleen as soft, while Michie and Parsons, and Ricketts, emphasize its firmness. The latter specifically states that it has " none of the soft, semi-gelatinous appearance of the typhoid spleen "; which is in accordance with my own observations.

The liver has consistently been recorded as large, pale, injected, and often as fatty. Wilson and Chowning, and Anderson, note stasis of bile in the ducts.

The gastrointestinal tract has shown no lesions. The pancreas, according to Anderson, is enlarged. The kidneys also are said to be enlarged, injected and degenerated or

fatty. Ricketts did not note the subcapsular hemorrhages noted by the other authors. The bladder and uterus show no lesions. No lesions have been noted in the aorta, vena cava and large arteries and veins of the trunk and extremities. The lymph nodes, according to Ricketts, are uniformly enlarged. Anderson states they are not enlarged. In two of Ricketts' cases the bone marrow was red. The central nervous system has shown no lesions beyond injection of the meningeal vessels. The lesions of the skin found after death consist of hemorrhages into the subcutaneous tissues, and gangrene, the latter usually of the scrotum and prepuce, rarely of the faucial pillars and soft palate. The gross pathology is therefore not distinctive except for the skin lesions. Otherwise the findings have been essentially those of any infectious disease.

2. Microscopic pathology. — Wilson and Chowning,[68] and Le Count[30] only have given accounts of the pathologic histology. The former present a very superficial account and record no distinctive lesion of the disease. They do note capillary hemorrhages in the skin and the accumulation of leucocytes in the capillaries of the skin and liver. They also noted phagocytic cells containing red blood cells in the capillaries of the skin, lungs, spleen, liver and kidney — a fair portion of their description is concerned with the presence of "infected red cells." Their summary is — "The changes are those which can be ascribed to interference with capillary circulation. The extravasation into and pigmentation of the skin account for the persistence of the 'spots' for long periods after the recovery of the patients. There is acute parenchymatous degeneration of the heart muscle, spleen, liver and kidney. The central nerve system is but little affected."

Le Count summarized the study of tissues from six monkeys, thirty-two guinea-pigs and six human cases. His descriptions are very brief and give the impression of his having seen more than he recorded. He noted as the most distinctive lesion, occlusion of blood vessels and the resultant necroses. "In sections of the skin, liver, kidney, spleen and adrenal

both vascular occlusion and the necroses resulting from obstruction were present. In the lung and heart the capillaries and small veins were found practically occluded with leucocytes, but there were no serious consequences of these conditions with exception of minute hemorrhages beneath the endocardium." Le Count attributed the necroses of the ears and scrotum of guinea-pigs to "anæmia from plugging of small blood vessels," but he does not describe the histology and development of the lesion which leads to thrombosis. Focal lesions in liver and spleen are described as attended with accumulation of mononuclear leucocytes, and he vaguely suggests that these cells may be endothelial in origin. "In discussing this phase of the subject it is proper to liken the focal necroses and the preliminary vessel changes to the alterations caused by the so-called 'endothelial toxins'; furthermore, to recall that some such toxins, it is believed, are liberated from the bodies of bacteria."

Le Count also noted in the spleen of guinea-pigs and man, but not in monkeys, the presence of large multinucleated cells resembling the megakaryocytes of bone marrow. In enlarged lymph nodes he found the sinuses crowded with mononuclear phagocytes. No lesions were found in the bone marrow of animals or in the central nervous system of man and animals.

Perivascular accumulations of cells and "evidence of their multiplication in situ" in the testes of guinea-pigs and monkeys was interpreted by Le Count as the probable "formation of new depots for the production of leucocytes or other cells which presumably are in some way designed to play some part in the defensive processes. These are usually in perivascular situations and so limited to the regions of the lymph channels that it seems unreasonable to ascribe them to the focal processes of blood-vessel obstruction and their sequences."

Le Count's contribution to the pathology of the disease was the recognition of the vascular lesions, but he apparently regarded them as secondary to focal lesions beginning in the tissues.

Ricketts' conception of Rocky Mountain spotted fever was obtained wholly from gross observations. He considered it to be a hemorrhagic septicæmia. Later, in his work on typhus fever, he took the same attitude and he classed both diseases with plague.

3. Attempts to demonstrate a parasite. — The work of Wilson and Chowning and the supposed discovery of a *piroplasma* has been referred to in the historical review.

Fricks[22] in 1916 reported the finding of protozoan-like bodies in the blood of spotted-fever guinea-pigs. These bodies were intracellular (in red corpuscles) and free, but were found only after the blood had gone through several long procedures, including defibrination, centrifugalizing for fifteen minutes, diluting with salt solution and a second centrifugalizing for six hours. The bodies were found in smears from the sediment stained with Giemsa's stain, and are described as "bright red granular bodies, singly and in pairs, highly refractile, accompanied by larger light blue bodies, and all surrounded by a pale blue matrix, the whole mass being rather indistinct but not encountered in the controls." These bodies were very small in size, the red staining ones being less than one micron in diameter, the blue staining ones slightly larger. Fricks could not find similar bodies in controls from normal guinea-pigs and from guinea-pigs with other diseases.

It is of interest to note that Fricks, who has made extensive studies of spotted fever, did not find the lanceolate organisms described by Ricketts and myself.

Ricketts'[55,56] attempts to demonstrate a parasitic microorganism in Rocky Mountain spotted fever resulted in the finding of a minute lanceolate bipolar organism in the blood of man, guinea-pigs and monkeys. Similar organisms were found by him in the tissues of infected ticks and in the eggs of infected ticks. These small rods were agglutinated by the blood from immune guinea-pigs. Ricketts found similar bacillary forms in the tissues and eggs of non-infective ticks. In the light of my own work it seems certain that Ricketts saw in the blood of infected animals and man the true parasite

of Rocky Mountain spotted fever. It also seems certain that in the tick he was misled by bacteria which are occasionally found in large numbers and of a size small enough to make confusion possible. Ricketts stated that the bacilli which he regarded as the cause of the disease were found in enormous numbers in the tissues and eggs of infected and non-infected ticks, in smear preparations, which I have found a most unsatisfactory method for demonstrating the true parasite of Rocky Mountain spotted fever. I have never been able to find the parasite in any number in eggs from proved infected adult ticks, and when present they invariably were markedly different in their morphology from those described by Ricketts. I have had the opportunity of comparing one of Ricketts' original preparations with those I have made from the eggs of infected ticks, and from the eggs of non-infected wild ticks, and feel convinced that, while Ricketts may have encountered the true parasite of the disease in ticks, he was led hopelessly astray by the occurrence of bacteria in his infected as well as non-infected ticks.

VI. IMMUNITY.

No instance is known of a second attack of Rocky Mountain spotted fever in man.

Our knowledge of experimental immunity in animals is derived wholly from the work of Ricketts and his associates[14, 15, 54, 56] upon guinea-pigs. Recovery from the disease confers a complete and lasting immunity in animals. Passive immunity may be conferred by the injection of blood from an immune animal simultaneously or soon after the injection of the virus, but this immunity is not lasting. These facts have been repeatedly confirmed by my own experiments upon guinea-pigs, using immune guinea-pig serum. Attempts to produce passive immunity in guinea-pigs, using serum from immune rabbits, have been only partly successful as the experiments were much interfered with by the presence of an epizoötic in guinea-pigs at the time; but there are no theoretical reasons why immunity should not be conferred by serum from immune animals of another species.

Ricketts found that the offspring of immune female guinea-pigs were immune and that this immunity was independent of the ingestion of milk from the immune mother, and also that guinea-pigs from non-immune parents suckled by an immune female were not immune. Experiments done by Foot[17] in my laboratory on the offspring of the immune rabbits failed to demonstrate the presence of immunity.

In two human cases studied by me, Cases 1 and 3 of this report, two were given transfusions of blood from an immune donor who had recovered from the disease the previous year. No beneficial effects were observed, but the tests are of small value as the transfusions were done late in the course of the disease.

VII. THE ROCKY MOUNTAIN SPOTTED FEVER TICK.

1. Nomenclature. — It is now recognized that but one species of *Dermacentor* is concerned in the natural transmission of Rocky Mountain spotted fever. When Ricketts began his work, there had been but little systematic study of ticks from the northwest region, and the ticks he used from the Bitter Root Valley were identified by Stiles as *Dermacentor occidentalis*, a closely similar species. Later, Stiles[65] recognized the Bitter Root tick as a new species which he named *Dermacentor andersoni*. Meanwhile Banks[4] had described this tick as *Dermacentor venustus*, and gave Marx the credit for this name, and for separating it from *D. occidentalis*. For a time the ticks concerned in the transmission of the disease in Idaho were erroneously regarded by Banks as a distinct species, *Dermacentor modestus*, and Ricketts[56] used this name in speaking of the ticks from Idaho.

These various names have all been used loosely by authors in writing about Rocky Mountain spotted fever, and naturally confusion has existed as to the correct nomenclature, even among entomologists, and whether or not more than one tick is concerned in the transmission of the disease.

Stiles protested against the use of the name *Dermacentor venustus* for the spotted fever tick, believing that Doctor Marx intended it for a species of *Dermacentor* from Texas. Be

this as it may, there is no question at all in regard to the identity of the ticks used by Banks and by Stiles in their studies and *Dermacentor venustus*, Banks, and *Dermacentor andersoni*, Stiles, are identical.

When systematists arraign one another in controversy in spite of the International Code, a novice had best refrain from comments, but a brief statement of the situation seems advisable in the face of the confusion in regard to the proper name or names of the tick concerned and whether or not more than one tick may be the subject of this confusion.

Banks[5] in 1910 protested against the name *Dermacentor andersoni*, rightly claiming that he was the first to separate the tick in question from *D. occidentalis*, giving it the name *D. venustus*, a manuscript name from Marx. Stiles[64] in answer claimed that *D. venustus* was applied by Marx to a different species and that the name was originally published by Neumann in 1897 as a synonym of *D. reticulatus*, and its typical locality was given as Texas and New Mexico. This view of Stiles was also that of Salmon and Stiles[59] in regard to *D. venustus* in 1900 before the identification of the spotted fever tick as a new species was made.

Banks[4] in 1908, in his description of *Dermacentor venustus*, says: "This species is quite common in the Northwest. It has been included in *D. occidentalis* by Neumann, but was separated out by Doctor Marx in manuscript under the name I have adopted. This is the species supposed to be concerned in the transmission of spotted fever in Montana." Banks gave the sources of his specimens of *D. venustus* as Washington, Colorado, New Mexico, Montana, Utah, Idaho and Texas (on sheep).

We may therefore assume that Banks believed that the tick described in manuscript as *D. venustus* by Marx was neither *D. reticulatus* nor *D. occidentalis*, but was identical with specimens later obtained by him (Banks) from the Northwest and identical with the tick subsequently described by Stiles as *D. andersoni*.

Usage is settling the difficulty in favor of *D. venustus*. Patton and Cragg[43] in their textbook of Medical Entomology

use the name *D. andersoni*. R. O. Newmann and Mayer,[40] in Lehmann's "Atlas und Lehrbuch wichtiger tierischer Parasiten und ihrer Ueberträger," accept *D. venustus*. Theobald, in "The Animal Parasites of Man," by Fantham, Stephens and Theobald,[16] also uses *D. venustus* to designate the spotted fever tick. Nuttall[42] uses *D. venustus* in describing the habits of this tick, but in a footnote states that the name is "still *sub judice*."

The name *D. venustus* is used in the publications of the Federal Bureaus of Entomology and Biological Survey and by the Montana State Board of Entomology.

There is now no excuse for confusion in regard to the tick itself. *Dermacentor occidentalis* is another species with a more western habitat which does not overlap that of *D. venustus* (Birdseye,[6] Hunter and Bishopp[26]) and is easily distinguishable from *D. venustus*. *Dermacentor modestus*, other than in the publications of Ricketts, has not figured in literature and is not to be found in any entomological publication I have consulted, and may be regarded as a name applied to specimens of *D. venustus* from Idaho, for a time, under the impression that they represented a new species.

In this paper *Dermacentor venustus* will be used as the name of the spotted fever tick; synonym, — *Dermacentor andersoni*.

2. The classification and external anatomy of ticks. Figs. 8 to 17. — A brief consideration of the classification of ticks, super family *Ixodoidea*, order *Acarina*, class *Arachnida*, in general is essential in this report because of the desirability of clearing away the confusion which exists in foreign medical works on entomology in regard to the conveyor of spotted fever. A brief description of the anatomy of ticks is accordingly given for the purpose of making intelligible the principles of classification.

The ticks are visible to the naked eye in all stages and several different stages are recognized in each species; the eggs which are ovoid with a tough, almost transparent, pliable shell; the larvæ which are six-legged and without genitalia;

the nymphs which are eight-legged and also asexual, and the adults, which also have eight legs and which are sexually mature as male or female.

Ticks have a body and a capitulum or rostrum, popularly spoken of as a head. The true head of a tick has become fused with the body and cannot be recognized. There is no cephalothorax. The capitulum consists of a base, the basis capituli, which bears the palps, the manibles or chelicerae, the mandibular sheaths and the hypostome, radula or labio-maxillary dart. The mandibles with their sheaths and the hypostome form the proboscis or haustellum.

The basis capituli is the basal portion which articulates with the body in the recess or emargination called the camerostome. Its shape varies in different species, and hence it is of value in classification. In females the basis capituli contains on each side of a median ridge a depressed area which consists of many minute pores and which are known as the porose areas. As the shape and precise position of these areas vary in different species, they are also of value in classification.

The hypostome is situated in the median line and consists of two fused symmetrical halves forming an elongated, spatulate, chitinous structure armed with small teeth which are directed backwards and arranged in transverse rows. The arrangement, size and distribution of the teeth vary in different species.

The paired mandibles and their sheaths form the dorsal wall of the organ of penetration of which the hypostome forms the ventral wall. The mandibles consist of cylindrical pieces or shafts of chitin, the proximal ends of which are bulbous and project into the body cavity to receive the attachments of the extensor and retractor muscles. On the distal ends of each mandible is articulated a digit which bears two or three toothed apophyses. Although the digits vary in architecture in different species, they are not of especial value in classification.

The mandibular sheaths are dorsal to the mandibles and continuous with the anterior portion of the basis capituli.

The two sheaths lie in close apposition; their distal ends form thin membranes which are invaginated and attached to the shafts of the mandibles. The outer surfaces of the sheaths are covered with teeth of microscopic size arranged in rows.

The palpi are inserted deeply, one on each side, into the basis capituli on the antero-lateral margins, in some species more on the dorsal side, in others more on the ventral side. They are flap-like structures composed of four segments, and vary considerably in size and shape in the different species of ticks. The basal segment is short and broad and usually hidden by the basis capituli, while the distal segment is very small so that commonly only two segments are easily seen. The palps as a whole are concave on the median side and serve to sheath the mouth parts. The comparative dimensions of the second and third segments of the palpi are of value in classification.

The body is oval or elliptical, flat in shape dorso-ventrally, and the dorsal surface is slightly convex. The anterior end of the body is emarginated to form the camerostome into which the capitulum is articulated. The integument as a whole is pliable, tough and leathery.

In Ixodidæ the dorsal surface is covered with a hard, chitinous plate of varying shape, usually irregularly hexagonal, called the scutum. In the male the scutum covers almost the whole dorsal surface; in the female it covers only about the anterior half though after engorgement it becomes very much smaller in proportion to the size of the tick. The scutum is usually marked by two longitudinal cervical grooves. The eyes, when present, are situated on the lateral margins of the scutum. The festoons are small lobe-like portions of the posterior margin of the body, usually eleven in number, which are bounded by short furrows running inwards from the body margin.

On the ventral surface of the body there are two orifices in the median line, a genital aperture or pore, situated anteriorly close to the base of the capitulum and the anus situated posterior to the last pair of legs. The anus is surrounded by a groove which is of great importance in classifying the

several genera as it varies in position and shape. The males of some species have one or two chitinous plates on each side of the anus, also of importance in classification.

The legs arise from the anterior part on each side of the ventral surface and each leg consists of six parts or segments. The coxa is the basal or first segment; it lies flat against the body and is not movable; it may have one or two spurs, i.e., dentate or bidentate. The next segment is the trochanter, which is short and may be broader than long. The third segment is the femur, which is elongated and joined to the trochanter by a pseudo-articulation. The fourth segment, the tibia, and the fifth, protarsus or metatarsus, are also elongated. The sixth segment, or tarsus, may also at its proximal end form a pseudo-articulation; its extremity is provided with two claws supported by a long or short stalk. In the Ixodidæ the claws carry on their ventral surface a membranous disc-like or umbrella-like expansion, the pulvillum. Haller's organ is situated on the dorsal surface of the first (anterior) coxa; it consists of several cup-shaped pores containing sensory hairs and dermal cells. It is supposed to be an organ of hearing (Banks) or smell (Patton and Cragg).

The stigmal plates containing the spiracles or stigmal orifices into which the tracheæ open, consist of raised chitinous plates traversed by goblet-like structures which give the surface a reticulated appearance. The stigmal plates may be round, oval, triangular or comma-shaped, and the shape and markings are quite constant for each species, though they differ in the sexes. The stigmal plates are situated above and usually behind the last (fourth) coxa.

The ticks *Ixodoidea* are divided into two families, the *Argasidæ* and the *Ixodidæ*, the most striking difference between the two families being the possession of a shield or scutum by the latter. Other differences as tabulated by Nuttall, Warburton, Cooper and Robinson[41] are:

	ARGASIDÆ.	IXODIDÆ.
Sexual dimorphism	Slight.	Marked.
Capitulum: Base	Ventral camerostome, no porose areas in ♀.	Anterior camerostome, porose areas in ♀.
Palps	Leg-like with sub-equal articles.	Relatively rigid, of very varied form, with rudimentary fourth article.
Body: Scutum . . .	Absent.	Present.
Festoons . . .	Absent.	Generally present.
Eyes: (When present)	Lateral on supracoxal folds.	Dorsal on sides of scutum.
Spiracles.	Very small, more anterior.	Generally large, well behind Coxa IV.
Legs: Coxa	Unarmed.	Generally armed with spurs.
Tarsi	Without ventral spurs.	Generally armed with one or two ventral spurs.
Pad (pulvillus) .	Absent or rudimentary.	Always present.

There are two genera of *Argasidæ*, Argas and Ornithodorus.

There are several classifications of the *Ixodidæ*. The following by Nuttall, Warburton[41] *et al.* will serve the purposes of this paper; it carries the weight of great authority and has been logically developed along established lines. The reader is referred to the work of Patton and Cragg[43] for a comparison of several classifications.

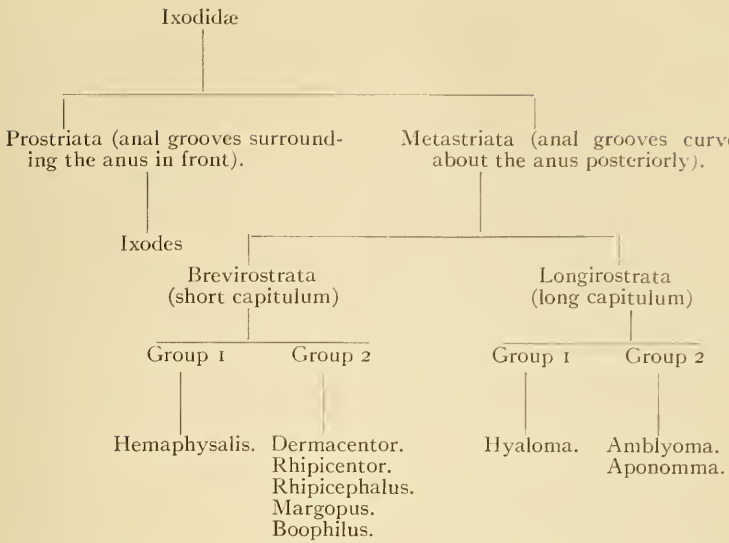

The genus *Dermacentor* is defined as: "usually ornate with eyes and festoons; with short, broad or moderate palps and basis capituli rectangular dorsally. In some species Coxæ I. to IV. of the male increase progressively in size; in all species Coxa IV. is much the largest; the male, moreover, shows no ventral plate or shields, Coxa I. bifid in both sexes. Spiracles sub-oval or comma-shaped."

The original description of *Dermacentor venustus* by Banks [4] is as follows:

"*Male.* Red-brown, marked with white, but not so extensively as *D. occidentalis*, usually but little white on the middle posterior region; legs paler red-brown, tips of joints whitish. Capitulum quite broad, its posterior angles only slightly produced; palpi very short and broad, with many, not very large punctures; lateral furrows distinct. Legs of moderate size, hind pair plainly larger and heavier, and with the teeth distinct. Coxæ armed as usual, the Coxa IV. nearly twice as wide at base as long. Stigmal plate with a rather narrow dorsal prolongation, with large granules in the main part and minute ones on the prolongation. Length of male 3.5 to 5 mm."

"*Female.* Capitulum and legs reddish-brown, the latter with tips of joints whitish; shield mostly covered with white. This white not so much broken up by the brown dots as in *D. occidentalis;* abdomen red-brown. Capitulum rather broad, posterior angles but little produced, the porose areas rather large, egg shaped, and quite close together; palpi shorter than width of capitulum. Shield as broad as long, broadest slightly

before its middle, and rather pointed behind, with numerous, not very large punctures. Legs of moderate size, the coxæ armed as usual. The stigmal plate has a rather narrow dorsal prolongation, with large granules on the main part, and small ones on the prolongation. Length of female shield 2 mm."

Banks makes the following comment: "This species is quite common in the Northwest. It has been included in *D. occidentalis* by Neumann, but was separated out by Dr. Marx in manuscript under the name I have adopted. It is larger than *D. occidentalis*, with more red and less white in the coloring, and differs in many minor points of structure. such as size of porose areas, size of hind coxæ in male, etc. This is the species supposed to be concerned in the transmission of spotted fever in Montana."

3. Hosts of *Dermacentor venustus*. — Besides the domestic animals which graze, such as horses, cows, mules, asses, sheep and goats, practically all of the wild mammals of the tick-infested regions serve as hosts. Facts which are of interest and of probable importance in the distribution of the virus in nature are that the larvæ and nymphs of the tick feed exclusively upon small animals and that the adults feed chiefly upon larger animals and in settled regions largely upon horses, cattle and sheep. According to Parker,[45] the domestic pig occasionally serves as host.

Hunter and Bishopp[27] found larvæ or nymphs or both upon the following animals:

Common names.	*Scientific names.*
Columbian ground squirrel	*Citellus columbianus*
Yellow-bellied chipmunk	*Eutamias b. luteiventris*
Pine squirrel	*Sciurus h. richardsoni*
Woodchuck	*Marmota flaviventer*
Side-striped ground squirrel	*Callospermophilus l. cinerascens*
Wood rat	*Neotoma cinerea*
Snowshoe rabbit	*Lepus bairdi*
Cottontail rabbit	*Sylvilagus nuttalli*
White-footed mouse	*Peromyscus m. artemisiæ*
White-bellied chipmunk	*Eutamias q. umbrinus*
Large meadow mouse	*Microtus modestus*
Jumping mouse	*Zapus princeps*
Pika or rock rabbit	*Ochotona princeps*
Pocket gopher	*Thomomys fuscus*

The woodchuck, jack rabbit and snowshoe rabbit also harbored adult ticks, while adults only were found on the following:

Common names.	*Scientific names.*
Mountain goat	*Oreamnos montanus*
Brown bear	*Ursus americanus*
Coyote	*Canis lestes*
Badger	*Taxidea taxus*
Wild cat	*Lynx uinta*

Dermacentor venustus was not found on the white-tailed deer (*Odocoileus leucurus*), two specimens; the mule deer (*Odocoileus hemionus*), six specimens, and the elk (*Cervus canadensis*), one specimen.

Parker and Wells[44] in eastern Montana found larvæ or nymphs or both on the following animals:

Common names.	*Scientific names.*
Prairie dog	*Cynomys ludovicianus*
Jack rabbit	*Lepus townsendi campanius*
Cottontail rabbit	*Sylvilagus nuttalli grangeri*
Striped spermophile	*Citellus tridecemlineatus pallidus*
Kangaroo rat	*Perodipus montanus richardsoni*
Pack rat	*Neotoma cinerea*
Upland meadow mouse	*Microtus ochrogaster haydeni*
Grasshopper mouse	*Onychomys leucogaster missouriensis*
Deer mouse	*Peromyscus mamiculatus osgoodi*
Pale chipmunk	*Eutamias pallidus*
Porcupine	*Erethizon epixanthus*

Adult ticks were also found on the prairie dog, jack rabbit and porcupine.

In western Montana the mountain goat seems to be the most important wild host of the adult *D. venustus*, as over a hundred in various stages up to complete engorgement were found on each of three goats examined. The most important host of the larvæ and nymphs is the ground squirrel, as sixty-five per cent of three hundred and forty-one examined were tick infested. Next in order of importance as hosts for larvæ and nymphs are the yellow-bellied chipmunk and the pine squirrel. Other mammals of considerable importance are the woodchuck, snowshoe rabbit, wood rat, white-footed mouse, meadow mouse and side-striped ground squirrel.

In eastern Montana the jack rabbit is the most important wild host of the adult spotted fever tick, as Parker[45] found eighty-seven per cent of them infected (eighty-four specimens examined). The jack rabbit also harbors the nymph and the larva; it is the most important host of nymphs in eastern Montana, and is the only animal that acts as host to all three stages of this tick. The deer mouse, as a host, is next in importance in eastern Montana, because of its abundance and because it harbors both larvæ and nymphs.

4. Biology of *Dermacentor venustus*. The following account is taken chiefly from the papers by Hunter and Bishopp[26, 27] and Bishopp and King.[7]

This tick, in common with most other ticks, passes through four distinct stages, the egg, the larva, the nymph and the adult. Fully engorged females deposit from two thousand to four thousand eggs. These hatch into six-legged larvæ.

The larvæ feed on small mammals and require three to eight days for complete engorgement. When engorged they drop from the host and seek protected places, and in a few days become quiescent. After a quiescent period of six to twenty-one days (Hunter and Bishopp) or eleven to thirty-one days after dropping (Bishopp and King) the eight-legged asexual nymphs emerge.

The nymphs in natural conditions may pass the winter either in the unengorged or engorged state. Engorgement is necessary as in the case of the larvæ, for further development, and again the hosts are small mammals, the same that the larvæ feed upon. The nymphs require three to nine days for feeding, and leave the host after engorgement and according to the temperature, molt to sexually mature adults in from twelve to one hundred and forty days. Nymphs will pass the winter in the engorged state and in experiments made by King in 1910–11 nymphs engorged between August 22 and September 11 emerged as adults between July 26 and August 18, 1911, giving a maximum period for molting of eleven months and nineteen days. In other experiments by King in the Bitter Root Valley in 1911, nymphs which

engorged in April molted in eighty-three to one hundred and forty days, those engorged in May molted in seventy-three to ninety-nine days, those engorged in June molted in thirty-nine to sixty-four days, those engorged in July molted in twenty-nine to sixty-one days, and those engorged in August molted in twenty-seven to thirty-one days.

The adult ticks feed in the spring months before hot weather begins and almost wholly on large animals such as horses and cattle. The males after feeding about four days seek the females which are fertilized while feeding. It requires eight to fourteen days for the female to engorge, after which she drops from the host and finds a protected spot in which to deposit her eggs. The period before the deposition of eggs begins after engorgement, varies with the temperature; at Dallas, Texas, Hunter and Bishopp, with eight females, record periods of from six to ten days. In the Bitter Root Valley, with three females, they record periods of thirteen to forty-one days in 1910, while Bishopp and King in the Bitter Root Valley during a colder spring, 1911, with seven females record periods between twenty and fifty-nine days. The female dies within a few days after depositing the last eggs, which are all in one place as she is inactive during the process.

Temperature conditions also affect the incubation period of the eggs, sixteen to thirty-five days with eight batches of eggs at Dallas, Texas, are periods given by Hunter and Bishopp, while in 1910 in the Bitter Root Valley with four batches of eggs, the periods were thirty-four to fifty-one days. In 1911 Bishopp and King with seven batches of eggs obtained incubation periods of thirty-one to seventy-three days.

The entire life cycle of the tick under natural conditions requires two years, but may take three years, as unfed nymphs and adults may survive for long periods. King (personal communication) has demonstrated that adult ticks may not find opportunity for feeding until the fourth spring from the egg stage. Larvæ, nymphs and adult ticks all may hibernate

in the unfed condition. Larvæ may live more than three hundred and seventeen days, nymphs more than a year, and adults more than six hundred and thirty-two days in the unfed condition. Adult ticks which do not engorge before hot weather sets in leave the plants upon which they rest while awaiting hosts and crawl down beneath grass and leaves to await another season, remaining practically inactive until hibernation, so that after July first very few adult ticks are seen in the Bitter Root Valley.

The greatest abundance of adult ticks is during April and May, and they disappear rapidly from sight during June, so that by July first few are found attached to hosts. Their first appearance after hibernation depends upon the temperature; Bishopp and King estimate that a daily mean temperature of 38° F. to 42° F. for six to twelve days will cause the ticks to emerge from hibernation, so that the second week of March begins the activities of the ticks in all of the states where spotted fever exists.

Dormancy in the fall is induced by temperatures considerably higher, 10° F. to 15° F. (Bishopp and King) than that required to awaken the ticks from hibernation, which means late August to early September in the spotted fever states. The nymphs and larvæ probably enter hibernation at the same time, as their principal hosts, the ground squirrel and woodchuck, go into hibernation about the middle of August.

The life cycle, as has been stated above, requires naturally at least two years. Bishopp and King have shown that nymphs which develop from over-wintered adults do not engorge that year, and also that adults which develop from over-wintered nymphs do not engorge the same year. Therefore eggs are deposited only by ticks which have passed the winter in the adult stage, and the eggs do not develop beyond the nymphal stage.

The ordinary life cycle is probably as follows: — Larvæ and nymphs which pass the winter engorged or unengorged, reach the adult stage the following summer. Adults which pass the winter deposit eggs the following spring, and their

eggs may develop as far as the nymphal stage. As adults very frequently do not find hosts the first season, a three-year cycle cannot be uncommon.

In the laboratory, ticks may be reared from eggs the same season they are deposited. The history of the eggs from two females received engorged from R. R. Parker, in June, 1918, is as follows:

Female A. Deposited eggs between June 21 and June 30. Eggs hatched at room temperature July 20 to July 29. The larvæ were placed on a guinea-pig on August 1 and dropped fully engorged between August 5 and August 8. The larvæ molted to nymphs between August 18 and August 23, and were fed on a guinea-pig between September 18 and 27. The engorged nymphs were placed in a bacteriological incubator at 37.5° C. September 27. The majority of them molted to adults between October 19 and December 4.

Female B. Received engorged from R. R. Parker in June, 1918, and deposited eggs between June 21 and June 30. The larvæ emerged at room temperature between July 20 and July 29, and were placed upon a guinea-pig on August 5. The fully engorged larvæ dropped between August 8 and August 12, and were kept at room temperature. The nymphs emerged between August 21 and August 28. They were fed between September 18 and September 26. Four fully engorged nymphs only were recovered, and these were placed in the bacteriological incubator at 37.5° C. The first molted on October 22; two more between this date and December 3; one perished.

5. Susceptibility of wild mammals to Rocky Mountain spotted fever. — Ricketts[52, 56] proved the susceptibility of the ground squirrel (*Citellus columbianus*), the woodchuck (*Marmota flaviventer*), the rock squirrel (*Callospermophilus lateralis cinerascens*), the chipmunk (*Eutamias sp.?*), and the mountain rat (*Neotoma sp.?*).

McClintic[36] showed that the ground squirrel (C. *columbianus*), the badger (*Taxidea taxus*), the weasel (*Putorius arizonensis*), the woodchuck (*Marmota flaviventer*), and the

rock squirrel (*Callospermophilus lateralis cinerascens*) could be infected. All showed only slight evidence of the disease, and guinea-pig inoculation was necessary in each instance to prove the presence of the virus in the blood of the animals tested. McClintic also proved that immune ground squirrels and woodchucks existed in the Bitter Root Valley. Of one hundred and sixty ground squirrels, forty were incapable of maintaining the virus when inoculated from infected guinea-pigs. Of fifteen woodchucks, three were found to be incapable of maintaining the virus. The demonstration of immune ground squirrels and woodchucks is strong evidence that these animals are infected in nature by the bites of ticks.

6. Infected ticks in nature. — Ricketts[52] was the first to produce spotted fever in a guinea-pig by allowing wild ticks, *D. venustus*, to feed upon it. In one experiment in which thirty-six male ticks from the Bitter Root Valley were fed upon one guinea-pig, a typical case of spotted fever resulted. Later Maver[31] produced the disease in two out of fourteen guinea-pigs, upon each of which twenty-five male and twenty-five female ticks were allowed to feed. Nine of these guinea-pigs had Montana ticks from the region of the Bitter Root Valley and five Idaho ticks from the vicinity of Pocatello placed upon them. At the time of the experiment the Idaho ticks were erroneously regarded as distinct from *D. venustus* and were called *D. modestus*. Two of the guinea-pigs upon which ticks from the Lo Lo Valley (a tributary of the Bitter Root Valley) were fed, developed spotted fever. The ticks used were collected from cows. The guinea-pigs upon which the Idaho ticks were fed did not develop spotted fever.

McClintic made more extensive researches in this direction, the results of which were published after his death by Fricks.[20] About two thousand ticks, *D. venustus*, collected in the foothills of the Bitter Root Mountains west of Victor, were used and were fed in lots of varying numbers upon fifty-four guinea-pigs. Six lots of these ticks were collected from mountain goats. In all, six guinea-pigs developed spotted fever, but three of these were infected from lots of ticks

which came from one mountain goat. It is of great interest to know that a guinea-pig inoculated with one cubic centimeter of blood from this goat did not develop the disease and proved susceptible to a subsequent inoculation of the virus from another guinea-pig. The other three guinea-pigs were infected by wild ticks collected from vegetation. Two guinea-pigs upon which ticks fed that came from two other goats, while they did not show symptoms of the disease, proved to be immune to subsequent inoculation, which is presumptive evidence that they had harbored infective ticks, thus bringing the total of positive results in McClintic's experiments to eight from ticks from six different sources.

In all of the above experiments by Ricketts, Maver and McClintic, substantially the same technic was employed. Guinea-pigs which developed no evidence of the disease were tested for immunity before they were recorded as negative. Guinea-pigs which developed the disease were used to inoculate other guinea-pigs in order to prove the infection to be that of spotted fever.

R. A. Cooley[9] also records the infection of a guinea-pig with ticks which were collected by W. V. King in the Bitter Root Valley. In this experiment one of four guinea-pigs upon which one hundred and sixty ticks fed became infected.

VIII. HISTORY AND IDENTITY OF THE STRAINS OF VIRUS USED.

1. Record. — Strain I. was started in January, 1916, from ticks sent by Surgeon L. D. Fricks. Two guinea-pigs were infected by a male and female tick respectively, and the strain obtained from the female tick was maintained until August 23, 1918. The various transfers are shown on Chart No. 1. These ticks were infected during the summer of 1915 on guinea-pigs. The original strain was recovered three years previously by Dr. Fricks, and had been maintained wholly in guinea-pigs.

Strain II. was started in February, 1916, from defibrinated blood sent by Dr. Fricks. This blood came from a guinea-pig of the same series upon which the ticks used to start

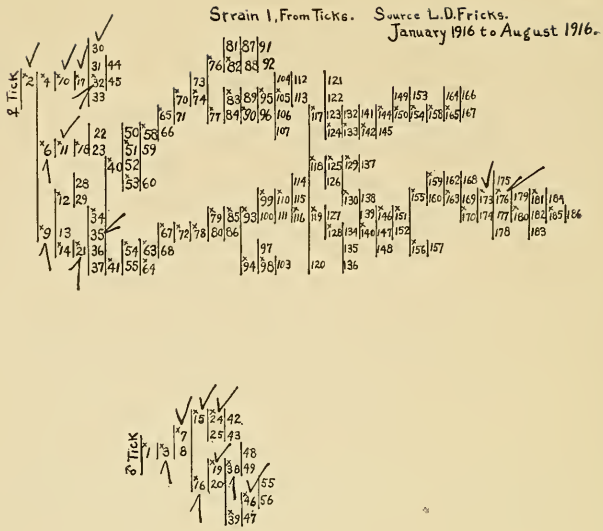

CHART 1.

Record of Strain I.—The numbers refer to guinea-pigs. Each "generation" occupies a vertical column. × indicates those used to furnish blood for inoculation of the guinea-pigs recorded in the next column. √ indicates those studied histologically and in which the parasite was demonstrated.

Strain I. were fed, and the only difference between Strain I. and Strain II. was that the former had been passed through ticks, while the latter had been maintained by continuous passage through guinea-pigs, first inoculated from the human case. The record of Strain II. is shown in Chart No. 2.

Another strain obtained from Surgeon L. D. Fricks, I have called the Darby strain, because the source was a case which occurred near Darby, Mont., near the head of the Bitter Root Valley. The ticks were fed on an infected guinea-pig during the summer of 1915 by Dr. Fricks; the guinea-pigs were infected from a human case contracted near the village of Darby. This strain was maintained by me for a comparatively short time from a guinea-pig infected by a tick which was numbered XXVII (Chart 3). Seven of these original ticks from Dr. Fricks, two males and five females, were attached to seven different guinea-pigs. All transmitted the disease. Type examples are shown in the protocols on page 91, under "Adult ticks proved to be infective."

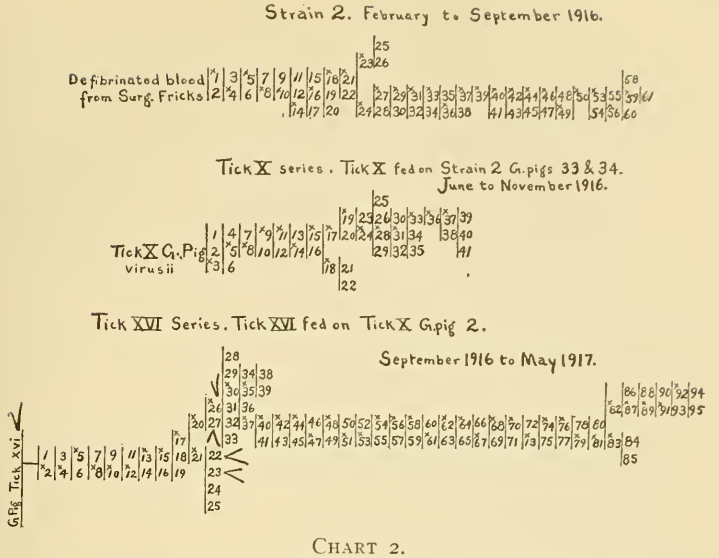

CHART 2.

Record of Strain II. with the series maintained from ticks infected from Strain II. — The numbers refer to guinea-pigs. Each "generation" occupies a vertical column. × indicates those used to furnish blood for inoculation of the guinea-pigs recorded in the next column. √ indicates those studied histologically and in which the parasite was demonstrated.

A fourth strain was started in November, 1917, from two guinea-pigs sent from Washington by Surgeon L. D. Fricks. This strain was secured in the summer of 1915 from a case in Touro County, Cal., and, according to Dr. Fricks, had been passed through guinea-pigs not more than twenty-five times, and had never been passed through ticks in the laboratory. This strain I have called the California strain, and a record of the transfers is shown in Chart No. 3.

Hayes strain. — This strain was obtained by me from a case contracted on O'Brien Creek, a tributary of the Bitter Root River, near Missoula, Mont. Two guinea-pigs were inoculated May 7, 1917, each with 5 c.c. of a mixture of equal parts of blood and citrate saline solution, twenty minutes after withdrawal of the blood from the patient.

Record of temperatures: Guinea Pig 1. — May 7, 103; May 8, 104.4; May 9, 102.2; May 10, 103.4; May 11, 105; May 12, 103; May 13, 105.8; May 14, 105.6; May 15, 102.4; May 16, dead.

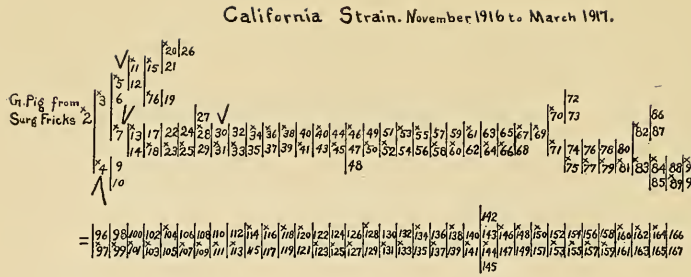

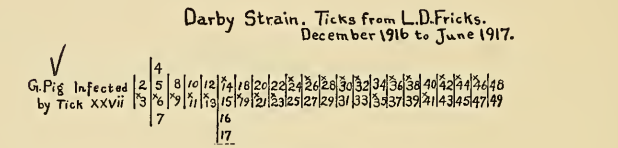

CHART 3.

Record of California strain and Darby strain. — The numbers refer to guinea-pigs. Each "generation" occupies a vertical column. × indicates those used to furnish blood for inoculation of the guinea-pigs recorded in the next column. √ indicates those studied histologically and in which the parasite was demonstrated.

The autopsy showed the typical lesions of Rocky Mountain spotted fever.

Record of temperatures: Guinea Pig 2. — May 7, 103; May 8, 103.6; May 9, 102.6; May 10, 103.6; May 11, 104.2; May 12, 106; May 13, 104.2; May 14, dead.

The autopsy showed the typical lesions of Rocky Mountain spotted fever.

Adult unfed ticks furnished by Dr. W. V. King, secured by dragging in the vicinity of Florence, Mont., were fed on Guinea-pig 1 between May 14 and 16, until the death of the guinea-pig. The strain was established in Boston by attaching two female ticks and one male tick of this series to a normal guinea-pig on June 2, 1917.

Record of temperatures: Hayes' Guinea Pig 3. — June 2, no temperature; June 3, no temperature; June 4, 100, all three ticks were feeding; June 5, 101.6; June 6, 101; June 7, no temperature; June 8, 102.1; June 9, 101.6; June 10, no temperature; June 11, 103, ticks removed almost fully engorged; June 12, 103.6; June 13, 105.1.

Guinea-pig killed on June 13 for inoculations. Post-mortem showed the spleen enlarged to double its size, marked injection of the testes and polar

fat of both testes and the inguinal nodes enlarged and reddened. Other tissues of the body were negative. Four guinea-pigs inoculated from this guinea-pig all developed the disease in characteristic form on the fourth day after inoculation. A record of these transfers is shown in Chart 4.

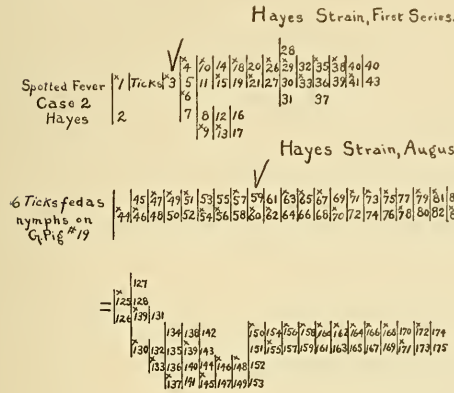

CHART 4.

Record of Hayes strain established from Case II. and reëstablished in guinea-pigs from ticks infected on No. 19 of the original series. The numbers refer to guinea-pigs. Each "generation" occupies a vertical column. × indicates those used to furnish blood for inoculation of the guinea-pigs recorded in the next column. √ indicates those studied histologically and in which the parasite was demonstrated.

From time to time during the course of the work strains transmitted from the above by ticks were maintained in guinea-pigs and recorded according to the number of the tick. For example, Tick X. strain was transmitted by Tick X., which was fed on Guinea-pigs 33 and 35 of Strain II. Tick XVI. strain was transmitted by Tick XVI., which was fed on Guinea Pig 154 of Strain I., and on Guinea Pig 2 of the Tick X. strain. These records are shown in Charts 4 and 5.

The Hayes strain was passed through ticks a number of times; for example, Guinea Pig 44 of this strain was infected by ticks fed as nymphs on No. 19.

Hayes tick strain, August, 1918. This strain was established from four ticks fed as nymphs on Guinea Pig 19, Hayes strain. The protocol of this feeding experiment is entered on page 97, under "Ticks infected as nymphs, some of which were proved to be infective." Tick A, Hayes strain, was

established by feeding nymphs raised from eggs deposited by Tick A between June 21 and June 30, 1918. The larvæ hatched between July 20 and July 29, 1918. They were fed, between August 1 and August 8, on a normal guinea-pig. They molted to nymphs between August 19 and August 23. The nymphs were fed on Guinea Pig 13, Hayes tick strain of August, 1918, September 18 to September 26. Some of the engorged nymphs molted to adults between October 22 and November 4. The strain was established by allowing two male ticks of this series to feed on a normal guinea-pig December 19 to December 24. The record of the strain is shown in Chart 5.

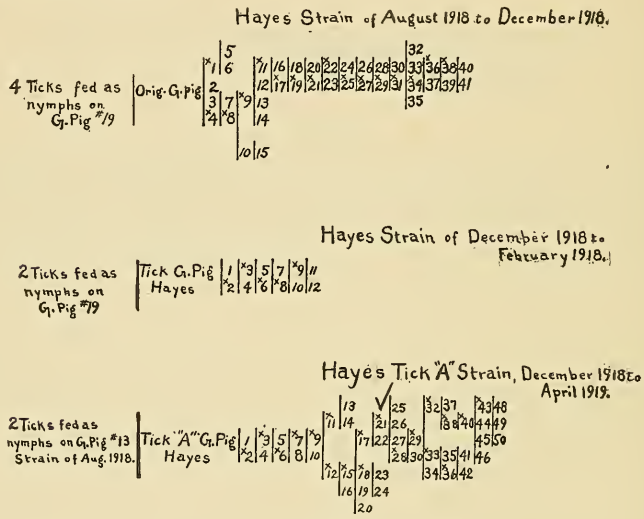

CHART 5.

Record of Hayes strain tick series established in 1918. — The numbers refer to guinea-pigs. Each "generation" occupies a vertical column. × indicates those used to furnish blood for inoculation of the guinea-pigs recorded in the next column. √ indicates those studied histologically and in which the parasite was demonstrated.

2. The identity of the strains used. — The above strains of the virus used were tested at different times in order to settle any doubt as to their identity. As Ricketts showed, recovery from an attack of spotted fever in the guinea-pig leaves a lasting immunity. I have frequently verified this,

and assume that if one strain confers immunity against another, they are identical. Ricketts[14] by this method showed that the strains of virus from Idaho and Montana were identical in nature.

Strains I. and II. came from the same source, as noted above. The California and Darby strains were crossed with Strain II. and with each other with negative results. The Hayes strain was crossed with Strain II. with negative results. Type protocols of these experiments follow.

The immune Strain II. guinea-pig used for testing with the California strain was infected by Tick XIV. Tick XIV. was fed on Strain II. Guinea Pig 39, July 12 to 15, 1916. It fed August 2 to 7 on a normal guinea-pig which was recorded as Tick XIV. guinea-pig of August 2.

Record of Tick XIV. guinea-pig of August 2.

Temperature after removal of tick: August 7, 102.2; August 8, 103; August 9, 104; August 10, 106; August 11, 106.1; August 12, 105.8, scrotum swollen and red; August 13, August 14, 105.2; August 15, 105.2; August 16, 103.8; August 17, 102.8; August 18, 103, scrotum nearly normal, the site of the tick bite is markedly indurated; August 19, 102.8; August 20, 102.8; August 27, 102; September 2, 102.

On December 5 this guinea-pig was inoculated intraperitoneally with 1 cubic centimeter of blood in citrate saline solution from California Guinea Pig 3, with completely negative results, as shown by the temperatures.

December 5, 6, 102; December 7, 102.4; December 8, 101.4; December 9, 101.6; December 10, 11, 101.2; December 12, 101.6; December 13, 101.6; December 14, 101.4; December 15, 101.6; December 16, 102.

Result: Immune Tick XIV. (Chart 2) guinea-pig of Strain II. was proved immune to the California strain from California Guinea Pig 3.

Darby strain and Strain II. (and California strain). — Tick XIV. guinea-pig which proved immune as shown above the California strain was inoculated intraperitoneally on February 17, 1917, with .5 cubic centimeters of blood in citrate saline from Darby strain Guinea Pig 13, with completely negative results.

Temperatures: February 19, 101; February 20, 101.2; February 21, 101.4; February 22, 101.8; February 23, 101.2; February 24, 101; February 25, 26, 100.4.; February 27, 101.

This guinea-pig lived until July 13, 1918, and presumably died of old age.

Result: Immune Tick XIV. guinea-pig of Strain II. and California strain was proved immune to the Darby strain.

Hayes strain and Strain II. — The immune guinea-pig used for this test was No. 7 of Tick X., Strain II. (Chart 2). This sub-strain was transmitted by Tick X. which was fed on Guinea Pigs 34 and 35 of Strain II.

Temperature of Tick X. strain, Guinea Pig 7, inoculated from No. 5, August 5, 1916. August 5, 102.8; August 8, 104.8; August 9, 105; August 10, 105; August 11, 105.4; August 12, 104; August 13, 14, 105; August 15, 103; August 16, 102.4; August 17, 103; August 18, 103; August 19, 103; August 28, 103; September 5, 102.

On July 20, 1917, eleven and a half months later, it was inoculated intraperitoneally with .5 cubic centimeters of blood in citrate saline from Hayes strain Guinea Pig 26.

Temperatures: July 20, 103; July 21, 102; July 22, 23, 101; July 24, 100.6; July 25, 100; July 26, 102.4; July 27, 100.6; July 28, 101.

Result: Immune Tick X. Guinea Pig 7 (Strain II.) was proved immune to the Hayes strain.

Conclusions: As Strains I. and II. were identical and guinea-pigs immune to Strain II. were also immune to the Darby, California and Hayes strains, and guinea-pigs immune to the California strain were immune to the Darby strain, we may conclude that the viruses of these strains were identical.

IX. THE EXPERIMENTAL TRANSMISSION OF ROCKY MOUNTAIN SPOTTED FEVER BY TICKS.

1. Transmission. — Ricketts[50, 52, 53] and his associates showed that the larvæ of *Dermacentor venustus* when fed upon infected guinea-pigs remained infective in the nymph stage, and that nymphs, when infected, remained infective after reaching the adult stage. He also showed that eggs from infected females would produce the disease when injected into guinea-pigs. He found that both male and female ticks would transmit the disease. Maver,[32] working under his direction, found that *Dermacentor marginatus*, from Utah, *Amblyomma americanum linnæus* from Missouri, and *Dermacentor variabilis* from Massachusetts can transmit the virus of Rocky Mountain spotted fever. In the case of *Dermacentor venustus*, Moore,[39] working under the direction of Ricketts, found that a minimum period of feeding of one hour and forty-five minutes was required to infect ticks so that they would transmit the disease. The average time was about ten hours, while he states in his conclusions that twenty hours' feeding

was almost certain to infect ticks. The minimum incubation time in ticks was not determined.

This phase of the tick transmission problem needs further elucidation. I have not been able to infect adult ticks with the same ease. Ricketts[52] stated that individual ticks varied greatly in the ease with which they could be made infective by feeding on infected guinea-pigs. He records ticks which did not become infected by a single feeding for periods of eight to fourteen hours, and he also expressed the opinion that it was more difficult to infect male ticks than female ticks.

My own results have borne out the difficulty of infecting adult ticks in intermittent feedings. The minimum time of feeding in all my experiments was two days. It was frequently impossible to infect a tick in two feedings of two days each, but males became infective as easily as females. Protocols of experiments in tick transmission where two and three feedings were required are entered under the heading of "Adult ticks which were proved to be infective." In fifteen experiments I have made, the results summarize as follows: Four were infective after a single feeding. Two were infective after two successive feedings. Four were infective after two feedings, having failed to infect guinea-pigs in a test following the first feeding. One required three feedings to make it infective, the tests after the first and second feedings having proved negative. Three ticks failed to become infective after a single feeding, and were not used further. One tick failed to become infective after two feedings, and could not be used again, as it became fully engorged.

The minimum incubation period in the tick has not been determined. The shortest time after a single feeding in my experiments was that of Tick XI., a male, which was fed July 28 to July 30 on an infected guinea-pig. It was fed August 2 to August 7 on a normal guinea-pig, which on August 7 had a temperature of 106° F., and ran a typical course of Rocky Mountain spotted fever. Making an allowance of four days as the usual incubation period in the guinea-pig, the incubation period in the tick could not have been more than six days, and probably not more than five days, in

this experiment. The length of time that the virus will survive in the tick has not yet been determined fully. The longest period of my experiments was that in the case of ticks infected as nymphs between July 2 and July 11, 1917, and which transmitted the disease as adults by feeding between December 19 and 24, 1918, a period of seventeen months. The protocol of this experiment is recorded under "Ticks infected as nymphs, some of which were proved to be infective in the adult stage."

2. The care and feeding of ticks. — In working with infected or presumably infected ticks, means must be taken for preventing losses. For that reason a careful count should be made each time the containers are opened, and but a small number of ticks kept in a single container. The most convenient containers are small pill boxes, kept inside of metal ointment boxes. The latter are perforated in order to insure access of moisture, which is of great importance if the ticks are to be kept for a long time. An excess of moisture favors the growth of molds, which is usually fatal to the ticks. I have found that the best method is to place the perforated ointment boxes containing the ticks inside an air-tight jar, and to supply moisture by means of moist filter paper or cotton kept out of contact with the boxes.

For the greatest longevity of ticks, storage in a cold room at 7° C. to 10° C. has given the best results. At this low temperature the ticks would dessicate rapidly if they were not kept in a moist atmosphere inside of an air-tight receptacle.

In feeding a number of ticks on the same animal, individual ticks may be marked by amputating the tarsus on one or more legs. The feeding of individual ticks or a small number of ticks may be easily and safely done by placing the ticks in a small wire gauze cage, and attaching to the animal by means of surgeons' adhesive plaster. These gauze cages, for attaching to guinea-pigs, may be 1.5 centimeter to 2 centimeters in diameter, and .5 centimeter to .8 centimeter deep. I have made them in the shape of a shallow cylinder with a flanged edge, like a man's straw hat, in order that they may be sewed

to the non-adhesive surface of adhesive plaster. After the cages are sewn to the adhesive plaster, a circular aperture is cut in the plaster as large as possible. (Figs. 3 and 4.) If the ticks are violently agitated in a test tube before introducing them into the cage, they will remain stationary for a brief period, during which the cage can be applied and fastened to the shaved abdomen of a guinea-pig or other animal. After the cage is attached in position, a swath of two-inch adhesive plaster is wrapped around the animal, for the purpose of more securely fastening the cage; a hole should be cut in the adhesive plaster swath large enough to permit the cage to project through it, and tight enough to grasp the flange, and keep the latter applied to the underlying adhesive plaster. (Fig. 5.)

In feeding larvæ and ticks it is almost impossible to keep count of the numbers. The method I have employed was suggested by one used by Surgeon L. D. Fricks. (Personal communication.) The uncounted larvæ or nymphs are introduced in their original container into a large battery jar containing the animal upon which they are to feed. The inner surface of the jar near the top is ringed with a heavy layer of vaseline one or two centimeters broad. In order to absorb excreta there should be three to four centimeters of clean white sawdust on the bottom of the jar. After preparations are made for covering the jar with a fine-meshed wire gauze or tightly woven cloth, the containers of the larvæ or nymphs may be opened by means of long forceps, and the cover quickly applied and made tight by means of adhesive plaster. Food may be introduced at any time through a slit which may be cut in the cloth or gauze top, and subsequently sealed with adhesive plaster. At the end of three days the guinea-pig with the attached ticks should be quickly transferred to a similarly prepared jar, and the first jar placed in an already heated Arnold sterilizer, in order to kill the ticks which have not attached. As a precaution against loss by ticks dropping from the guinea-pig while the transfer is being made, the manœuver should be accomplished over a white surface. A bottle of xylol or benzol should be at hand for the drenching

of any surface suspected to harbor escaped nymphs or larvæ. The animal is allowed to remain in the second jar until the engorged nymphs or larvæ have dropped. A few unengorged individuals may be found on the sides of the jar or caught in the grease ring. The animal, after removal, should be immediately transferred to a clean glass jar, and etherized, when it may be conveniently searched for attached ticks, or rendered innocuous by drenching with xylol or benzol. The engorged larvæ or nymphs can be detected easily in the sawdust, which should be transferred to shallow glass dishes. In order to handle the engorged larvæ and nymphs without injuring them, I have employed metal forceps with thin cardboard extensions of the points, making it possible to grasp them firmly without crushing them. By this method of feeding the immature stages of the ticks, a great many individuals are lost. I have been able to recover about fifty per cent of those introduced into the jars. Its advantage is safety.

In raising ticks from eggs I have usually transferred each engorged and impregnated female to a small wide-mouth glass bottle, stoppered with cotton covered with linen, to prevent the larvæ from becoming entangled in the cotton fibers. During the period preceding and during oviposition, the female should be kept in semi-darkness, in a slightly moist atmosphere. After the eggs are deposited the dead female should be removed and the eggs allowed to incubate in the original receptacle, whence, after hatching, they can be introduced into a jar with the animal upon which they are to feed.

3. The intermittent feeding of adult ticks. — It is possible to induce an adult female tick to feed as many as five times at fairly widely separated intervals (see protocols of "Adult ticks proved to be infective," page 91). It is important, however, that the ticks should be detached without injuring the mouth parts, and this can be done only with certainty by grasping the epidermis of the animal with sharp-pointed stout forceps and tearing away that portion to which the tick is attached. The procedure can be done best with the aid of prism magnifying binoculars, as manufactured by Zeiss or Bausch and Lomb, and which have been exceedingly useful for this purpose.

X. DISSECTION AND INTERNAL ANATOMY OF TICKS.

1. The dissection of ticks. — A binocular dissecting microscope with erecting prisms is an absolute essential. The instruments I have found most useful are small knives ground into different shapes, made from cataract and iridectomy knives. The shaping and sharpening should be done under the dissecting microscope, and the finest jewelers' oilstones used. The shapes of the knives I have found most useful are shown in text-figure 1. Mounted needles ground with a

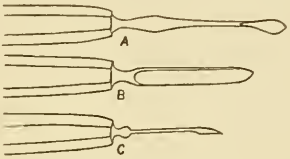

FIG. 1.

cutting edge can be made quickly. Fine blunt-pointed mounted needles are very useful for removing tracheæ and separating organs. Two stout yet very finely-pointed forceps are needed, and these must be pointed by the worker. I have found it advantageous to grind the points as fine as possible, sharper than ordinary needles, with a fairly abrupt taper in order to get correct apposition of the points in grasping objects.

The ticks, in rapid work, are dissected under salt solution (.8 per cent NaCl) in a circular trough made of paraffin and lampblack; the black color is advantageous for the contrast it gives. The trough should be molded upon a glass or metal plate which can be clamped to the microscope stage.

The ticks for dissection are fastened by pinning to the trough with a fine entomological needle passed through the body at the base of the capitulum. The first cut is made completely around the body of the tick through the integument along the lateral margins. In dissecting partially fed ticks it is easy to make this cut without injuring the intestinal diverticulæ by squeezing the margin of the tick with a fine-pointed forceps, which displaces the viscera at that point. The knife — and I have found a rigid round-pointed knife

with a very keen edge shaped like A (text-figure 1) best for this purpose — is passed between the blades of the forceps. The cut is begun at the posterior border and then extended anteriorly on each side until the camerostome is reached, each extension of the cut being made between or close to the blades of the forceps. In dissecting engorged ticks much practice is required, as it is impossible to displace the viscera by squeezing. My procedure has been to fasten the tick in a glass trough with an adhesive mixture of beeswax, pitch and resin, which is warmed and the tick pressed into it. It has been advantageous to melt the mixture with a hot wire at the point to which the tick is to be fastened. This method assures stability of the tick and the first cut can then be made while supporting the point of the knife against a needle or forceps held close to the side of the tick. After the cut along the margins of the tick is finished, if fastened by a pin, a second pin should be passed through the ventral surface near the posterior edge, after having pushed the organs away, in order to keep the tick in position while removing the dorsal surface. The dorsal surface is removed by grasping the rear end with the forceps and with a round-bellied knife (A or B, text-figure 1), carefully scraping away the hypoderm. The base of the capitulum should be carefully disarticulated and left attached to the ventral surface.

With sufficient practice it is possible to remove the dorsal surface, leaving the organs intact and enclosed in the hypoderm. Portions of the various organs may now be removed for smear preparations, after incising the hypoderm, by grasping with the forceps and cutting with the fine sharp-pointed knife (C, text-figure 1), or with a needle with a cutting edge.

While becoming familiar with the anatomy of the tick, the blunt-pointed needles are useful to separate the organs for the purpose of identification.

For section work the dissection is completed by detaching the ventral hypoderm from the chitinous integument, best done by carefully elevating the whole with a blunt needle at the posterior border and gradually working forwards by

lifting and scraping against the integument with a round-bellied knife. A keen edge is needed in cutting through the leg muscles, in order to avoid tearing the hypoderm. After the ventral surface of the organs enclosed by hypoderm has been freed, the base of the capitulum is disarticulated from the ventral surface and left attached to the organs. The capitulum serves as a convenient handle in transferring the organs from one solution into another.

A pipette fitted with a rubber teat is necessary to remove and replenish the salt solution during dissection in case the intestinal diverticulæ are ruptured, as the contents cloud the solution. The pipette is also useful to create currents in the dissecting solution for the displacement of organs while determining relations.

When dissecting for anatomical study it is sometimes advantageous to replace the saline solution with an .8 per cent NaCl solution containing three per cent commercial formol. This fluid hardens the organs and makes them retain their shapes; it also makes them somewhat tougher and less liable to rupture.

2. Internal anatomy of *Dermacentor venustus* (Figs. 18 and 19). — The following brief description of the gross internal anatomy of *Dermacentor venustus* is given for the purpose of making the text references to the various organs understandable.

The internal anatomy of the different genera of ticks varies but slightly, so that the descriptions of ticks other than *Dermacentor venustus* are of great help, and the reader is referred to the excellent descriptions in Patton and Cragg's textbook, and to the articles of Samson,[60] Christophers[8] and Robinson and Davidson[57]; the last-named paper on the anatomy of *Argas persicus* is exceptionally complete.

After reflection of the dorsal integument, in the living tick, the heart can be seen beating in the median line, over the central portion of the alimentary tract, i.e., stomach or mid-intestine. It lies just anterior to the middle portion of the body of the tick, or just posterior to the level of the third coxa. In *Dermacentor venustus* it appears as a flattened

spheroid with four lobulations. Running anteriorly from it is the main blood vessel, or aorta, a translucent walled tube of considerable strength, which passes forward in the median line, descending to empty into the periganglionic sinus just anterior to the mid-intestine.

The dissection of the alimentary tract is best accomplished by carefully freeing the salivary glands, and removing them from the body cavity, and then carefully detaching the tracheæ from the organs. This can be done easily if the larger tracheal trunks are grasped with the forceps and, while under tension, the smaller branches are combed away from the organs with a blunt-pointed needle. The œsophagus can be seen coming from the pharynx, and, entering the brain anteriorly on the ventral side, it passes backwards and emerges on the dorsal surface of the brain near the posterior margin, where it enters the mid-intestine or stomach. The mid-intestine is a short tubular organ, and, together with the diverticulæ, is thin-walled and transparent, and always contains dark brown to black contents. From the mid-intestine or stomach arise the diverticulæ and hind intestine or rectum. The hind intestine arises from the ventral side of the mid-intestine, slightly anterior to its middle portion, and descends ventrally and posteriorly to open into the rectal sac. The rectal sac, in its partially filled state, appears opaque whitish. It presents four lobes, two anterior, which embrace the lower end of the hind-intestine, and two posterior lobes, which are shorter than the anterior, and embrace the anus. The anus arises on the ventral surface of the posterior margin of the rectal sac. Opening into the rectal sac, close to and on each side of the median line on its ventral surface, near the junction with the hind-intestine or rectum, are the two Malpighian tubes.

(*a*) The intestinal diverticulæ (Fig. 18). — The anterior end of the mid-intestine divides into two main trunks, a right and left anterior lateral division, each of which gives off three branches; an anterior diverticulum, which is short but which reaches to the anterior end of the body on the dorsal surface;

a median branch, which takes a slightly tortuous course to the anterior end of the body on the dorsal surface; and a posterior branch, which is much the larger of the three. This posterior branch divides soon after its origin at about the level of the third coxa, into two secondary branches, an external branch, which turns backward and forward and then upwards near the lateral margin of the body, and an internal branch which gives off a tertiary branch at the level of the posterior margin of the fourth coxa. The tertiary branch descends and then runs anteriorly close to the lateral margin of the body along the ventral surface to a point between the first and second coxæ. The main internal (secondary) branch is continued backwards along the dorsal surface to the posterior lateral margin, descends to the ventral surface, and is then directed anteriorly and inwards, almost reaching the median line. It terminates just anterior to the brain, and lies in contact with the lateral surface of the brain; its tip may curve inwards so as to embrace the anterior surface of the brain. This branch is one of the largest of the intestinal diverticulæ.

The posterior end of the mid-intestine or stomach divides into a right and a left posterior lateral division, each of which in turn divides into two branches, a lateral and a median branch, both of large size. The lateral branch curves outward and backwards on the dorsal surface, descends to the ventral surface at the posterior margin of the tick, and curves forward to terminate somewhere between the posterior margin and the rectal sac. It usually terminates on the dorsal surface of the rectal sac, but may terminate at the posterior margin. The median branch passes backwards, descends to the ventral surface at the posterior margin of the body and extends on the ventral surface of the body close to the median line to the anterior end, ventral to all organs, and in contact with the uterus. Its blind ending is usually found just anterior to the brain.

(*b*) The Malpighian tubes. — The Malpighian tubes in the dorsal dissection appear on each side as delicate tubes with opaque white contents near the median line. Each tube

forms a sharply flexed loop near the median line dorsal to and at the level of the anterior lateral divisions of the alimentary tract. The two arms of this loop at first lie in close contact (7 in Fig. 18). Their course is tortuous, and posteriorly they separate, one disappearing between the median and lateral branches of the posterior lateral division of the alimentary tract, the other external to the lateral branch of this division, and internal to the internal (secondary) branch of the posterior branch of the antero-lateral division of the alimentary tract. The course of the Malpighian tubes is best studied from a ventral dissection. Each takes origin on the ventral surface of the body, lateral to and anterior to the brain, near the posterior margin of the basis capituli. It passes outwards and backwards near the ventral surface through the divisions of the salivary glands, where it makes a number of turns, again passing posteriorly and coiling around the main tracheal trunks. It then passes to the dorsal surface of the body, between the lateral branch of the posterior lateral division and the internal secondary branch of the posterior (third) branch of the antero-lateral division, and goes forward to form the loop already described. The distal arm turns posteriorly to disappear between the median and lateral branches of the posterior lateral division of the alimentary tract, whence it passes to the ventral surface of the body, travels anteriorly to reach a point at about the junction of hind-intestine and mid-intestine, and finally backwards to terminate in the rectal sac (Fig. 19). In its course the Malpighian tube lies in contact with every organ in the body, parallels the ovary for a considerable distance, and in its distal portion lies in contact with the oviducts.

(*c*) The salivary glands. — The salivary glands are recognizable with ease because of their characteristic appearance, which is very much like that of a bunch of grapes. They have a porcelain-white appearance, and lie on each side of the body over the bases of all four legs. They lie in contact internally with the uterus, oviducts and ovaries, dorsally and ventrally with the coils of the intestinal diverticulæ. They

are traversed by the Malpighian tubes. The main duct of the salivary gland, considering the size of the organ, is very small, but can readily be found as a transparent tube entering the pharynx.

(*d*) The female reproductive system (Fig. 19). — This description is from a partially fed, unimpregnated female. In the dorsal dissection of the tick, the ovary is easily recognized as a translucent whitish organ studded with ova running transversely across the dorsum of the rectal sac, but ventrally to the origin of the posterior intestinal diverticulæ. From this point it can be traced forwards and upwards, along a tortuous course, to the anterior half of the body, where it becomes continuous with the small calibered oviduct. The oviduct passes forwards and inwards to make a loop near the vagina. The returning arm passes backwards again and forms a loop near the junction of the oviduct and ovary. The distal arm returns in contact with the other two arms and joins the oviduct on the opposite side to form the sacculated uterus. The three arms forming these loops of the oviduct lie in close contact and in a horizontal plane. The vagina is a relatively large organ which passes ventrally and anteriorly to open into the genital aperture. On the dorsal surface of the vagina are two tubular glands, one on each side — the accessory glands.

(*e*) The brain (3 in Fig. 19). — The brain is a relatively small white organ, in shape a flattened spheroid, with the posterior margin slightly truncated. It lies in the triangle formed by the bifurcation of the intestinal tract posteriorly and the salivary glands on each side, approximately at the level of the second coxa. It gives off nerve trunks of relatively large size, the distribution of which has been determined for other ticks, particularly *Argas persicus*. One can recognize in *Dermacentor venustus* the posterior branches, so-called " splanchnic " nerves, four lateral branches, going to the four legs, and delicate branches going anteriorly, two on each side of the median line, and presumably corresponding to the palpal and mandibular nerves of *Argas*.

(*f*) The male reproductive organs. — The testis occupies practically the same position as the ovary in the female, and in the mature tick (*D. venustus*) occupies a large part of the body cavity. Posteriorly it forms several large loops on each side between the loops of intestinal diverticulæ. Anteriorly the testis on each side tapers gradually to pass into the much smaller calibered vas deferens, which makes several loops at about the level of the genital aperture, on each side of the ejaculatory duct. The distal arm of the loop finally passes posteriorly and ventrally between the coils of the accessory glands to form another loop, and turning forward becomes much increased in caliber. The dilated terminal ends of the vasa deferentia lie in contact, side by side, entirely surrounded by the accessory glands; they terminate anteriorly in the seminal vesicle which lies in a position corresponding to the uterus in the female, and is also concealed from all sides by the accessory glands. Anteriorly and inferiorly the seminal vesicle is continued into the ejaculatory duct which communicates with the genital aperture corresponding to the vagina in the female.

The accessory gland forms a complex arrangement of curved tubes of large size, bilaterally symmetrical, opening into the ejaculatory duct. In *D. venustus*, opening directly into the ejaculatory duct, are two short, opaque, white glands on each side, a pair anterior and ventral in relation to a pair which lie immediately dorsal and posterior. The remaining lobes which form the bulk of the mass of accessory glands are three in number on each side, and take origin from an unpaired median structure which passes backwards and then upwards and forwards, encircling the proximal end of the ejaculatory duct and terminates in two short arms which lie dorsal to the seminal vesicle. This median lobe on the ventral side is of small caliber, where it turns upwards and forwards; it becomes of large size and gives off four sacs, two on each side; the first pair at the point of flexure are the larger, the second pair are immediately anterior to the first or at the beginning of the dorsal arm of this median lobe. Between these sacculations and the bicornuate end the lobe presents a fusiform

shape. The lateral lobes arising from this median lobe all take origin from the ventral or proximal arm, all close together and near the ejaculatory duct. The first pair of lobes are of large size and each divides into two arms which pass dorsally and meet their fellows in the median line above the dorsal arm of the median lobe. The second pair are short, thick lobes which lie on each side of the ventral arm of the median lobe. The third pair are long, slender lobes which extend backwards, parallel to the median line and terminate close to the posterior margin of the body.

XI. TECHNIC.

1. The formula for the Giemsa stain used is: Azur II. eosin (Gruebler), 3 grams; Azur II. (Gruebler), .8 grams; Merck's reagent methyl alcohol, 375 grams; Merck's reagent glycerine, 125 grams.

2. Technic of making smear preparations from ticks and animals. — In making preparations from the tick organs it is advisable to tease the tissue apart with very sharp needles under the dissecting microscope in a drop of .8 per cent salt solution, rather than to crush the tissues. Whereas the micro-organisms are easily demonstrable in cells or fragments of cells, they are found with considerable difficulty outside of these situations, and for this reason I have even entertained the hypothesis that the microörganisms possess great fragility. The preparations made in this manner are air dried, fixed in absolute alcohol for fifteen to twenty minutes, and stained in Giemsa's stain diluted in proportions of one drop to one cubic centimeter of distilled water. The preparations should be allowed to stain for two to four hours.

For the demonstration of the parasites in smear preparations from animal tissues, much patience is required in order to obtain suitable material. It is useless to look for the organisms in preparations made by crushing tissues from any source. I have found them only in preparations made from the cutaneous and subcutaneous tissues in monkeys and

guinea-pigs, and the tendon sheaths in guinea-pigs. As they are situated almost exclusively in the walls of the blood vessels, it is necessary to disintegrate these structures, and this I have accomplished by putting the tissue upon the stretch and patiently scraping with a very sharp razor held vertically and passed across the tissues with an oblique sliding motion. If the under surface of the skin from the scrotum of infected guinea-pigs and monkeys is treated in this way, and the material accumulating on the razor edge be carefully separated and fixed upon slides, it is usually possible to obtain cells containing the organisms. As in the case of smear preparations from ticks, organisms outside of cells are almost impossible to find, even though the preparations are made from regions proved by sections to contain them in large numbers.

In smear preparations, as in sections, the parasite of Rocky Mountain spotted fever decolorizes by Gram's method. It is difficult to stain with ordinary aniline dyes, and only Giemsa's stain has given good results.

3. Histological technic. — Tick tissues and mammalian tissues have been treated alike during the latter half of this work. The method employed with best results is a modification of Giemsa's stain. The tissue is fixed in Zenker's fluid thoroughly saturated with corrosive sublimate, and preferably without the addition of acetic acid. After embedding in paraffin and sectioning, slides are treated in the usual way, except that an extra step is taken to insure complete removal of the iodin, which is employed to remove crystals of corrosive sublimate deposited in the tissues. Before placing in water the sections are treated with a half per cent sodium hyposulphite solution for ten or fifteen minutes, and then thoroughly washed in running water followed by distilled water. The slides are stained in a slightly alkaline mixture. For the best results it is essential to start with distilled water free from traces of acid, or to determine by trial the amount of alkali required for the best results. Starting with the neutral distilled water, I have found that two to four drops

of a half per cent sodium bicarbonate solution to one hundred cubic centimeters of water gives the required alkalinity. I have also found it advantageous to retard the precipitation of the dye, and for that purpose add three to four cubic centimeters of reagent methyl alcohol to each one hundred cubic centimeters of water. The formula for the stain which has given the most uniformly good results is: Distilled water, 100 cubic centimeters; .5 per cent sodium bicarbonate, 2 to 4 drops; reagent methyl alcohol, 3 cubic centimeters; Giemsa's stain, 2.5 cubic centimeters.

The stain should be poured over the slides immediately after mixing, and should be changed twice during the first hour, and allowed to remain in the third solution for twelve to eighteen hours. The slides, which are heavily overstained by this method, are differentiated in ninety-five per cent ethyl alcohol. The procedure of differentiation really consists in removing the excess of stain to a point where good histological detail is secured. If the sections are too blue, a better balance may be secured by adding very small quantities of colophonium to the alcohol. After differentiation the sections should be rapidly dehydrated in absolute alcohol, cleared in xylol and mounted in oil of cedarwood.

The various steps in the technic are as follows:

1. Fix in Zenker's fluid (formula: corrosive sublimate, 6 grams, potassium bichromate 2.5 grams). Twenty-four hours should be allowed for animal tissues, but two to six hours for tick tissues is sufficient.

2. Embed in paraffin and section at 5μ or less.

3. Xylol, alcohol, Lugol's solution; alcohol as usual.

4. .5 per cent sodium hyposulphite to remove the last traces of iodin, ten to fifteen minutes.

5. Wash in running water ten minutes, followed by distilled water.

6. Stain, differentiate, dehydrate and clear as above, and mount in oil of cedarwood.

The staining of paraffin sections by Giemsa's stain is no more complicated or difficult than using the eosin-methylene blue stain. One condition, however, is absolutely essential,

and that is that the sections should be thin, not over five microns.

Other methods may be used for the demonstration of the parasite. The eosin, methylene-blue stain will occasionally produce excellent results, but gives less clear pictures. A very satisfactory method, which of course does not suffice for histological study, is to overstain with Loeffler's methylene-blue; for example, one or two hours in the paraffin oven at 55° C. and then differentiate in 1 to 1000 or 1 to 2000 acetic acid in water. After washing in distilled water, the sections should be transferred immediately to absolute alcohol, cleared in xylol and mounted in balsam. The stain recently devised by Goodpasture[91] for demonstration of the influenza bacillus in tissues gives fair results, although confusing because of the intense staining of other material occurring in the lesions. On the whole, Giemsa's stain has proved much the more satisfactory. It is of interest to note that when applied after fixation in Schaudin's fixative, as originally recommended by Giemsa, it is almost impossible to demonstrate the parasites. On the other hand, very excellent results have been occasionally secured after this fixation by the eosin-methylene-blue stain.

XII. THE PARASITE.

1. The parasite in mammals. — Early in the investigation of Rocky Mountain spotted fever in guinea-pigs the conclusion was arrived at that the nature of the lesion in the blood vessels demanded the local presence of a parasite. Le Count[30] was of the same opinion while making his studies on the pathological anatomy of spotted fever.

The first discovery of the parasite was made with the eosin-methylene-blue stain in thin paraffin sections of Zenker-fixed material. It was a surprise to find that Giemsa's stain used with tissues fixed in Schaudin's fixative (two parts saturated corrosive sublimate, one part absolute alcohol) would not demonstrate this organism at all satisfactorily, although giving most excellent results with trypanosomes and relapsing fever

spirochætes in control tissues. In the course of experiments with this stain it was found that the ordinary staining effect could be reversed if the tissues were fixed in Zenker's fixative, and differentiated with ethyl alcohol. By reversal of the stain is meant the staining of chromatin blue and cytoplasm pink, whereas in successful preparations stained after fixation in Schaudin's fixative, the cytoplasm is blue and the chromatin red or purple red, as in smear preparations. The presence of the chrome salt in the fixative seems to be requisite for the uniformly successful demonstration of the spotted fever parasite. A number of methods using alkaline methylene-blue as the principal staining agent which were successful with Zenker-fixed tissues were unsuccessful in tissues fixed in alcohol and formalin, although occasionally giving very fair results with tissues fixed in saturated corrosive sublimate. In the description of the parasite it is necessary to consider the various appearances found in mammalian tissues and in tick tissues. It is much easier to demonstrate parasites both in ticks and mammalian tissues in sections than in smears, a fact which is considered elsewhere in this report. The morphology and distribution in mammalian tissues are identical in all types studied, — man, monkey, rabbit and guinea-pig. White rats and mice were found not to be susceptible.

In sections (Figs. 44, 46, 48, 50 and 63 to 68) the parasite invariably has the form of a minute paired organism, often surrounded by a very narrow but definite clear zone or halo, as if encapsulated. It is very often possible to show that the distal ends of the pairs are tapered, so that the appearance may be likened to that of a diminutive pair of pneumococci. This paired lanceolate form is found in the endothelial cells of the vascular lesions (Fig. 50), and most abundantly in smooth muscle cells of the media of vessels with the lesions; and individual smooth muscle fibers are frequently found completely filled with them (Figs. 48, 64, 66, 68 and 69). Rarely the parasite is found in endothelial cells detached from the vessel walls but usually incorporated in thrombi.

They have also been found outside of blood vessels, in endothelial cells, which collect in and around the adventitia. These lanceolate forms in mammalian tissue are very uniform in size, as seen in sections. The length of a pair ranges from slightly under to slightly over one micron, the width is certainly not over one quarter of the length of the pair, and probably lies between .2 and .3 micron. Rarely in smooth muscle cells a smaller form is found, closely packed, in great numbers, comparable in size to the intranuclear forms in ticks.

In smear preparations of mammalian tissues made by the method described elsewhere in this report, one finds in addition to the lanceolate forms, slender rod-shaped forms, some of which exhibit polar granules (Fig. 29). With the Giemsa stain applied after ethyl alcohol fixation, these slender rods stain delicately pale blue in color. The polar granules stain purplish or reddish. The sharpness of outline usually seen with bacteria, accidentally or intentionally introduced into the preparations, is a marked contrast to the rather vaguely defined outlines of the spotted fever organisms. These rod-like forms often occur in pairs, the individuals of which may be almost a micron in length. In addition to the rods and lanceolate forms in these smears, there are very minute pale-blue staining rounded forms. These rods and minute rounded forms resemble the first forms of the parasite which occur in smear preparations in the intestinal tract of infected ticks.

The demonstration of the parasites in the circulating blood is extremely difficult. Ricketts unquestionably saw this organism in the blood of man and guinea-pigs, and he described it as "having the form of two somewhat lanceolate chromatin-staining bodies separated by a slight amount of eosin-staining substance" — a description which was based on preparations of blood stained by Giesma's stain as furnished by Gruebler. With the Giemsa stain I have been using, the lanceolate bodies in blood films stain reddish or purple, and are separated by a very slight amount of bluish-staining material. In thick film preparations, in which the dried drop of blood is treated with distilled water before fixation in absolute alcohol, the lanceolate or oval paired forms often appear to be surrounded with

a considerable amount of pale bluish-staining material (Figs. 24 and 25). The study of the parasite in the circulating blood has been inadequately done by myself. In one human case (Case II. of this report), they were found in endothelial cells in ordinary blood films, stained with Giemsa's stain, a few hours before death (Fig. 56). I have studied them frequently in thick filmpreparations from monkeys and guinea-pigs, but have been unable to add anything to the above description. I have never been able to find them during the incubation period, but have found them to be rather more abundant towards the end of the febrile period than earlier in the disease, and it is my belief that this form of the parasite exists in the circulating blood only within phagocytic cells, and that their introduction into the circulation is fortuitous, and accounted for by the detachment of endothelial cells from the lesions in the blood vessels.

2. The parasite in the tick (Plates VI. to IX). — In ticks three morphological forms can be found. Inspection of the table accompanying the study of the parasite in ticks infected as nymphs, shows that the first appearance of the micro-organism occurs on and after the fifth day. As seen in smears of the gut contents, these organisms appear as pale-blue bacillary forms (Figs. 20 and 34), some of which are slightly curved and club-shaped, without chromatoid granules. The distinctive feature, however, is the delicacy with which they stain, and their pale-blue coloration with Giemsa's stain. In size, the individual rods are one half to slightly over a micron in length. These forms in ticks have been found with constancy only in the gut of nymphs, and were first found in a day-to-day examination of infected nymphs, undertaken in the hopes of demonstrating a life cycle for the parasite. In the tissues of ticks infected as adults, these forms have been seen, and at first were disregarded because it seemed possible that they were not connected with the parasite of spotted fever. An adequate series of controls shows that they are one form of the spotted fever parasite, and that their presence in the nymph precedes the occurrence of a

smaller delicately-staining bluish rod with deeply-staining chromatoid granules. This minute form of the parasite (Figs. 21, 22, 28, 33, 35) appears in smears in abundance on and after the seventh day, but are most numerous from the seventh to the fifteenth day. They make their appearance earlier in nymphs kept at 37.5° C. than at room temperature. These forms are so small that it is difficult to study them except with high magnification and perfect illumination. The 1.5 millimeter Zeiss apochromatic objective, and a 6 compensating ocular represents the magnification required. The chromatoid dots in these minute rods are often paired and are usually situated at one end. Appearances are found which would indicate that these rods divide by transverse fission, and that the division is preceded by a division of the chromatoid particles, but such evidence is purely morphological. Later on, in smear preparations of the gut and of other organs (Fig. 30), the more deeply staining purplish lanceolate paired organisms are found. In adult tissues these exceedingly minute rods with chromatoid dots have been found only in smear preparations of the Malpighian tubes and salivary glands. In sections of ticks, whether infected in the nymphal or adult stage, all tissues become invaded by the parasite, and in sections of ticks one can distinguish at least two morphological types, the larger lanceolate form, which becomes universally distributed in all tissues, and a much more minute form, which occurs in the nuclei of cells and occasionally packed in the muscle fibers of the intestinal tract (Figs. 37 and 43). The larger forms have been found in abundance in all parts of the intestinal tract and the salivary glands (Figs. 36 and 38), and walls of the salivary gland ducts, in all parts of the reproductive system, male and female, and have been found both in spermatozoa and in ova. The brain and nerve trunks (Figs. 31 and 39) and musculature of the tick (Fig. 40), including muscles of the sucking organs, leg muscles and dorso-ventral muscles, become heavily infected. The parasites are found often in great abundance in the cardiac muscles and in the striated muscle of the aorta. In the salivary glands the parasites are found in both types

of acini, and a few can always be demonstrated in the lumina of the intra-acinal portions of the ducts.

The intranuclear (Figs. 27, 32 and 42) forms are exceedingly minute and are often found completely filling and even distending the nucleus. Because of their small size and tight packing, such masses even in thin sections are difficult to resolve into their individual members. Occasionally in such intranuclear masses of the organisms, a few larger lanceolate paired forms will be found, surrounded by a very thin clear space or halo (see Fig. 27). When these intranuclear forms were first encountered, they were accepted with reluctance as a form of the spotted fever parasite, but I now regard them as the most characteristic form in infected ticks. As Tables IV. and V. show, small bacteria are frequently found in ticks, but in no uninfected tick has this minute intranuclear form been encountered. The distribution of infected nuclei in adult ticks is restricted, as far as I have been able to determine, to the Malpighian tubes, rectal sac, intestinal epithelium and the cells of the salivary gland ducts. In nymphs sectioned during the quiescent period, they have been found in great abundance in the nuclei of the hypoderm, which at this stage is in active proliferation in the formation of new organs. They have been also found in the musculature of the developing adult, as well as in the other locations mentioned. The infected nuclei are found with greatest ease and earliest in the epithelium forming the valve-like junction of rectum and rectal sac. In infected ticks that have been kept for several months, the parasites are less abundant than during the first few weeks. The larger lanceolate forms, however, can always be found in the various organs, and usually the intranuclear forms can be found in the rectal sac and Malpighian tubes. It seems probable that the minute forms found in such numbers in the smear preparations of engorged nymphs are the same as the intranuclear forms and have been liberated by the rupture of cells in the making of the preparations. In support of this point is the fact that in one instance I have been able to find masses of minute

rods with chromatoid granules, lying apparently partly enclosed by the nucleus in a smear preparation.

There is no cellular reaction to the parasite of Rocky Mountain spotted fever in the tick. An absence of reaction to relapsing fever spirochætes (*Spirochæta duttoni*) in *Ornithodorus* has been noted by me.[96]

3. The parasite in the eggs of ticks. — Ricketts records experiments in which the disease was produced by the injection of eggs from infected ticks, an experiment which I have repeated with positive results. The eggs came from Tick XXXII., infected in Montana on Case II., and afterwards used to establish the disease in Boston. Companion ticks are XXXIII. and XXXIV., which are recorded under "Adult ticks proved to be infective." This tick became fully engorged while feeding on Hayes Guinea Pig 3, June 2 to June 11, 1917. On June 28, 1918, one hundred and forty eggs from this tick were crushed and suspended in citrate saline solution, and injected subsequently into a male guinea-pig. This guinea-pig, after an incubation period of seventy-two hours, developed and ran a typical course of Rocky Mountain spotted fever, and from it the strain was re-inoculated for two subsequent passages.

The larger lanceolate form of the parasite was found in smear preparations made from these eggs (Fig. 26). This morphology is entirely different from that of rods in the eggs of uninfected ticks. Figure 23 illustrates the forms frequently encountered in eggs from non-infective ticks, and was drawn from a preparation made by Prof. R. A. Cooley and identified by him as identical with those described by Ricketts. This non-pathogenic bacterium may of course occur together with the spotted fever parasite, and it is probable that Ricketts had the misfortune to work extensively with ticks infected with this organism.

4. Summary. — In lesions of the blood vessels in man, monkeys, rabbits and guinea-pigs, the larger paired lanceolate form of the parasite is invariably present. On Charts 1 to 5

inclusive, the guinea-pigs which have been examined histologically for the parasites are indicated by a check (√), and without exception the parasites have been found. As the protocols of the experiments show, they were found in all of the five human cases, and in all of the few monkeys and rabbits examined. The guinea-pig series is of special value. As will be seen by the chart, the parasite was found in all strains of the virus and in many instances after one or more passages of the virus through ticks; in the case of the Hayes strain it was found in guinea-pigs infected after three passages of the virus through ticks.

In ticks the only conclusion possible from the following experiments is that this organism is pathognomonic of and inseparable from ticks capable of transmitting Rocky Mountain spotted fever. Some significance must be attached to the various morphological types described, and the sequence in which they appear. The initial form in infected ticks is the relatively large delicately-staining rod without chromatoid granules, followed by an exceedingly minute rod form with chromatoid granules. The final form is the relatively large, apparently chromatin-rich lanceolate paired form. It seems logical to believe that this last form represents a resting or perhaps a slightly more resistant stage, as it is the only form that can be demonstrated in the circulating blood. The possibility, however, must be considered of another form in the blood. If the minute rod with chromatoid granules or the intranuclear form does exist in the circulating blood, free or in leucocytes, its demonstration will be a matter of difficulty. I am inclined to believe, if it does exist, that it occurs within leucocytes. I have made repeated and careful attempts to demonstrate this form in the blood without success.

The study of blood from infected animals with the dark field illuminating apparatus has proved futile. All of the forms described in ticks, however, can be seen in preparations from tick tissues. They are difficult to see in the gut contents because of the innumerable large refractive granules which are products of digestion. They are likewise difficult to see in preparations from the salivary gland because of the

granules, probably of an enzyme nature, with which the Type I. gland cell is filled. However, they have been found in all of the tissues of the tick by this method. They are not motile. One characteristic worthy of note is that the contour of the organism with the dark field illumination does not present the refractive contour shown by bacteria. The organism appears as an evenly illuminated short rod exhibiting the same luminosity and contour shown by spirochætes; for this comparison *Spirochæta duttoni* was used.

5. Nature of the parasite. — A decisive conclusion in regard to the nature of this parasite is not justified by the data we have, if by classification we mean associating it with other known parasites, as bacterium, protozoan and spirochæta. The simple life cycle and the bacterium-like morphology are against classifying it among the protozoa. The morphological variations which I have described do not represent a greater range than that exhibited by many well-known bacteria, but, on the other hand, there is a definite morphological sequence to be observed in infected ticks and a more or less specific localization in the tissues of ticks of the various morphological forms. The extreme susceptibility to physical and chemical agents may be accepted as a weak argument against classification with bacteria. The staining reaction which has been dwelt upon in the description is another weak argument, but one nevertheless upon which I am inclined to place some weight, particularly after comparison with many bacteria stained by similar technic. Even with bacteria as small as the influenza bacillus the difference in staining is marked. The viable bacteria always present sharply defined outlines and stain much more intensely, and when treated in exactly the same manner employed for the spotted fever smears, invariably stain a deep purplish. It is true, however, that some bacteria in cultures stain bluish and exhibit chromatoid granules, but not with the same regularity as the spotted fever organisms. The fact that the spotted fever parasite is always intracellular in mammalian and tick tissues, and also intranuclear in the latter, may be

used as an argument against its bacterial nature, and does, I believe, carry some weight, but bacteria in animal tissues often are intracellular, and may occur there in large numbers. Recently Theobald Smith[94] and Tyzzer[95] have called attention to bacteria characteristically intracellular. In my own studies of ticks, bacteria, whenever encountered, have been intracellular, frequently in large numbers (see Tables IV. and V.), though never intranuclear. The sum of the weight of these differences, together with the very unusual feature exhibited in the exact reproduction of the disease in experimental animals, leads me to the conclusion that this parasite represents a new form of microörganism. All things taken into consideration, including the fact of tick transmission, we have but a single reason for considering the classification of this organism with bacteria, and that is its bacterium-like morphology. It would be egotistical to assume that I have excluded all possibilities in the way of a more complicated life cycle. All that I have accomplished is to show that the various stages encountered explain the facts that are requisite to account for the multiplication in ticks and the transmission of the disease. It seems extremely probable that certain spirochætes, such as the relapsing spirochæte, have a definite life cycle, or at least another morphological form, yet reproduction by transverse division is sufficient to account for all of the phenomena associated with the transmission of the disease by ticks.[96]

Convinced that the microörganism of Rocky Mountain spotted fever represents a new type of parasite, I propose the name *Dermacentroxenus* (Dermacentor + ξένος) *rickettsi* for this organism, in honor of Ricketts who first saw it in the blood. The name "Rickettsia" has been applied by da Rocha-Lima[86] to minute bacillary forms found by Hegler and von Prowazek in typhus fever, and regarded as identical with bodies described by Ricketts[85] in Mexican typhus. The available descriptions of Ricketts are too meager to permit a trustworthy comparison with the spotted fever parasite, but as Ricketts's description of the typhus organism, which he regarded as a bacterium of the plague bacillus group, is

markedly different from his description of the spotted fever organism *in blood*, the name "Rickettsia" cannot be considered as applicable to the spotted fever organism, as described in this report. Much more work is required before the classification of "Rickettsia" and its relation to typhus fever can be arrived at.

6. Attempts at cultivation. — After the demonstration of the minute organisms in the lesions of the blood vessels in guinea-pigs and monkeys, a series of cultivation experiments was begun, which was carried through two years until every possible method was tried. Ricketts apparently made exhaustive attempts at cultivation of the virus without success. Fricks[22] claims to have infected guinea-pigs with cultures grown under partial anaërobic conditions in human blood serum diluted with normal salt solution in the proportion of one to two and three. A piece of fresh guinea-pig kidney was added to the medium at the time of inoculation. In the three guinea-pigs which acquired the disease, the cultures were inoculated with blood from a guinea-pig, blood from a human case, and crushed tick eggs respectively. I have been unable to repeat these results, and indeed have found it impossible to make the virus survive in any culture medium for a period equal to that in defibrinated blood.

All of the ordinary bacteriological media have been tried under all conditions of temperature and oxygen supply. The various methods for securing partial anaërobiasis successful in the cultivation of *Bacillus abortus* were employed without success. The methods of growing spirochætes devised by Noguchi were tried, and in these experiments the criterion for a suitable ascitic fluid was the successful cultivation of *Spirochæta duttoni*. Several liquid and solid media containing hemoglobin which proved to be suitable for the cultivation of *Trypanosoma lewisi* were used, including the Novy-McNeil-Nicolle medium, and the medium used by myself, Chapman and Stevens[97] for growing trypanosomes for filtration experiments. A variety of bacteria and mold fungi were used in the hope of finding a method of cultivation in symbiosis. A few experiments were even made with tissue cultures

which was done with the assistance of Dr. N. C. Foot. Successful tissue cultures were started from tissues excised from the testicle and epididymis of infected guinea-pigs. No organisms could be demonstrated in the tissue cultures, which were composed chiefly of connective tissue cells; nor was it possible to infect animals by injecting the whole of these cultures. Two series of cultivation experiments were carried through, using relatively simple media containing unheated protein, in which especial attention was paid to securing a wide range of reaction, in the hope that success might be achieved at a certain hydrogen-iron concentration.

In all of the above experiments the dark field illuminating apparatus was used in studying the cultures. From time to time guinea-pig inoculations were made, even though the morphological evidence was negative. Occasionally bacteria were encountered, which when injected, caused a fatal peritonitis or a septicæmia. The most striking instance of this sort was the recovery of a small streptococcus which was fatal for guinea-pigs in about six days after inoculation. This streptococcus grew best under anaërobic conditions, and caused a course of temperature somewhat similar to that produced by spotted fever.

As success in the cultivation of pathogenic microörganisms may depend on very slight variations in the constitution of culture media — acidity and oxygen supply — the publication of negative results does not seem advisable, as it might tend to discourage repetition, whereas repeated efforts may result in the accidental or intentional introduction of the necessary factors. On the other hand, the problem may be as impossible of solution as the cultivation of the bacillus of leprosy has proved to be.

XIII. EXPERIMENTS TO PROVE THE SPECIFICITY OF THE PARASITE.

Since the proof of the causal relationship of the microörganism which I have described is largely dependent upon its constant occurrence and inseparability from ticks capable

of transmitting the disease, the results have been tabulated together with the control experiments under the following headings:

(1) Adult ticks proved to be infective.

(2) Ticks infected as nymphs, some of which were proved to be infective in the adult stage.

(3) Control ticks, nymphs, first series and second series.

(4) Adult control ticks proved non-infective.

(5) Adult control ticks not tested.

In every instance of adult ticks proved to be infective, the parasites were found. They were found in no instance in proved non-infective ticks, either in adults or nymphs. In infected nymphs they were found in every instance where the examinations were made later than six days after dropping, with one exception — Tick LXXXIV. — which was not thoroughly examined.

In the examination of adult control ticks which were not tested, some of which were obtained by dragging in the unfed state, and others in various degrees of engorgement collected from cattle, bacteria were found in a fair number. Unfed adult ticks in the spring months will collect upon cloth dragged over vegetation, as moving objects represent possible hosts. In only one instance were microörganisms found which could be confused with the spotted fever parasite. This was in Tick XI., Table V., which came from an unengorged male, one of a series collected from cattle. It is possible that this was a naturally infected tick. On the other hand, the distribution of the organisms was limited to the epithelial cells of the intestinal tract, while I have invariably found the organisms much more widely distributed in proved infected ticks.

In addition to the ticks recorded in table form, twenty adult ticks fed once upon infected guinea-pigs, but not tested after their infectivity, were examined for the parasites. They were found in eleven of these twenty ticks, which in view of the fact of the frequent failure to infect ticks by one or even two feedings, is about what one would expect. In one tick, which failed to produce the disease after each of two feedings and which was fed a third time on an infected guinea-pig,

the parasites were found. The infectivity of this tick could not be tested, as it became fully engorged during the last feeding.

The conclusion to be drawn from these examinations of infected and control ticks is that the microörganism under consideration is constantly present in and inseparable from ticks containing the virus of Rocky Mountain spotted fever.

(1) Adult ticks proved to be infective. — Tick X., *D. venustus*, unfed. Fed June 20 to June 22, 1916, on Strain II. Guinea Pig 34, again on June 27 to 29, 1916, on Strain II. Guinea Pig 35. (See Chart 2.)

Record of Strain II. Guinea Pig 34, inoculated June 15, 1916, from No. 31 of this series:

Temperatures: June 13, 102; June 14, 103; June 15, 102.5; June 16, 17, 18, 19, 104.6; June 20, 106, ticks attached; June 21, 104; June 22, 95, ticks removed.

Killed June 22, 1916. Autopsy showed typical lesions of spotted fever.

Record of Strain II. Guinea Pig 35, inoculated June 21, 1916, from No. 33 of this series:

Temperatures: June 21, 22, 103.6; June 23, 103; June 24, 25, 26, 105.6; June 27, 106, ticks attached; June 28, 105.6; June 29, dead, ticks removed.

An autopsy showed typical lesions of spotted fever.

This tick was fed July 15 to 18, 1916, on a normal guinea-pig labeled Tick X. guinea-pig, to test its infectivity.

Record of Tick X. Guinea Pig. — Temperatures after removal of Tick X.: July 18, 101.2; July 19, 101.8; July 20, 102.6; July 21, 105; July 22, 105.8; July 23, 24, 105.8, killed.

At autopsy the lesions were typical of spotted fever, and from this guinea-pig the strain was maintained for sixteen generations. (See Chart 2.)

Result: Tick X. proved to have transmitted the virus of Rocky Mountain spotted fever.

July 24, 1916, dissected and tissues preserved for serial section. The organisms were found in the sections in the salivary glands and duct walls, gut walls, Malpighian tubes, ganglion and nerves and musculature.

Tick XI., *D. venustus*, unfed. Fed June 20 to 22, 1916, and again on June 27 to 29, 1916, on Strain II. Guinea Pigs 34 and 35, together with Tick X. (See Chart 2.)

This tick was fed July 15to 18, 1916, on a normal guinea-pig, labeled Tick XI. Guinea Pig, to test its infectivity. The result was negative as shown by the temperatures after removal of the tick.

Temperatures: July 18, 101.5; July 19, 102; July 20, 101.8; July 22, 102; July 24, 101.8; July 25, 101; July 26, 101.9; July 27, 101.6; July 28, 101.6; July 29, 102.

This Tick XI. Guinea Pig proved susceptible to inoculation from Tick X. Guinea Pig 3, from which it was inoculated July 29, and it was recorded as Tick X. Guinea Pig 5.

Temperatures: July 29, 102; July 20, 102; July 31, 104.8; August 1, 105; August 2, 104.2; August 3, 106; August 4, 106.2; August 5, 104.8, killed.

The autopsy showed typical lesions of spotted fever, and from this pig Tick X. Guinea Pigs 7 and 8 were inoculated in perpetuating the strain. (See Chart 2.)

Third feeding of Tick XI. on an infected guinea-pig. July 28, 1916, to July 30, 1916, this tick was fed with three other ticks upon Tick X. Guinea Pig 2. (See Chart 2.)

Record of Tick X. Guinea Pig 2, inoculated July 24, 1916, from original Tick X. Guinea Pig.

Temperatures: July 24, 102.2; July 25, 100.6; July 26, 102.4; July 27, 104.6; July 28, 105, ticks attached; July 29, 30, 31, dead, ticks removed.

At autopsy the lesions were typical of spotted fever.

Second feeding on a normal guinea-pig, August 2 to 7, 1916. This Tick XI. was fed August 2 to 7, 1916, for the second time on a normal guinea-pig, recorded as Tick XI. guinea-pig of August 2.

Record of Tick XI. guinea-pig of August 2, after removal of Tick XI.

Temperatures: August 7, 106; August 8, 106.4; August 9, 106; August 10, 106; August 11, 105.8, scrotum swollen and red, eyelids and paws are swollen, the scrotum is swollen and black; August 12, 103.6; August 13, dead.

At autopsy the lesions were typical of spotted fever.

Result: Tick XI. proved to have transmitted the virus of Rocky Mountain spotted fever.

Tick XI. dissected August 12, 1916. Smear and dark field preparations were made from one side and the remainder preserved for serial sections.

The organisms were found by all methods in salivary glands, musculature and Malpighian tubes. In serial sections they were found in all organs and also in spermatozoa. (Figs. 28, 37 and 43.)

Tick XIII., *D. venustus*, unfed ♀. Fed July 13 to 15, 1916, on Strain I. Guinea Pig 162.

Record of Guinea Pig 162; inoculated July 7 from No. 159:

Temperatures: July 8, 103; July 11, 104.2; July 12, 104.5, ticks attached; July 14, 101; July 15, dead, discarded.

This Tick XIII. was fed on a normal guinea-pig, recorded as Tick XIII Guinea Pig, July 18 to 20, 1916. Result negative.

Record of guinea-pig after removal of tick: July 20, 101.3; July 21, 99; July 22, 101; July 24, 101.2; July 25, 101.8; July 26, 101.2; July 27 101.4; July 28, 100.6; July 29, 101; July 30, 102; July 31, 102.4; August 1, 102.4; August 2, 101.6.

This guinea-pig was inoculated August 2 from Strain I. Guinea Pig 176 and was recorded as No. 179, and proved susceptible. It was used to infect other ticks. At death, August 11, 1916, presented typical lesions of spotted fever.

Second feeding of Tick XIII. on an infected guinea-pig. July 28 to July 30, 1916, fed on Tick X. Guinea Pig 2, together with Tick XI. (See above.)

Second feeding of Tick XIII. on a normal guinea-pig. Fed August 2 to 7, 1916, on a normal guinea-pig, during which time it became fully engorged

Record of Tick XIII. Guinea Pig of August 2: Temperatures after removal of tick: August 7, 104.4; August 8, 105.2; August 9, 106.4; August 10, 105.8; August 11, 105.6; August 12, 105.8; August 13, 14, 105; August 15, 104; August 16, 104; August 17, 103; August 18, 102.6, killed.

At autopsy the lesions were typical of spotted fever, with necrosis of paws and swelling of eyelids and paws. The tissues studied microscopically showed the histological lesions and the microörganisms in the blood vessels which are characteristic of spotted fever.

Result: Tick XIII. proved to have transmitted the virus of Rocky Mountain spotted fever.

Dark field preparations showed the organisms in the leg muscles. Serial sections showed the organisms in all tissues. In smears they were found in salivary gland, muscle and Malpighian tubes. (Figs. 33 and 36.)

Tick XIV., *D. venustus*, unfed ♀. Fed July 12 to 15, 1916, on Strain II. Guinea Pig 39.

Record of Strain II. Guinea Pig 39. Inoculated July 7 from Guinea Pig 37 of this series. (See Chart 2.)

Temperatures: July 8, 103; July 11, 104; July 12, 104.2, ticks attached; July 13, 104.3; July 14, 105.6, scrotum swollen and red; July 15, 106, killed for inoculations, ticks removed.

Guinea Pigs 40 and 41 inoculated from this guinea-pig ran typical courses of the disease (see Chart 2.), and from them the strain was continued.

This Tick XIV. was fed on a normal guinea-pig recorded as Tick XIV. Guinea Pig, July 18 to 20, 1916, with negative result.

Record of Tick XIV. Guinea Pig. Temperatures after removal of tick: July 20, 102.3; July 21, 102.4; July 22, 102.6; July 23, 24, 102; July 25, 102.2; July 26, 101.2; July 27, 102.2; July 28, 101.8; July 29, 102.2; July 30, 102.4; July 31, 102.6; August 1, 102.8; August 2, 102.8.

This guinea-pig was inoculated August 2, 1916, from Strain I. Guinea Pig 176, and recorded as No. 180. It proved susceptible.

Record of Guinea Pig 180. Temperatures: August 2, 102.8; August 3, 103.2; August 4, 102.6; August 5, 103.6; August 7, 105; August 8, 105.6, scrotum swollen.

Killed August 8. Autopsy showed typical lesions of spotted fever, and Guinea Pigs 181, 182 and 183 inoculated from it developed the disease. (See Chart 1.)

Second feeding of Tick XIV. on an infected guinea-pig. July 28 to 30, 1916, fed on Tick X. Guinea Pig 2, together with Ticks XI. and XIII. (See above.)

Second feeding of Tick XIV. on a normal guinea-pig. Fed August 2 to August 7, 1916, on a normal guinea-pig, on which it became fully engorged.

Record of Tick XIV. Guinea Pig of August 2. Temperatures after removal of tick: August 7, 102.2; August 8, 103; August 9, 104; August 10, 106; August 11, 106.1; August 12, 105.8, scrotum swollen and red. August 13, 14, 105.2; August 15, 105.2; August 16, 103.8; August 17, 102.8; August 18, 103, scrotum normal; induration at site of bite; August 19, 102.8; August 24, 102.8; August 25, 102.8; August 26, 103; August 27, 102; August 30, 102; September 1, 102.

This guinea-pig was inoculated February 17, 1917, from Tick XXVII. Guinea Pig, Darby strain, and proved to be immune.

Result: Tick XIV. proved to have transmitted the virus of Rocky Mountain spotted fever.

Tick XIV. dissected August 22, 1916.

The organisms were found in smears in preparations of the gut, salivary gland, Malpighian tubes and leg muscles. In serial sections they were found in all tissues. (Figs. 38, 40, 41 and 42.)

Tick XIX., *D. venustus*, unfed ♂. Fed on Strain I. Guinea Pig 154, June 26 to 29, 1916. Inoculated June 21 from No. 150.

Temperatures of Guinea Pig 154: June 22, 103; June 23, 103.1; June 26, 107, scrotum swollen and red, ticks attached; June 28, 106; June 29, killed, ticks removed.

Blood from this guinea-pig was used to inoculate No. 158 which ran a typical course and was used to continue the strain. July 20 to 24, 1916, this Tick XIX. was fed on a normal guinea-pig which was recorded as Tick XIX. Guinea-Pig. The tick fed well and passed considerable feces during the four days.

Record of Tick XIX. guinea-pig after removal of the tick: July 24, 101.8; July 25, 103.4; July 26, 102.7; July 27, 103.8; July 28, 105.8; July 29, 105.4, scrotum swollen and red; July 30, 105.2; July 31, 105.2; August 1, 104.4; August 2, 103.8; August 3, 103, scrotum necrotic, ears swollen and red, paws swollen and red; August 4, 102.6; August 5, 102; August 6, 102; August 8, 102, edges of ears are dry, necrotic; August 9, 102; August 10, 102; August 11, 102.5; August 12, 102.4; August 13, 14, 102.4.

Result: Tick XIX. proved to have transmitted the virus of Rocky Mountain spotted fever. Tick XIX. dissected July 28, 1916. Examined by serial sections.

The organisms were found in all tissues in small numbers, abundantly in the salivary glands, œsophagus, ganglion and gut.

Tick XXI., *D. venustus*, unfed ♂. Fed June 28 to July 1, 1916, on Strain I. Guinea Pig 156.

Temperatures: June 22, 101.8; June 26, 103.1; June 28, 105.4, ticks attached.

This tick was well filled as the result of this feeding.

July 20 to 24, 1916, this Tick XXI. was fed on a normal guinea-pig which was recorded as Tick XXI. Guinea Pig. The tick became well filled and passed much feces.

Record of Tick XXI. Guinea Pig after removal of tick: July 24, 102.4; July 25, 104.6; July 26, 106.2; July 27, 105; July 28, 106.4; July 29, 105.8; July 30, 104.8. July 31 was found dead.

The autopsy showed typical lesions of spotted fever.

Result: Tick XXI. proved to have transmitted the virus of Rocky Mountain spotted fever. Tick XXI. dissected July 28.

The organisms were found in serial sections in salivary glands, muscles of sucking organ and brain and nerve trunks. (Figs. 31 and 39.)

Tick XXVI., *D. venustus*, ♀. From L. D. Fricks. Fed in nymphal stage in summer of 1915 on a guinea-pig inoculated from a human case of Rocky Mountain spotted fever. "Darby" strain series. (See Chart 3.) Attached to a normal guinea-pig, recorded as Tick XXVI. Guinea Pig, December 27, 1916, to January 3, 1917.

Record of guinea-pig, Tick XXVI. December 27, tick attached in capsule; December 28, tick not feeding; December 29, tick has attached;

December 30, 31, tick has passed feces. Temperatures: January 1, 104; January 2, 104.2; January 3, 105, tick removed; January 4, 106, killed for inoculation.

Autopsy showed typical lesions of spotted fever. Two other guinea-pigs, Nos. 2 and 3, were inoculated with blood from this one, and ran typical courses and at autopsy showed lesions typical of spotted fever.

Record of Tick XXVI. Guinea Pig 2, inoculated January 4, 1917. Temperatures: January 5, 102.2; January 6, 101.6; January 8, 105; January 9, 105; January 10, 104; January 11, 101, killed.

Autopsy showed typical lesions of spotted fever.

Record of Tick XXVI. Guinea Pig 3, inoculated January 4, 1917. Temperatures: January 5, 102; January 6, 102; January 8, 105; January 9, 105; January 10, 104; January 11, 103.4, killed.

Autopsy showed typical lesions of spotted fever.

Result: Tick XXVI. proved to have transmitted the virus of Rocky Mountain spotted fever. Tick XXVI. dissected January 12, 1917.

Organisms were found in the smear preparations of the salivary gland, Malpighian tubes, gut and leg muscles. In serial sections they were found in the brain and salivary gland. (These sections were poorly stained.)

Tick XXVIII., *D. venustus*, ♀. Same source as Tick XXVI. Attached to a normal guinea-pig, recorded as Tick XXVIII. Guinea Pig, December 27, 1916, to January 3, 1917.

Record of Tick XXVIII. Guinea Pig. December 27, tick attached in capsule; December 28, tick not feeding; December 29, tick not feeding; December 30, 31, tick feeding, has passed feces; January 1, temperature of guinea-pig, 100.8; January 2, temperature of guinea-pig, 102; January 3, temperature of guinea-pig, 103.4, tick removed; January 4, temperature of guinea-pig, 104.4; January 5, temperature of guinea-pig, 106; January 6, temperature of guinea-pig, 105.6, killed.

Autopsy showed typical lesions of spotted fever, and inoculation of the heart's blood reproduced the disease in two other guinea-pigs from which a third series of guinea-pigs were infected; each animal reacted characteristically and showed typical lesions.

Result: Tick XXVIII. proved to have transmitted the virus of Rocky Mountain spotted fever. Tick XXVIII. dissected January 23, 1917.

The organisms were found in smear preparations of salivary glands, Malpighian tubes, gut wall and muscles.

Tick XXXIII. and Tick XXXIV. Two unfed *D. venustus* ♀s. Fed with others May 22 to May 24, 1917, on one

of two guinea-pigs inoculated with one cubic centimeter of blood May 18, 1917, from a human case of spotted fever at Hamilton, Mont. (Case III., John Lake.)

Temperatures of Case III. guinea-pig: May 18, inoculated; May 19· 103.2; May 21, 101; May 22, 105, ticks attached; May 23, 104.9; May 24, 105, scrotum swollen and red, ticks removed; May 25, killed.

This guinea-pig was not autopsied. The companion inoculated at the same time ran a similar course of temperatures and at autopsy, May 25, showed typical lesions of spotted fever.

These two ticks were attached in a capsule on June 2, 1917, to a normal guinea-pig, recorded as Case III. Guinea Pig 3. Removed June 11, 1917.

Record of Case III. Guinea Pig 3. — Temperatures: June 2, ticks attached; June 4, 102, one tick feeding; June 5, 103, both ticks feeding; June 6, 102.2; June 8, 101.8; June 9, 101.2; June 11, 101.6, ticks removed; June 12, 102.4; June 13, 101.6; June 14, 102; June 15, 103.4; June 16, 104; June 18, 104.6; June 19, 105; June 20, 105; June 21, 103; June 22, dead.

Autopsy showed typical lesions of spotted fever.

Result: One or both of Ticks XXXIII. and XXXIV. proved to have transmitted the virus of Rocky Mountain spotted fever.

Ticks XXXIII. and XXXIV. dissected June 29, 1917.

Both ticks showed the organisms in marked abundance in all tissues in serial sections and in the smear preparations of salivary glands, gut, Malpighian tubes and muscles. (Fig. 30.)

Summary: Ten proved infective adult ticks contained the parasites of Rocky Mountain spotted fever.

(2) Ticks infected as nymphs, some of which were proved to be infective in the adult stage. — The "flat," i.e., unfed, nymphs used in this series of examinations for the presence of the spotted fever organisms were received from W. V. King in June, 1917. These nymphs were raised by Dr. King from eggs and reached the nymphal stage in July, 1916. Seven which fed on a normal guinea-pig (see first control series, Table II.) did not infect. On July 2, 1917, 200 were placed in a jar with Guinea Pig 19, Hayes strain. On July 3, 127 more nymphs were added, making a total of 327. On July 5, the guinea-pig with the feeding nymphs was transferred to a

new jar and the first one sterilized. On July 9 many fully engorged nymphs had dropped, and on July 11, 140 fully engorged nymphs were collected from the jar. The majority of these nymphs molted during the first week in August, and the adults reserved for future experiments were placed in a cold room, in a slightly moistened atmosphere, temperature 7° C. to 10° C.

The temperatures of this guinea-pig were not taken because of the danger of losing some of the nymphs. It was killed July 11, 1917, and showed the typical lesions of spotted fever. The inguinal lymph nodes were enlarged and red. The spleen was treble normal size, deep red in color; the capsule was covered with a thin, translucent fibrinous layer. The testes were adherent to the tunica, with hemorrhages into the polar fat. The cremasteric muscles were dry, dark-red in color and adherent. The skin of the scrotum was necrotic and the subcutaneous tissues of the scrotum were œdematous and dark-red in color. The other tissues of the guinea-pig were negative.

Experiments to prove the infectivity of the ticks fed as nymphs on Hayes Strain Guinea Pig 19.—I. August 27, 1917, placed three female and three male ticks of this series in a wire gauze capsule upon a normal guinea-pig subsequently recorded as Hayes Strain Guinea Pig 44. (See Chart 4.)

Record of Hayes Strain Guinea Pig 44. August 27, ticks attached; August 28, 101, none feeding; August 29, 100, all ticks feeding. Temperatures: August 30, 100; August 31, 101.6; September 1, 102.7; September 3, 105.6; September 4, 106, removed ticks; all have fed moderately; September 5, 105.4, killed guinea-pig for inoculations.

Autopsy showed the typical lesions of spotted fever, and from this guinea-pig the strain was maintained. (See Chart 4, page 59.)

Result: Six ticks fed as nymphs on Hayes Strain Guinea Pig 19 proved to have transmitted the virus of Rocky Mountain spotted fever.

II. August 23, 1918. Placed two female and two male ticks of this series in a wire gauze capsule upon a normal

guinea-pig, subsequently recorded as Hayes Tick Guinea Pig of August, 1918.

Record of Hayes Tick Guinea Pig of August, 1918. Temperatures: August 23, 102.4, ticks attached; August 24, 101.6, three ticks feeding; August 25, 101.1, two ticks are feeding; August 26, 101.6, all ticks are feeding; some have passed feces; August 27, 100; August 28, 104; August 29, 102.6, removed ticks; all have fed moderately; August 30, 105.3, inoculated Guinea Pigs 1 and 2 with blood taken by heart puncture; August 31, 106.6, killed.

The autopsy showed the typical lesions of spotted fever, and Guinea Pigs 3 and 4 inoculated with the heart's blood were used to maintain the strain. (See Chart 5, page 60.) On Guinea Pig 13 of this series other ticks reared from eggs of a tick (Tick A) were infected and Hayes Tick "A" strain established. (See Chart 5, page 60.)

Result: Four ticks fed as nymphs on Hayes Strain Guinea Pig 19 proved to have transmitted the virus of Rocky Mountain spotted fever.

III. On August 5, 1918, placed five female ticks of this series in a wire gauze capsule upon a normal rabbit (white and black), subsequently recorded as Hayes Tick Rabbit 1.

Record of Hayes Tick Rabbit 1. Temperatures: August 5, 102.2, attached ticks; August 6, 102.2, all ticks are feeding; August 7, 103, feces in capsule; August 8, 102.4; August 9, 103.4; August 10, 105.7, removed ticks; all have fed well (average size 5 x 6 x 2 mm.); August 11, 105.4, scrotum injected and slightly swollen; August 13, 105.2; August 14, 105.4; August 15, 104.2, killed.

The autopsy showed enlarged and pink inguinal lymph nodes, the spleen deep red in color and moderately enlarged, and the testes injected. All other tissues were negative. Microscopic examination of the tissues showed the typical vascular lesions of spotted fever in the testes and skin of the scrotum, and the parasites were found in these lesions.

Result: Five ticks fed as nymphs on Hayes Guinea Pig 19 proved to have transmitted the virus of Rocky Mountain spotted fever.

IV. December 19, 1918, placed two female ticks of this series, which had also fed on Hayes Tick Rabbit 1, on a normal guinea-pig which was recorded as Hayes Tick Guinea Pig of December, 1918.

Record of Hayes Tick Guinea Pig of December, 1918. Temperatures: December 19, ticks attached; December 20, 103.8; December 23, 101.6; December 24, 102.6, removed ticks which had fed sufficiently to fill out

TABLE I.

Nymphs fed on Hayes Strain Guinea Pig 19.

No. of Tick.	Date Dissected, Time after Dropping, Temperature Conditions.	Result of Smear Preparations.	Result of Serial Sections.
XLI.	July 12, 1 day at room temperature.	Gut – Muscle – Salivary gland – Malpighian tubes –	No sections.
XLII.	July 13, 1 day at 37.5° C.; 1 day at room temperature.	Gut – Muscle – Salivary gland – Malpighian tubes –	No sections.
XLIII.	July 14, 1 day at room temperature; 2 days at 37.5° C.	Gut – Salivary gland – Malpighian tubes –	All tissues negative.
XLIV.	July 14, as above.	Gut –	No sections.
XLVI.	July 16, 1 day at room temperature; 4 days at 37.5° C.	Gut +, larger pale-blue rod forms in small numbers. Malpighian tubes –	Gut +. Intracellular and intranuclear forms in gut and rectal sac. Brain – Muscle – Malpighian tubes – Hypoderm and developing organs – The salivary glands are absent at this stage.
XLVII.	July 17, 6 days at room temperature.	Gut – Malpighian tubes –	No sections.

XLVIII.	July 17, 1 day at room temperature; 5 days at 37.5° C.	Gut+, many rods in one of two slides; some with chromatoid dots. (Figs. 20 and 34.) One slide— Malpighian tubes—	Gut+, free and intracellular forms. Rectal sac+, intranuclear and intracellular forms. Blood cells+, a few. Brain+, a few. Œsophagus+, a few. Muscle— Hypoderm and new organs— Malpighian tubes—
XLIX.	July 17, as above.	Gut+, one of two slides only. Malpighian tubes—	No sections.
L.	July 18, 1 day at room temperature; 6 days at 37.5° C.	Gut+, in abundance, many with chromatoid dots. Malpighian tubes+, many with chromatoid dots.	Gut+, free and intracellular. Rectal sac+, free and intracellular and intranuclear. Brain+, in abundance. Œsophagus+, in abundance. Blood cells+ Salivary glands+ Uterus+ Muscle— Malpighian tubes— Hypoderm—
LI.	July 18, as above.	Gut+, a few pale-blue rod forms. Malpighian tubes—	No sections.
LII.	July 18, as above.	As above.	No sections.
LIII..	July 18, 6 days at room temperature; 1 day at 37.5° C.	Gut+, many paired rod forms and occasional short chains. Malpighian tubes—	No sections.

TABLE I. — *Continued.*

Nymphs fed on Hayes Strain Guinea Pig 19.

No. of Tick.	Date Dissected, Time after Dropping, Temperature Conditions.	Result of Smear Preparations.	Result of Serial Sections.
LIV.	July 18, as above.	Gut +, in small numbers.	No sections.
LV.	July 19, 6 days at room temperature; 2 days at 37.5° C.	Gut +, in fair numbers, rod forms. Malpighian tubes −	All tissues +, including salivary glands, developing sex (♀) organs and hypoderm. Intranuclear forms in rectal sac, developing leg muscles, hypoderm.
LVI.	July 19, as above.	Gut +, in abundance.	No sections.
LVII.	July 19, 1 day at room temperature; 7 days at 37.5° C.	Gut +, in abundance with intracellular masses. Rods with chromatoid dots. Malpighian tubes +	No sections.
LVIII.	July 19, as above.	Gut +, as above.	No sections.
LIX.	July 20, 1 day at room temperature; 8 days at 37.5° C.	Gut +, in great abundance; rods with chromatoid dots. Malpighian tube −	Gut +, in abundance. Rectal sac +, intranuclear forms. Œsophagus +, intranuclear forms. New organs − Brain − (fair stain only).
LX.	July 20, as above.	Gut +, in great abundance; rods with chromatoid dots.	No sections.

LXI.	July 20, 6 days at room temperature; 3 days at 37.5° C.	Gut+, large pale rods and rods with chromatoid dots. Malpighian tube−	No sections.
LXII.	July 20, as above.	Gut+, in great abundance; rods with chromatoid dots predominating.	No sections.
LXIII.	July 21, 6 days at room temperature; 4 days at 37.5° C.	Gut+, in abundance; rods with chromatoid dots.	Gut+ Poor stain.
LXIV., ♀	July 21, 1 day at room temperature; 9 days at 37.5° C.	Gut+, in abundance, as above. Malpighian tube−, a poor preparation.	Gut+ Poor stain.
LXV.	July 21, 10 days at room temperature.	Gut+, pale-blue rods and rods with chromatoid dots in numbers.	No sections.
LXVII., ♂ . . .	July 23, 6 days at room temperature; 6 days at 37.5° C.	Gut+, in great abundance; rods with chromatoid dots.	All tissues+, including blood cells and new organs. Intranuclear forms in: Muscle. Rectal sac. Malpighian tubes. Hypoderm.
LXVIII.	July 23, as above.	Gut+, as above.	All tissues+, as above. Intranuclear forms, as above.
LXIX.	July 23, 1 day at room temperature; 11 days at 37.5° C.	Gut+, in great abundance; rods with chromatoid dots. (Fig. 21.) Malpighian tubes+, rods with chromatoid dots.	No sections.

TABLE I. — *Continued.*

Nymphs fed on Hayes Strain Guinea Pig 19.

No. of Tick.	Date Dissected, Time after Dropping, Temperature Conditions.	Result of Smear Preparations.	Result of Serial Sections.
LXX.	July 23, 12 days at room temperature.	Gut+, in abundance; rods with chromatoid dots.	No sections.
LXXV., Imago .	July 26, 1 day at room temperature; 14 days at 37.5° C.	Gut+, in great abundance; rods with chromatoid dots.	No sections.
LXXVI., ♂, Imago	July 26, 13 days at room temperature; 2 days at 37.5° C.	Gut+, in great abundance; rods with chromatoid dots. Malpighian tubes+	All tissues+, including new organs. Intranuclear forms in: Rectal sac and muscle. (Short search only.)
LXXVII., ♀, Imago	July 26, 6 days at room temperature; 9 days at 37.5° C.	Gut+, as above.	All tissues+ Intranuclear forms in salivary glands and ducts.
LXXVIII. . . .	July 26, 15 days at room temperature.	Gut+, in abundance, pale-blue rods and rods with chromatoid dots.	No sections.
LXXIX., ♀ . .	July 27, 15 days at room temperature; 1 day in ice chest.	Gut+, in great abundance; rods with chromatoid dots.	All tissues+ Intranuclear forms in: Salivary glands. Malpighian tubes. Rectal sac.
LXXX.	July 27, as above.	Gut+, as above.	No sections.

LXXXI., ♂ . .	July 27, 16 days at room temperature.	Gut +, as above. (Figs. 22 and 35.) Malpighian tube +	All tissues + Intranuclear forms in rectal sac. (Poor sections.) (Figs. 27 and 32.)
LXXXII. . . .	July 27, as above.	Gut +, in abundance; lanceolate forms and rods with chromatoid dots.	No sections.
LXXXIII. . . .	July 27, 13 days at room temperature; 3 days at 37.5° C.	Gut +, in great abundance; rods with chromatoid dots. Malpighian tubes −	No sections.
LXXXIV. . . .	July 27, as above.	Gut − Malpighian tube −	No sections.
LXXXVI. . . .	July 28, 13 days at room temperature; 4 days at 37.5° C.	Gut +, in abundance. Malpighian tube − (Poor stain.)	No sections.
LXXXVIII., ♀, Imago	July 30, 13 days at room temperature; 6 days at 37.5° C.	Gut +, in great abundance; rods with chromatoid dots. Malpighian tube +	No sections.
XC., ♀, Imago .	August 2, 22 days at room temperature.	Gut +, in fair numbers, lanceolate forms and rods with chromatoid dots.	All tissues + Intranuclear forms in rectal sac.
XCI., ♀, Imago .	August 2, as above.	Gut +, in abundance; lanceolate forms and rods with chromatoid dots. Brain +, lanceolate forms. Salivary glands +, lanceolate forms. Malpighian tubes +, lanceolate forms.	All tissues +, in great abundance.

TABLE I. — *Concluded.*

Nymphs fed on Hayes Strain Guinea Pig 19.

No. of Tick.	Date Dissected, Time after Dropping, Temperature Conditions.	Result of Smear Preparations.	Result of Serial Sections.
XCIX., ♀ . . .	August 10, 30 days at room temperature.	Gut +, lanceolate forms chiefly in fair numbers. Salivary glands + Malpighian tubes +	Poor sections, some incomplete. Salivary glands +
CXXXV., ♀, Imago used to infect Hayes Guinea Pig 44.	September 4, 47 days at room temperature; 7 days feeding on Hayes Guinea Pig 44.	Gut +, small numbers. Malpighian tube +, many paired rods. Salivary glands −	All tissues +, in small numbers.
CXXXVI., as above.	September 4, as above.	Gut +, as above. Malpighian tube − Salivary gland −	All tissues + Intranuclear forms in rectal sac.

the wrinkles and pass feces; December 26, 103.6; December 27, 105.2; December 28, 106.4, killed.

The autopsy showed typical lesions of spotted fever and from this guinea-pig the strain was maintained for eleven generations. (See Chart 5, page 60.)

Result: Two ticks fed as nymphs on Hayes Strain Guinea Pig 19 and again upon a normal rabbit were proved to have transmitted the virus of Rocky Mountain spotted fever.

Summary of conditions affecting the preceding Table I. — Seven nymphs from the same source fed on a normal guinea-pig did not infect. (See first control series, Table II.) Of ticks raised from one hundred and forty nymphs fed on Hayes Guinea Pig 19, three separate lots of six, four and five respectively transmitted the virus of Rocky Mountain spotted fever, and in a fourth experiment two ticks of the five used to infect a rabbit also infected a guinea-pig. It seems reasonable to conclude that the majority or all of the ticks fed as nymphs on Hayes Guinea Pig 19 contained the virus of Rocky Mountain spotted fever.

Summary of results in Table I. — Forty-five nymphs fed on Hayes strain Guinea Pig 19 were dissected and examined for the parasite of Rocky Mountain spotted fever during a period of forty-seven days extending from the first day after dropping as fully engorged nymphs through and into the adult stage. The smear preparation technic was controlled by selecting at random ticks throughout the series for serial sectioning.

The parasites were found on and after the fifth day (note influence of temperature in chart) with but one exception (Tick LXXXVI.).

The first form to appear in smears of the gut is the relatively large pale-blue staining rod at which time the minute intranuclear forms may be found in sections of the rectal sac and intestines.

In the early stages of digestion in the nymph many confusing bodies are found, free and within cells of the intestinal tract. For a while, tiny red and blue stained bodies, one or two

microns in diameter, massed in epithelial cells of the intestine, were given consideration as possible parasitic forms, as their resemblance to *Theileria* was rather striking. However, these forms in later stages of digestion lost their red and blue staining and many became pigmented greenish. A study of the control nymphs showed the presence of these bodies in equal abundance, thereby absolutely disproving relationship to the parasite of Rocky Mountain spotted fever. As digestion in the tick is wholly intracellular, the most plausible explanation of these bodies, and one supported by considerable morphological evidence, is that they are derived from the nuclei of ingested white blood corpuscles.

With the appearance in the intestine of the minute rods with chromatoid granules, the large forms diminish in numbers and finally disappear (eight to fifteen days, according to temperature). Still later the densely staining lanceolate forms appear in the intestines; from about the sixteenth day on. The period of greatest abundance of the minute rods with chromatoid granules in smears of the intestinal tract corresponds with the greatest abundance of intranuclear forms in sections. Lanceolate forms, however, can be found in sections in most organs immediately after the intranuclear forms make their appearance.

Since the lanceolate is the only form that can be demonstrated in the blood of infected mammals, it is probably the one introduced into the tick. From this densely staining lanceolate form must come the pale-blue staining rods which are the first indication of multiplication of a specific parasite in infective ticks. The period of greatest abundance of the parasite in the tick is that coincident with the greatest intranuclear development, and the minute rods with chromatoid dots. The lanceolate form is a late arrival in the tick, and represents the completion of a fairly definite morphological cycle, and as the lanceolate form only can be demonstrated in the salivary gland cells and ducts of both types of salivary gland acini in the tick, it is reasonable to suppose that the parasite is reintroduced into mammals in this form.

Confirmatory evidence of this last theory is the fact that the lanceolate paired forms were found in large numbers in mononuclear phagocytic cells (endothelial cells) in sections through a tick bite made in infecting Hayes Strain Guinea Pig 3.

(3) Control ticks. Nymphs proved non-infective. First series. — These nymphs were raised by Dr. W. V. King from eggs in July, 1916, in Victor, Mont. They were fed on a normal male Guinea Pig 6, August 4 to 13, 1917, when seven fully engorged nymphs were recovered, which had dropped from the guinea-pig.

Temperatures of normal Guinea Pig 6 after removal of the nymphs: August 13, 102.4; August 14, 102.5; August 15, 102; August 16, 101.4; August 17, 101; August 18, 102; August 19, 20, 101; August 21, 100; August 22, 101; August 23, 102.4; August 24, 101.6; August 25, 101.

This guinea-pig was not tested for susceptibility, as it died on August 27, together with several others, from the effects of an exclusive cabbage diet.

TABLE II.

No. of Tick.	Date Dissected, Time after Dropping, Temperature Conditions.	Smears of Gut and Malpighian Tubes.	Serial Sections, All Tissues.
CIV. . . .	August 16, 3 days at 37.5° C. in incubator.	Negative.	
CVI. . . .	August 17, 4 days at 37.5° C.	Negative.	
CVII.. . .	August 20, 7 days at 37.5° C.	Negative.	Negative.
CVIII. . .	August 20, 7 days at 37.5° C.	Negative.	Negative.
CIX. . . .	August 22, 9 days at room temperature.	Negative.	Negative.
CXIV. . .	August 23, 9 days at room temperature; 1 day at 37.5° C.	Negative.	Negative.
CXIX. . .	August 27, 9 days at room temperature; 5 days at 37.5° C.	Negative.	

Summary. — None of this series of seven nymphs fed upon a normal guinea-pig and dissected over a period of fourteen days, contained microörganisms. The source of these nymphs

was the same as those fed upon Hayes Strain Guinea Pig 19 (Table I.).

(4) Control ticks. Nymphs proved non-infective. Second series. — These ticks were sent by W. V. King as engorged larvæ which dropped between July 26 and July 27, 1917. They molted in Boston between August 6 and August 13, 1917. The nymphs were fed August 13 to August 21, 1917, on normal female Guinea Pig 7. Seventy-six fully engorged nymphs were collected which had dropped from the guinea-pig.

Table III.

No. of Tick.	Date Dissected, Time after Dropping, Temperature Conditions.	Result: Smears of Gut and Malpighian Tubes.	Serial Sections, All Tissues.
CX. . . .	August 22, 1 day at 37.5° C.	Negative.	
CXIII. . .	August 23, 2 days at 37.5° C.	Negative.	Negative.
CXVI. . .	August 24, 3 days at 37.5° C.	Negative.	
CXVII. .	August 25, 4 days at 37.5° C.	Negative.	
CXX. . .	August 27, 6 days at 37.5° C.	Negative.	
CXXIII. .	August 28, 7 days at 37.5° C.	Negative.	Negative.
CXXV. .	August 29, 8 days at 37.5° C.	Negative.	Negative.
CXXVII. .	September 1, 11 days at 37.5° C. Male imago, almost mature.	Negative.	
CXXIX. .	September 1, 11 days at room temperature.	Negative.	Negative.
CXXX. .	September 1, 7 days at room temperature; 4 days at 37.5° C.	Negative.	Negative.
CXXXIII.	September 4, 14 days at room temperature.	Negative.	Negative.
CXXXIV.	September 4, female imago. 7 days at room temperature; 7 days at 37.5° C.	Negative.	Negative.

Temperatures of Guinea Pig 7 after removal of the ticks: August 28, 100; August 29, 100.8; August 30, 100.6; August 31, 102.6; September 1, 101.6; September 3, 102; September 4, 101.6; September 5, 101.4; September 6, 102; September 7, 101.2.

On September 7 this guinea-pig was inoculated from Guinea Pig 107, California strain.

Temperatures after inoculation: September 8, 102.2; September 9, 10, 102.6; September 11, 105; September 12, 106; September 13, 105.8; September 14, 105.

September 15, found dead. Autopsy showed lesions consistent in a female guinea-pig with spotted fever.

Summary. — None of this series of twelve nymphs, dissected over a period of fourteen days, contained microörganisms.

(5) Adult control ticks proved non-infective. — Tick III., ♀, *D. venustus*, from Prof. R. A. Cooley; fed June 23 to 26, 1916, on normal male Guinea Pig 1. Dissected July 3, 1916; examined by serial sections. Result negative.

Temperature of Guinea Pig 1, after removal of tick: June 26, 104; June 27, 102.8; June 28, 102.1; June 29, 101; June 30, 101.4; July 1, 102.2.

Killed July 1, 1916. No lesions found.

Tick V., ♀, *D. venustus*, from Prof. R. A. Cooley. Fed June 23 to 26, 1916, on normal male Guinea Pig 2. Dissected July 11, 1916. Examined by serial sections. Result negative.

Temperature of Guinea Pig 2, after removal of ticks: June 26, 103; June 27, 102.4; June 28, 101.8; June 29, 102; June 30, 102.1; July 1, 101.9.

On July 8, 1916, this guinea-pig was inoculated from Guinea Pig 158, Strain I., and was No. 165.

Temperatures: July 8, 102; July 9, 102.8; July 10, 11, 104; July 12, 104.6.

Killed July 12, 1916. Autopsy showed lesions typical of spotted fever.

Tick VIII., ♀, *D. venustus*, from Prof. R. A. Cooley. Fed June 23 to 26, 1916, on normal male Guinea Pig 2 (see above). Dissected July 10, 1916. Examined by smears. Result negative.

Tick XXII., ♀, *D. venustus*, partly engorged; from Prof. R. A. Cooley. Fed June 23 to 26, 1916, on normal male Guinea Pig 3. Dissected July 25, 1916. Examined by smears and serial sections. Result negative.

Temperature of Guinea Pig 3: June 26, 101; June 27, 102.4; June 28, 101.6; June 29, 102; June 30, 101.9; July 1, 101.8.

July 8, this guinea-pig was inoculated from Guinea Pig 158, Strain I., and proved susceptible. Record lost.

Tick XXIII., ♀, *D. venustus*, partly engorged; from Prof. R. A. Cooley. Fed July 13 to 17, 1916, on normal male Guinea Pig 4. Dissected August 3, 1916. Examined by smears and serial sections. Result negative.

Temperatures of Guinea Pig 4 after removal of ticks: July 18, 102.6; July 19, 102; July 20, 102.8; July 21, 100.6; July 22, 103; July 24, 102.1; July 25, 102.2; July 26, 102; July 27, 101.4.

July 27, this guinea-pig was inoculated from Guinea Pig 42, Strain II., and numbered 44.

Temperatures: July 28, 101.4; July 29, 102; July 30, 102.6; July 31, 106; August 1, 105.4; August 2, 105; August 3, 106.

Killed. Autopsy showed typical lesions of spotted fever, and inoculations of heart's blood into Guinea Pigs 46 and 47, Strain II., reproduced the disease in both in typical form.

Tick XXV., *D. venustus*, from Prof. R. A. Cooley. Fed June 23 to 26, 1916, on normal Guinea Pig 1 and again July 13 to 17, 1916, on normal male Guinea Pig 5. Dissected August 7, 1916. Examined by serial sections. Result negative.

Temperature of Guinea Pig 5 after removal of ticks: July 18, 102; July 19, 101.2; July 20, 102.9; July 21, 100.1; July 22, 102.1; July 23, 24, 101.6; July 25, 101.2; July 26, 101.4; July 27, 101.3.

July 27 inoculated from Guinea Pig 173, Strain I., and numbered 178.

Temperatures: July 27, 101.3; July 28, 103.2; July 29, 105.8; July 30, 105.8; July 31, 105.6; August 1, 105.2; August 2, 105.

Killed. Autopsy showed typical lesions of spotted fever.

Summary. — Six proved non-infective adult ticks contained no microörganisms similar to the parasite of Rocky Mountain spotted fever.

(6) Adult control ticks not tested (Table IV.). — Lot 773, unfed adult ticks collected April 19, 1917, by Dr. W. V. King by dragging along O'Brien Creek, a tributary of the Bitter Root River. These ticks were studied from sections only and were dissected in Montana during April and May, 1917. In the column of results the reason for mentioning the rectal sac — gut junction — is that this is the place where intranuclear forms of the parasites are most common in infected ticks.

TABLE IV.

No.	Description.	Result.
1	♂	Negative. All tissues, including rectal sac — gut junction.
2	♀	Negative, all tissues. Rectal sac not found.
3	♀	Negative, all tissues, including rectal sac — gut junction.
4	♀	Large, slender, purple-staining bacilli in all tissues except brain, salivary glands and Malpighian tubes. Most abundant in the ova. Negative for organisms the size of the spotted fever organism. Rectal sac — gut junction — negative.
5	♀	Small bacilli, slightly larger than the spotted fever organisms, are present in the ova and in the epithelial cells of the gut. All other tissues are negative, including rectal sac — gut junction.
6	♂	Negative, all tissues, including rectal sac.
7	♀	Negative, all tissues; rectal sac not found.
8	♂	Negative, all tissues, including rectal sac — gut junction.
9	♂	In gut contents are groups of minute bacilli, but slightly larger than the spotted fever organisms. All other tissues are negative, including rectal sac — gut junction.
10	♂	Large, slender bacilli, similar to those in Tick IV., are present in all tissues, including testes. No organisms of the size of the spotted fever organism found. The rectal sac — gut valve — was found.
11	♀	All tissues negative; rectal sac not found.

Lot 772, adult ticks in various stages of engorgement collected April 24, 1917, from cattle, by W. V. King, in O'Brien Creek, Mont. Dissected in Montana during April and May, 1917. (Table V.)

TABLE V.

No.	Description.	Result.
1	♀ about $\frac{2}{3}$ engorged.	All tissues negative. Rectal sac not found.
2	Unengorged tick. Sex organs not in sections.	A few large, purple-staining bacilli in gut. Brain, salivary gland, muscle and Malpighian tubes negative. No organisms of the size of the spotted fever organisms found. Rectal sac not found.

TABLE V.— *Continued.*

No.	Description.	Result.
3	♀ about ¼ engorged.	Negative, all tissues. Rectal sac not found.
4	♀ about ½ engorged.	Negative, all tissues, including rectal sac — gut junction.
5	♀ about ¼ engorged.	Negative, all tissues, including rectal sac—gut junction.
6	♀ almost fully engorged with ripe ova.	Negative, all tissues, rectal sac — gut junction — not found.
7	♀ apparently unfed.	Negative, all tissues, rectal sac — gut junction — not found.
8	♀ has fed slightly.	Negative, all tissues; rectal sac not found. In the hypoderm are medium-sized micrococci.
9	♂ unengorged.	Negative, all tissues, but rectal sac not found.
10	♂ unengorged.	Large and very minute bacilli in one diverticulum in an epithelial cell. The smaller bacilli are equal in size to the spotted fever organism. All other tissues are negative, but rectal sac — gut valve — not found.
11	♂ unengorged.	Clumps of minute paired organisms, not distinguishable with certainty from the spotted fever organism, are present in epithelial cells of the diverticulæ. Rectal sac — gut valve — not found. All other tissues are negative.

Summary. — Of eleven unfed adult ticks dissected soon after taking from their habitat, four contained bacilli; in two instances, of large size and generally distributed; in two instances, of small size and restricted to the gut. In no instance were organisms present which could be confused with the spotted fever organism. No intranuclear microorganisms were found in any instance.

In eleven ticks taken from cattle and dissected soon after, three contained bacilli; one micrococci. The bacilli in all instances were confined to the gut, though in one instance because of their small size confusion with the spotted fever organism was possible, and possibly this was in reality an infected tick. No intranuclear microörganisms were found in any instance.

In the two series, totaling twenty-two ticks, none were found with a general invasion of the tissues with organisms

resembling the spotted fever organisms. In two instances only (in the ticks of Lot 773) large, slender bacilli were found in all tissues. The presence of small bacilli restricted to the gut in no way simulates the appearances present in infected ticks.

XIV. PROPERTIES OF THE VIRUS.

1. Filterability. — The protocols of experiments published by Ricketts[51] indicate conclusively that the virus in the blood of infected animals and in the eggs of infected ticks will not pass through Berkefeld filters. I have not thought it necessary to repeat these experiments, but consider it advisable to repeat filtration experiments with the tissues of infected ticks, as it is possible that the minute intranuclear forms of the parasite may prove filterable.

Preliminary transmission experiments made with thoroughly crushed tissues from proved infective ticks have deterred me from attempting filtration experiment, as uncertain results were obtained with the unfiltered crushed tissues suspended in salt solution. The cause of failure to infect animals by tick tissues so treated has not been ascertained. In these experiments, using proved infective ticks, it was not possible to transmit the disease by injecting the thoroughly crushed tissues suspended in salt solution, and I have arrived at the tentative conclusion that the infectivity of the virus was destroyed by the procedure.

2. Resistance to glycerine. — Portions of testis, liver, spleen and kidney of infected guinea-pigs were placed in a large excess of twenty-five per cent and fifty per cent glycerine (Merck's reagent) in distilled water and stored in the ice-chest 7° C. to 10° C. until tested for infectivity. The material before injection was washed in several changes of sterile .8 per cent salt solution and then ground in a mortar, and suspended in salt solution for injection into guinea-pigs. The suspensions were always injected intraperitoneally. The amount of tissue actually injected into each guinea-pig used for the tests was estimated as equal to 1.5 to 2.0 grams of fresh tissue.

Destruction of the virus was considered as proved if the guinea-pig did not develop spotted fever.

The results of these experiments are fragmentary, owing to the loss of several guinea-pigs from epizoötic infections.

However, the emulsions of tissues treated as above conveyed the disease to guinea-pigs after one-day and five-day periods in both twenty-five per cent and fifty per cent glycerine. After a period of one month the virus was destroyed; intermediate periods were not tested, and the only conclusion permissible is that the virus has no marked degree of resistance to glycerine such as is possessed by the viruses of rabies, poliomyelitis and smallpox.

3. Resistance to bile. — In the following experiments ox-bile sterilized by heat (100° C.) was used. The blood from the infected guinea-pigs was drawn directly into an equal amount of bile previously placed in the syringe. Three of five guinea-pigs injected with mixtures of the bile and blood died of peritonitis. The protocols of two that survived are as follows:

Experiment I. — .75 c.c. of blood from California Strain Guinea Pig 113 drawn into an equal quantity of bile at 12.10 P.M., September 28, 1917, and kept at room temperature for three hours, and at 10° C. for twenty hours (total of twenty-three hours), was injected at 11.10 P.M. intraperitoneally into a normal guinea-pig, September 29, 1917. This guinea-pig remained normal and later proved susceptible to an inoculation from Hayes Strain Guinea Pig 56.

Experiment II. — The source of the virus was California Strain Guinea Pig 116. The dose was 1 c.c. of the bile blood mixture; time, three hours at room temperature. Result: Spotted fever in the test guinea-pig.

Results: The virus in blood mixed with an equal quantity of heated ox-bile remained infective for three hours, but was destroyed in twenty-three hours (twenty hours of which were at low temperature.)

4. Resistance to dessication. — Ricketts[51] found that the virus was destroyed some time between twenty-four and forty-eight hours after complete dessication. In his experiments the blood was dried in Petri dishes over sulphuric acid in a dessicator. For complete dessication eighteen to twenty-four hours was required.

In the following tests the blood was rapidly dried in open Petri dishes by directing a current of air upon it from an electric fan. The dried blood was then placed in a dessicator over concentrated sulphuric acid and the air exhausted. The entire process required two hours. The dessicator containing the blood was kept at room temperature in diffuse daylight.

The blood was tested by triturating the dried blood with .8 per cent salt solution and injecting into guinea-pigs.

Experiment I. — 1.2 c.c. of blood drawn from Hayes Strain Guinea Pig 22 at 3.00 P.M., July 13, 1917, and treated as above, was injected into a guinea-pig intraperitoneally July 14, 1917, at 10.45 P.M. (The dosage was actually equal to less than the amount withdrawn and probably .5 to .7 c.c.)

This guinea-pig remained normal and was subsequently proved susceptible to inoculation with blood from California Strain Guinea Pig 97.

Result: Estimating the time of dessication at two hours, the virus was destroyed in fifteen hours, forty-five minutes.

Experiment II. — 1 c.c. of blood drawn from Hayes Strain Guinea Pig 31 at 11.15 A.M., July 25, 1917, and treated as above, was injected into a guinea-pig intraperitoneally July 26, 1917, at 12.00 M. o'clock. (The dosage included the whole amount of blood drawn.)

This guinea-pig remained normal and was subsequently proved susceptible to inoculation with blood from California Strain Guinea Pig 97.

Result: Estimating the time of dessication at two hours, the virus was destroyed in ten hours, forty-five minutes.

5. Preservation in defibrinated and citrated blood. — In these tests the blood was defibrinated immediately after withdrawing it from the heart of infected guinea-pigs, by means of a syringe fitted with a large-sized needle. The infectivity was tested by injection into normal guinea-pigs. At room temperature at the end of five days 0.5 cubic centimeters, injected intraperitoneally, infected guinea-pigs with spotted fever. Kept in the cold room at 7° C. to 10° C. for twelve days one cubic centimeter infected guinea-pigs with spotted fever. The incubation period, at the end of five days at room temperature, and at the end of twelve days in the cold room, was considerably delayed in both instances; in the former instance it was six days, in the latter instance five days. These experiments are incomplete.

Ricketts[51] found that blood retained its infectiousness upon ice for sixteen days, although large amounts, five cubic centimeters, were required to infect. He found that blood which would infect with a dose of .1 cubic centimeter when drawn, in eleven days required two cubic centimeters to infect. In one experiment, at the end of fifteen days upon ice, a dose of three cubic centimeters failed to infect.

Blood from infected animals drawn into equal parts of citrate saline solution (one per cent sodium citrate in .8 per cent sodium chloride solution), and kept in the cold room at 10° C., in doses of 2 to 2.5 cubic centimeters of the mixture, failed to infect at the end of twenty-eight days. The blood from rats infected with African relapsing fever remained infectious under the same conditions for forty days. At room temperature the virus is destroyed in citrated blood in six to eight days.

6. Resistance to heat. — Ricketts found that the virus was not destroyed when heated at 45° C. for thirty minutes; but was destroyed in twenty-five minutes at 50° C.

In our own tests the following technic was employed. Blood from infected guinea-pigs was defibrinated and mixed with an equal part of .8 per cent salt solution, and divided into quantities of two cubic centimeters, which were sealed in glass ampules. The ampules were completely submerged for the tests, in a water bath kept at the desired temperature. One ampule in each experiment similarly filled was fitted with a thermometer and the period of the experiment was recorded from the instant the desired temperature was reached. The ampules were plunged into cold water at the end of the test. The infectivity of the blood at the end of the experiment was determined by injecting one or two cubic centimeters of the mixture intraperitoneally into a normal guinea-pig. In each instance where the guinea-pig did not acquire the disease, it was proved susceptible by a subsequent inoculation with blood from another infected guinea-pig.

The results are recorded in the following table.

TABLE VI.

Source of Virus.	Temperature.	Time.	Result.	Remarks.
Hayes Guinea Pig 31 .	55° C.	15 minutes.	Destroyed.	Dose 1 c.c.
Hayes Guinea Pig 31 .	55° C.	5 minutes.	Destroyed.	Dose 1 c.c.
Hayes Guinea Pig 71 .	55° C.	5 minutes.	Destroyed.	Dose 1 c.c.
Calif. Guinea Pig 133 .	50° C.	15 minutes.	Destroyed.	Dose 1 c.c.
Calif. Guinea Pig 134 .	50° C.	5 minutes.	Destroyed.	Dose 1 c.c.
Hayes Guinea Pig 47 .	49° C.	15 minutes.	Destroyed.	Dose 2 c.c.
Hayes Guinea Pig 47 .	49° C.	10 minutes.	Destroyed.	Dose 2 c.c.
Hayes Guinea Pig 47 .	49° C.	5 minutes.	Not destroyed.	Dose 2 c.c.
Hayes Guinea Pig 46 .	45° C.	15 minutes.	Not destroyed.	Dose 2 c.c.
Calif. Guinea Pig 127 .	45° C.	15 minutes.	Not destroyed.	Dose 2 c.c.
Calif. Guinea Pig 127 .	45° C.	10 minutes.	Not destroyed.	Dose 2 c.c.
Hayes Guinea Pig 46 .	45° C.	10 minutes.	Not destroyed.	Dose 2 c.c.
Hayes Guinea Pig 46 .	45° C.	5 minutes.	Not destroyed.	Dose 2 c.c.
Calif. Guinea Pig 131 .	45° C.	15 minutes.	Not destroyed.	Citrated blood used. Dose, 1.5 c.c.

These results show that the virus will resist 45° C. for fifteen minutes and 49° C. for five minutes. It is destroyed at 49° C. in ten minutes and at 50° C. in five minutes. The destructive temperature therefore lies between 45° C. and 49° C.

7. The resistance to freezing. — In these tests equal parts of blood from infected guinea-pigs and citrate saline solution (.8 per cent salt, 1 per cent sodium citrate) were frozen as soon as possible by placing against the refrigerator coils in a cold room. The probable temperature was −1° to −3° C.

Guinea-pigs inoculated at the end of three and four days' freezing became infected with spotted fever, while those inoculated at the end of nine and twelve days did not become infected.

This experiment indicates that the virus will withstand freezing for a period longer than four and less than nine days.

XV. ROCKY MOUNTAIN SPOTTED FEVER IN EXPERIMENTAL ANIMALS.

1. The disease in guinea-pigs (Figs. 29, 45, 46, 48, 49, 52, 59, 64 and 69.) — After inoculation of blood from a strain established in guinea-pigs, the temperature usually rises to 103° or 104° F. at the end of forty-eight or seventy-two hours, rarely one or two days later.

After inoculation of blood from human cases the temperature usually does not rise until seventy-two to ninety-six hours have passed, and in the first few transfers to guinea-pigs the incubation period may vary from three to five days, until it becomes fixed at from forty-eight to seventy-two hours.

The incubation period when the disease is transmitted by ticks is from three to seven days after the tick has attached, the usual period is four to five days.

After the initial rise, the temperature quickly reaches 105° F. to 106° F., usually on the second or third day, and a high level, 105° to 106° F., is maintained. Death, which usually occurs in well-established strains on the sixth to seventh day of fever, or eight or nine days after inoculation, is preceded by a sudden drop of temperature to subnormal. The uniform course of the disease in well-established strains in guinea-pigs is striking, and resembles the behavior of a fixed rabies virus.

If the guinea-pig is going to recover, the temperature begins to drop at the end of seven or eight days, and gradually reaches normal in a period of from three to six days more. A temperature of 103° to 103.5° F. may persist for a week or ten days.

The first visible sign of the disease in male guinea-pigs is the swelling and reddening of the skin of the scrotum, which occurs on the third to fourth day of temperature, at which time the animal begins to exhibit signs of discomfort, loss of appetite and roughness of coat. The skin of the scrotum soon becomes dull red, and may exhibit a definite line of demarcation about a necrotic portion on the sixth to seventh

day of temperature. (Fig. 52.) Reddening and swelling of the eyelids, ears and paws is not seen as a rule unless the animal survives six or seven days of temperature. Necrosis of the paws resulting in ulcers, and of the ears resulting in dry necrosis and separation, takes place on the tenth to fourteenth day, and may not take place until the temperature is almost normal, or has become fixed at 103° to 103.5° F. for a period of several days.

In female guinea-pigs the reaction to the disease is less striking, as the tissues of the vulva and anus rarely show lesions comparable to those of the scrotum in the male. Ordinarily, unless the animal lives long enough to develop the lesions of paws and ears, we must rely upon the temperature for diagnosis.

The post-mortem findings vary with the duration of the disease. In male guinea-pigs killed at the end of five or six days of temperature, we find œdema and congestion of and hemorrhage into the skin and subcutaneous tissues of the scrotum. The vessels of the skin of the whole surface of the body are finely injected, and this may be seen by removing the skin under anæsthesia. Generalized hemorrhages do not occur into the skin; the scrotum, paws and ears are the only sites of hemorrhage and necrosis of the skin. The inguinal and, to a less degree, the axillary lymph nodes are swollen and reddened.

The peritoneal surfaces and intestinal tract are normal. The spleen is enlarged to three to five times its normal size, is dark-red in color and firm in consistency. There may be a very thin, translucent layer of fibrin upon its surface. The liver usually presents small yellowish opaque areas of necrosis which are common in any infection in guinea-pigs, so that their significance is doubtful. The gastro-intestinal tract is normal. The kidneys are normal. The adrenals usually show injection of the medulla, but hemorrhages do not occur in uncomplicated cases.

The organs of the chest are normal.

The most striking changes are found in the testes and adnexa. The testes are swollen and markedly injected, usually with minute hemorrhages into the tunica at both poles.

The polar fat is discolored and contains small hemorrhages. The cremasteric muscles and parietal tunica are deep red, often hemorrhagic, and both these structures are adherent to each other and to the testes. Small hemorrhages are practically constant in the epididymis, particularly between the testis and epididymis. Hemorrhages into the areolar tissue around the ductus deferens are the rule.

In late cases the testes become adherent in the scrotum, due to organization of the necrotic tissues and exudate, and the subcutaneous tissues surrounding the anus and scrotum are thickened, brawny and hemorrhagic. The seminal vesicles are normal.

The central nervous system may be injected, but shows no lesions. Dissection of the tendon sheaths of the feet in late cases shows a permanent dusky red injection and often minute hemorrhages.

In female guinea-pigs a marked injection of the uterus and ovaries is the rule. Actual hemorrhages are very rare. The other organs exhibit the same lesions as in the male.

Male guinea-pigs, because of the characteristic reaction shown in the scrotum, have been used almost exclusively in my own work; females being employed only when normal males were not obtainable.

Guinea-pigs. Microscopic. — Heart: The heart muscle, pericardium, endocardium, valves and blood vessels invariably have no lesions. Aorta: Without lesions. Lungs: The lungs invariably show a strikingly large number of large mononuclear cells (endothelial cells) in the alveolar capillaries, and cells in mitosis free and attached to the capillary walls are common. These mononuclear cells are frequently phagocytic for red blood cells and polymorphonuclear leucocytes. They are sometimes massed in great numbers, and occasionally there are collections of them containing a rare multinucleated cell in an alveolus. Small arteries and veins occasionally contain collections of a few similar mononuclear phagocytic cells attached to the intima, but the larger vessels are without lesions and thromboses are never found. The

interlobular lymphatics may also contain large numbers of these large mononuclear phagocytic cells. The bronchi are without lesions.

Spleen: Marked congestion of the sinuses and pulp veins, with a heavy accumulation of large mononuclear (endothelial) cells in the blood spaces and in the pulp, are the common features. In late cases the megakaryocytes and erythroblasts and most of the lymphoid cells are absent and the reticular tissue is filled with endothelial cells, many of which enclose red blood cells or polymorphonuclear leucocytes. Mitoses are numerous in the meshes of the reticular tissue, and in the pulp veins (sinuses) where endothelial cells remain attached to the vessel walls while in the act of dividing. There is no evidence of activity on the part of the lymphoid tissue and in cases with advanced lesions the Malpighian bodies are recognizable with difficulty because of their small size and partial replacement by endothelial cells. There are no degenerative lesions or necrosis. Thromboses are absent and the arteries and larger veins are without lesions. The capsule and peritoneal serosa are usually normal.

Liver: The liver may be normal except for an increase in large monocuclear (endothelial) cells in the sinusoids and hepatic veins. These cells while still attached to the sinusoid walls contain red blood cells and polymorphonuclear leucocytes and fragments obviously derived from these elements; occasionally attached endothelial cells are in mitosis. The arteries and larger veins are free from lesions. The bile passages are normal. In many livers small necroses are found, consisting of from one to several vacuolated, deeply staining liver cells with pyknotic nuclei and invaded by polymorphonuclear leucocytes. Extensive necroses are probably attributable to other processes, as they are not common in uncomplicated spotted fever in guinea-pigs. The capsule and peritoneal serosa are normal.

Pancreas: The pancreas is invariably normal. Gastrointestinal tract: Invariably normal. Kidneys: The kidneys usually show an increase in the number of cells in the glomeruli, due to the accumulations of mononuclear (endothelial)

cells in the capillaries. Mitosis of the capillary endothelium is of exceedingly rare occurrence. The renal epithelium shows no lesions. The blood vessels are normal.

Adrenal gland: Beyond a moderate injection, usually normal. Rarely a small necrosis is found in the fasicular zone in the cortex. The blood vessels are normal. Peripheral lymph nodes: The sinuses are distended from fluid containing many large mononuclear phagocytic (endothelial) cells containing mostly red blood cells. The reticular tissue also contains many similar cells. The blood vessels are injected but show no lesions.

Testes and adnexa: The seminiferous tubules show degenerative changes to a degree corresponding with the lesions present in the blood vessels. Cessation of spermatogenesis is common, with complete absence of the spermatids. The disappearance of the spermatids is preceded by a stage in which greatly swollen cells of this series are found undergoing atypical multipolar mitotic division. The tubules of the rete and epididymis rarely show lesions except where involved in small perivascular necroses. The blood vessels of the interstitial tissue, the tunica, epididymis, polar fat and of the cremasteric muscle invariably show striking lesions and the presence of the minute paired microörganism in the lesions. The earliest lesions consist of collections of endothelial cells heaped up *in situ* in the intima of arteries and veins, or filling capillaries. Mitotic figures are common in arteries and veins and frequently vessels of fair size are completely occluded by masses of endothelial cells. These cells can also be traced in migration through the media, whence they go to form compact zones in and around the adventitia; further multiplication occurs in these perivascular accumulations, as is evidenced by numerous mitoses. (Figs. 45 and 49.) Small deposits of fibrin are found in arteries and veins, and occlusion may result from this type of thrombosis. The infiltration of the media with endothelial cells and polymorphonuclear leucocytes also leads to a marked degree of concentric thickening and diminution of caliber. Hyaline degeneration and necrosis of the smooth muscle cells is of invariable occurrence,

and frequently the original lumen of an artery is indicated by the deeply acidophilic staining of the inner zone of muscle cells (Fig. 45). In the interstitial tissue of the testis and epididymis small veins and capillaries become filled with endothelial cells and the connective tissue and lymphatics also acquire large numbers of them. These cells often contain red blood cells, lymphoid cells and polymorphonuclear leucocytes. Arteries and veins, in addition to fibrin formation, frequently contain masses of fused hyaline-appearing red blood corpusles. Fairly extensive areas of necrosis occur in the testes, tunica and cremasteric muscles, accompanied by the appearance of fibrin, polymorphonuclear leucocytes, lymphoid and plasma cells and eosinophiles. The serous epithelium of the tunica is usually swollen and cuboidal and the surface when adjacent to underlying necroses becomes covered with an exudate of fibrin and cells. Organization of this exudate occurs in late cases with resulting fusion of the parietal and visceral tunicæ. In the endothelial cell and in smooth muscle cells of arteries and veins with lesions the minute paired microörganism is found in large numbers. Smooth muscle cells literally become packed with them, so that their presence enables the tracing of the course of the infected cells at the branching of blood vessels (Fig. 69). The parasites occur also in detached endothelial cells lying in the lumina of vessels and less frequently can be found in the cells in the perivascular zones.

Skin: The skin of the scrotum, anus and prepuce invariably is the seat of similar lesions of the blood vessels. (Figs. 48, 49, 64, 69.) In advanced cases the skin of the ears and the paws shows the lesions. In guinea-pigs the skin from other locations has not been examined. In the skin the blood vessels show more tendency to form fibrin thrombi, and less marked perivascular zones of endothelial cell infiltration. Secondary degeneration and necrosis of the appendages of the skin, hair follicles and glands is always present, and often extensive necrosis and ulceration of the skin of the scrotum, ears and paws result from the obliteration of blood vessels. Secondary infection of the necrotic skin produces the usual microscopic appearances of suppuration.

The tick bite: Microscopic examination of the seat of the bite of infected ticks shows several interesting features. The epidermis at the point of attachment is absent, and the surface of the exposed corium is necrotic and infiltrated with fibrin and leucocytes. Regeneration of the epidermis occurs at the edges, while the tick is still feeding. Extending from the surface into the corium are diverging strands of fibrin. The corium is œdematous, the strands of collagen are widely separated, and new fibroblasts are present in great numbers in a wide zone surrounding the point of attachment and extending into the subcutaneous tissue and even into the muscle panniculus. In the central portion of the lesion are distributed large numbers of mononuclear phagocytic (endothelial) cells enclosing red corpuscles and polymorphonuclear leucocytes. These endothelial cells often contain large numbers of the minute paired parasites (Fig. 59). The characteristic endothelial proliferation in blood vessels is present after the animal becomes infected. In case of recovery from the infection the seat of the tick bite leaves a dense plaque of fibrous tissue occupying the lower layers of the corium and subcutaneous tissue. Control bites of normal ticks have not been studied, but it is evident that the material injected by the feeding tick stimulates a marked proliferation of fibroblasts. The surface lesion repairs by organization.

Bone marrow: There are no lesions; normal activity is invariably present.

2. The disease in rabbits (Figs. 6 and 7). — Unlike guinea-pigs, the susceptibility of the rabbit is subject to vagaries which have not yet been explained. The disease in rabbits has recently been studied by Foot[17] in my laboratory. In one of two attempts the disease was transmitted to a rabbit by ticks which were infected as nymphs. (See page 99.)

In fourteen inoculations of rabbits with blood from guinea-pigs, ten developed the disease in typical form, three gave doubtful reactions, and one resulted negatively. In eleven inoculations from rabbits to rabbits, six were unmistakably positive, two were doubtful and three negative. Foot has

pointed out the impossibility of maintaining the strain in rabbits without alternating with guinea-pigs, but further work is necessary to discover the cause of this difficulty. It seems probable that the virus is present in the blood for a shorter time than is the case with man, monkey and guinea-pig. That this is the case is supported by the fact that it has been occasionally impossible to infect guinea-pigs from rabbits showing unmistakable anatomical and febrile evidence of the disease.

The course of the disease after successful inoculation is practically the same in rabbits as in guinea-pigs, and the gross pathology is identical. The ears play a more prominent part in the symptomatology, often becoming swollen, reddened and drooping. It is possible to see thrombosed vessels in the ears of white rabbits, and to watch the development of areas of dry necrosis and the separation of such areas (Figs. 6 and 7).

The following is a typical record of a rabbit inoculated from a guinea-pig. The record of the positive tick transmission is included on page 99 in connection with the protocols of ticks infected as nymphs.

Record of Rabbit 3, Hayes strain. A three-fourths grown, pure white, male rabbit, inoculated intraperitoneally with 2 c.c. of blood in citrate saline solution from Guinea Pig 75, Hayes strain.

December 19, 1918, inoculated. Temperatures: December 20, 102.6; December 21, 102.4; December 22, 103; December 24, 103; December 26, 105; December 27, 105.4; December 28, 106; December 29, 105.4, left scrotum red and swollen; December 31, 105. January 2, 104, a small ulcer on left scrotum; January 3, 103.6, ears swollen, bluish red, marginal veins thrombosed; January 4, 103; January 5, 104.6; January 7, 104, scrotum indurated, ulcer healed; January 8, 102.6; January 9, 104.6, dry necrosis of outer margins of ears, 3 x 2 cm. on left ear, about 1 cm. in diameter on right ear; January 25, separation of necrotic portions of ears.

The histology of the vascular lesions in rabbits is identical with that in guinea-pigs except for minor quantitative differences. The parasite of the disease occurs in equally large numbers in the same cells and situations as in guinea-pigs. The liver necroses and degenerative changes in the testes are similar; in the latter, however, large, multinucleated cells

in the lumina of the seminiferous tubules resulting from atypical division of spermatids is a prominent feature. The spleen shows greater phagocytosis of red blood cells and apparently a more rapid digestion of the phagocytosed cells shown by a more extensive pigment formation and the occurrence of dark-colored, fused corpuscular masses in endothelial cells in the splenic veins or sinuses.

3. The disease in monkeys (Figs. 47, 50 and 65). — Four monkeys were inoculated from guinea-pigs, two were *Rhesus macacus*, one a South American capuchin and one a Java *Rhesus*. One *Rhesus macacus* was a female; the others were males. All proved equally susceptible and all succumbed by the end of the seventh day. The female *macacus* was killed while moribund on the seventh day. The strains used were Strain I. and the Hayes strain. No temperatures were taken, as the objects of these experiments were to observe the character and localization of the lesions and to demonstrate the parasite in the lesions. The dosages varied from two to three cubic centimeters of blood given intraperitoneally in citrate saline solution.

The course of the disease in these monkeys was rapid. The animals became obviously ill on the fourth to fifth day, and on the fifth or sixth day would assume and maintain the sleeping posture until death. Swelling and redness of the scrotum was observed in the males on the fifth day. In the female no changes were seen at the vulva. A slight erythema of the chest and anus was seen in the female monkey before death.

The post-mortem findings were as follows:

A diffuse dusky injection of the small vessels of the skin and subcutaneous tissues, but no hemorrhages. Tendon sheaths and muscle fasciæ normal. Inguinal and axillary lymph nodes enlarged and reddened. The peritoneal surfaces were normal. The pleural and pericardial surfaces were normal. The heart and lungs were normal. The spleen was enlarged in each instance to about double normal size, deep red in color, and firm. The liver, pancreas and gastro-intestinal tract were normal. The omentum in one instance was deeply injected.

The kidneys were normal. The adrenals showed injection of the medulla, but no hemorrhages.

The bladder was normal in each instance. The retroperitoneal lymph nodes were slightly enlarged. In the female no lesions of the genitalia were found.

In the male monkeys the subcutaneous tissues of the scrotum were invariably œdematous and deeply injected and contained small hemorrhages.

The cremasteric muscles were injected. The tunica vaginalis in each case was reddened and in one instance studded with petechiæ. The testes were invariably deeply injected and swollen. The epididymes were swollen and injected.

The organs of the neck, buccal and pharyngeal mucosæ showed no lesions. The brains and meninges showed no lesions.

This series, while small, is significant in showing the same localization of lesions seen in guinea-pigs and rabbits and in man.

Microscopic. Monkey 4. — Heart: Normal. Lung: There is marked injection of the capillaries in the alveolar walls and the capillaries contain large numbers of large mononuclear cells with round or horseshoe-shaped nuclei and numerous polymorphonuclear leucocytes. There are rare mitotic cells in the alveolar wall capillaries. The large blood vessels and bronchi are normal. The alveoli contain no exudate.

Spleen: There is marked injection. The Malpighian bodies are small, and many contain scattered polymorphonuclear leucocytes and small collections of large phagocytic mononuclear cells which contain lymphoid cells and polymorphonuclear leucocytes. The reticular tissue of the pulp is almost devoid of lymphocytes and contains red blood cells, numerous polymorphonuclear leucocytes and large mononuclear phagocytic cells. The sinuses and splenic veins contain many large mononuclear phagocytes, and occasional masses of fused hyaline-appearing red blood cells, sometimes surrounded by one or more phagocytic cells. The arteries are normal.

Liver: There is a marked uniform injection of the sinusoids. There is a marked uniform fatty infiltration of the liver cells in the form of large droplets. An occasional single liver cell is necrotic and invaded by polymorphonuclear leucocytes. In the sinusoids there is a slight excess of polymorphonuclear leucocytes and numerous large mononuclear phagocytes (endothelial cells), some of which are attached to the walls of sinusoids. These cells contain red blood cells, leucocytes, and often dense, granular hyaline material suggesting fused red blood cells. A rare endothelial is in mitosis. The arteries, veins and bile passages are normal.

Pancreas: Normal. Gastro-intestinal tract: Œsophagus, stomach, jejunum, ileum, colon: all normal. Kidney: Normal.

Adrenal: The veins and capillaries are greatly distended with blood. The outer half to two-thirds of the fascicular zone shows a diffuse infiltration of the cell columns with polymorphonuclear leucocytes, and there are small gaps in the columns which are filled with mononuclear phagocytic cells (endothelial cells) and polymorphonuclears. There are many adrenal cells which show hyaline change and fragmentation. The capillaries contain occasional endothelial cells in mitosis and free mononuclear cells with inclusions of red blood cells and nuclear fragments. The medulla is negative except for the marked distention of the blood vessels.

Testes and adnexa: A rare seminiferous tubule shows complete cessation of spermatogenesis with disappearance of the spermatids; such tubules being lined with large, pale, elongated cells, probably derived from the sustentacular cells. The great majority of tubules are normal. The interstitial tissue in a few places is œdematous, and occasional occluded vessels are found similar to those in the tunica and epididymis. The epididymis and ductus deferens show no lesion of the epithelial structures. The blood vessels of the tunica vaginalis, the cremasteric muscles, the epididymis and pampiniform plexus show numerous and striking lesions of the intima, the smallest consisting of collections of endothelial cells attached to the endothelium, while more extensive lesions consist of

complete thrombosis and extensive collections of endothelial cells in the intima. There are many mural thrombi composed of endothelial cells, fibrin and polymorphonuclear leucocytes. In the testes and epididymis small veins and capillaries are occasionally completely filled with endothelial cells, some of which are phagocytic. The minute paired organisms are present in fair abundance in the endothelial cells of mural thrombi and in smaller collections attached to apparently normal intima (Fig. 50). In tangential sections of arteries with but slight lesions the organisms can be found in the smooth muscle cells of the media as well as in the endothelium.

Prostate: A rare blood vessel in the capsule shows lesions like the above. The gland itself is normal.

Seminal vesicles normal. Urinary bladder normal. Aorta normal.

Lymph nodes: Lymph nodes from axilla and groin and the mediastinum show a marked accumulation of large mononuclear cells, some of which are phagocytic (endothelial cells) in the sinuses. The peripheral lymph nodes are deeply injected with blood as well. All lymph nodes contain but few polymorphonuclear leucocytes. The secondary follicles are inactive.

Skeletal muscle: An occasional muscle fiber is swollen and convoluted in shape, without striations, and has assumed a homogeneous, glassy appearance (waxy degeneration). A rare small artery and vein show lesions like those in the testes.

Skin: The skin from all parts of the body shows extensive lesions of the blood vessels with thromboses similar to those of the testes and epididymis (Figs. 47 and 65). The large arteries and veins of the subcutaneous tissue show the most marked lesions, and occasionally the smooth muscle of the media is degenerated and infiltrated with leucocytes beneath a mural thrombus. There is a very marked engorgement of all blood vessels of the skin. The capillaries of the papillæ occasionally are filled with endothelial cells and are rarely thrombosed. The capillaries about the coil glands are usually filled with fibrin and endothelial cells. Complete thrombosis

of large arteries and veins is rare, but is present in the subcutaneous tissue. The epidermis and hair follicles and sebaceous glands are negative. The coil glands show marked degenerative changes, in many instances the epithelium is desquamated and the lumen filled with polymorphonuclear leucocytes and hyaline cell débris. The minute paired organism is present in the endothelial cells and smooth muscle of blood vessels showing lesions.

Mucosa of the buccal cavity: The epithelium and glands are normal. In the muscle beneath the mucosa an occasional artery shows small lesions of the intima. The organism is present in abundance in several such arteries.

Brain: Cortex cerebri. Sections from five different regions are normal. The meninges are normal. Cerebellum normal. Choroid plexus normal. Medulla and cervical cord normal.

XVI. THE PATHOLOGY IN MAN. SUMMARY.

The only distinctive gross features in Rocky Mountain spotted fever are those connected with the distribution and character of the cutaneous and subcutaneous lesions of the blood vessels and the lesions of the male genitalia, particularly the scrotum and the testes. The extensive hemorrhages into the scrotal tissues, often with necrosis and similar lesions of the testes and their appendages, are the most characteristic gross findings in animals as well as in man. The spleen in man, as in animals, is always enlarged to several times the normal size, and is firm unless there has been a secondary bacterial infection.

The microscopic lesions of the disease are those dependent upon focal lesions of the peripheral blood vessels, and to a general increase of large mononuclear phagocytic cells (endothelial cells) in the capillaries of various organs.

Heart: In Case I. there are small collections of endothelial cells in the endocardium and a few microscopic mural thrombi. In Case V. there are a few minute degenerative lesions of the myocardium, and occasional intra- and perivascular accumulations of endothelial cells.

Lung (Fig. 67): The lungs from the cases examined — II., III. and V. — show large numbers of mononuclear phagocytic cells (endothelial cells) in the alveolar capillaries. In Case V. there is broncho-pneumonia.

Spleen (Fig. 62): In all four cases with complete autopsies there is extreme engorgement with blood, almost complete loss of lymphoid cells, and a great accumulation of large mononuclear phagocytic cells (endothelial cells) in the splenic veins (sinuses) and reticular tissue. These cells contain many red-blood corpuscles.

Liver (Fig. 61): There are a few minute focal necroses in all four cases, while throughout there are many phagocytic mononuclear cells (endothelial cells), free in the sinusoids or attached to the walls. These cells contain red-blood corpuscles and occasionally leucocytes. In the liver of Case V. a few arteries, veins and capillaries in the portal spaces show small lesions of the intima and a perivascular infiltration of endothelial and polymorphonuclear leucocytes. A small number of the minute parasites are present in these lesions.

Gastro-intestinal tract (examined only in Cases II., III. and V.): In Case II. a single artery in the wall of the stomach was found with a mural thrombus. In Case III. there are several small vessels and capillaries with mural thrombi. The intestines are normal in both of these cases. In Case V. the stomach and intestines are normal.

Pancreas (examined only in Cases II., III. and IV.): No lesions are present.

Kidneys: No acute lesions of the kidney tissue or blood vessels are found in any of the four cases. The glomerular capillaries contain a few free endothelial cells in each case.

Adrenals (examined only in Cases II., III. and IV.): No lesions of importance are present. The blood vessels are normal.

Thyroid (examined only in Cases II. and IV.; in the latter it is normal): In Case II. the intima of arteries and veins shows minute lesions with mural thrombi like those in the vessels of the skin. These lesions contain the minute parasite of the disease.

Lymph nodes (examined in Cases II. and III.): From all regions — axillary, inguinal, mesenteric and bronchial — there is a similar picture, namely, the accumulation of large mononuclear phagocytic cells (endothelial cells) in the sinuses and medullary areas.

Aorta and large blood vessels: The aorta in Cases II., III. and IV. shows no acute lesions. The large blood vessels in all four cases of the principal organs of the body in no instance contain lesions.

Skeletal muscle: Muscle from Cases III., IV. and V. shows occasional lesions of the blood vessels like those found in the skin. The muscle fibers show small patches of waxy degeneration.

Central nervous system (examined in Case II.) is normal.

Skin and subcutaneous tissues (Figs. 44, 51 to 58, 60, 63, 65, 66 and 70): The skin and subcutaneous tissues taken from all parts of the body from all five cases show extensive lesions of the blood vessels. Though the lesions vary in degree and number, they represent the same process, and for this reason but one description of their character is given, based on a careful study of many blocks from each case. The number of affected vessels in the skin corresponds roughly with the extent and age of the rash; for instance, there is greater involvement of the vessels of the skin of the legs than of the skin of the abdomen, which agrees with the evolution of the eruption. Similarly, in the male the lesions of the vessels of the scrotum are very numerous and marked.

The most striking lesions are found in large-sized arteries and veins of the lower layer of the corium, and in the subcutaneous fat, where completely thrombosed vessels are common. The earliest lesion in these vessels is a collection of large mononuclear phagocytic cells (endothelial cells) over an area of swollen and degenerated endothelium of the intima (Figs. 60, 63 and 66). In arteries there is fragmentation of the internal elastic lamina and collections of polymorphonuclear leucocytes beneath it and in the media. In these early lesions the minute paired parasite is found in large numbers, in endothelial cells, and in smooth muscle cells of the media.

Many of the endothelial cells and smooth muscle cells containing the parasites show hyaline change and a preference for the basic stains. More extensive, and presumably later, lesions affect the whole circumference of the vessel, so that there may be a concentric thickening of the intima due to the accumulation of endothelial cells upon and in the intima (Figs. 51 and 54). Fibrin deposits are found about degenerated endothelial cells and in the media, and finally complete thrombosis results. In longitudinal sections of vessels (Fig. 51) it is possible to see numerous foci of fibrin deposit along the course of the thickened intima. The extension of fibrin thrombi beyond the seat of the initial lesion accounts for the finding of cross-sections of vessels filled with fibrin thrombi without marked lesions of the wall. In late lesions the whole vessels wall becomes infiltrated with endothelial and polymorphonuclear leucocytes; and surrounding the vessel a zone of large mononuclear phagocytic cells (endothelial cells) forms. Early stages of repair were seen in Case I. in vessels of the skin of the legs, in beginning canalization of thrombi. The minute paired parasites are most numerous in the early and moderately advanced lesions. They vary in size; larger, lanceolate forms, in pairs, which together measure slightly less than one micron in length, are found in endothelial cells and in smooth muscle cells (Figs. 44, 63, 66). Much more minute forms occur in enormous numbers in smooth muscle cells, and these forms are comparable in size to the intranuclear forms found in ticks.

Lesions of the papillary capillaries and subpapillary plexus of the skin are in general similar to those of the larger vessels, though modified by the difference in thickness of the vessel walls. Briefly, these vessels become filled with proliferated endothelial cells (Fig. 70), some of which become necrotic. Perivascular collections of endothelial cells occur also with necrosis, and then accumulations of polymorphonuclear leucocytes (Figs. 57 and 58). Thrombi of fibrin are found. The plexuses of capillaries around the coil glands are particularly liable to these lesions. Infiltration of nerves with polymorphonuclear leucocytes and mononuclear amœboid cells (endothelial cells) was found in Cases I. and II.

The epidermis may show changes dependent upon the infarctions of minute areas of the corium. Microscopical losses of epidermis occur.

The lesions of the skin of the ears and scrotum of guinea-pigs and rabbits, and of the skin of the scrotum in monkeys, are identical in character with those of the human cases, — initial endothelial cell proliferation, followed by thrombosis and perivascular proliferation.

Testes and adnexa: In all four male cases very extensive lesions, similar in all respects to those of the skin and subcutaneous vessels, are found in the arteries, veins and capillaries of the testes, epididymis and pampiniform plexus. The parasites are as numerous in these locations as in the skin.

The lesions of Rocky Mountain spotted fever in man and in experimental animals are practically restricted to the peripheral blood vessels, including those of the external genitalia. The vascular lesion is in the beginning a proliferative lesion on the part of the vascular endothelium. Varying degrees of intensity in the reaction are encountered, so that polymorphonuclear leucocytes may or may not play a part in the lesions before the occurrence of thrombosis. Following thrombosis, polymorphonuclear leucocytes are of necessity present. A direct injury to cells by the parasite is shown by the degenerative changes found in the endothelial cells and in the smooth muscle cells of the media, which are also invaded by the parasite. The general reaction to the disease, and possibly to the toxin of the parasite, is shown by the finding of endothelial cell accumulations in the blood vessels of the lung, liver, spleen, and in the lymph nodes.

One feature of Rocky Mountain spotted fever which cannot be too strongly emphasized is that it may be exactly duplicated in experimental animals. This duplication of the clinical and pathological picture takes place no matter how the virus is introduced, whether by intraperitoneal or subcutaneous inoculation, or through the medium of a tick. When transmitted by a tick, the incubation period is about the same as that in man. In non-fatal cases, the duration of the disease

is about the same. The character of the temperature curve is almost identical, but most striking of all is the exact duplication of the pathology, both in regard to the tissues affected and in the distribution of the lesions. In all animals, as well as in man, Rocky Mountain spotted fever is a disease of the peripheral blood vessels, an acute specific infectious endangiitis.

XVII. CASE REPORTS.

Case I. — A well-developed, vigorous woman, age 26 years, a new arrival and resident in Saw Tooth Canyon, in the Bitter Root Valley, near Hamilton, became ill on April 27. On April 23 a partially engorged tick was removed from the back of her neck. The first symptoms noted were pains in the arms and legs and flushing of the face. On May 1 she noticed a rash on her legs and she came to Hamilton for medical care. When examined on the evening of May 1 she had a short, moist cough; her face was flushed and there was a mottled erythema over the forehead and neck and a macular eruption, disappearing upon pressure, thickly distributed over the whole body, but most prominent over the arms, shoulders, buttocks and legs. The temperature was 105° F., pulse 96, respirations 24. She was extremely restless, slept for a period of fifteen minutes only during the night, and vomited several times. On May 2, by daylight, a slight yellowish cast of the skin was apparent and the rash was more apparent. The lesions averaged about one to each square centimeter of surface, were 1 to 3 mm. in diameter, just perceptibly elevated and disappeared upon pressure. There was a marked erythematous mottling of the forehead, the face was flushed, the conjunctivæ moderately injected and the tongue coated. The buccal mucosa, the fauces, tonsils and palate were negative.

The treatment consisted of enemas, calomel, and "aspirin" in large doses. To this last may be attributed the low temperature from this date. The diet was restricted to liquids, largely buttermilk and lemonade. Tepid sponge baths were given. The patient continued to be restless and did not sleep. On May 3, the rash seemed less pronounced. Her mental condition was good though she complained of a severe headache. At noon, 125 cc. of blood was transferred by the indirect method in a paraffined tube from an immune donor. White blood count at 3.00 P.M., 7,300. During the night she became delirious and got out of bed.

On May 4 her condition was worse. She had a hard, dry cough. The skin of the face, neck and thighs was cyanotic, and a deep mottling of dull red appeared on the thighs. She became extremely sensitive to the touch; the slightest pressure over the tibia for instance caused severe pain. The yellowish cast to the skin was now pronounced. The tongue was heavily coated along the middle third; the edges were clear. The throat, palate, tonsils and buccal mucosa appeared to be normal. During the afternoon

she became slightly delirious and again passed a sleepless night. White blood cell count, 7,300. Red blood cell count, 5,008,000.

On May 5 the cyanosis and icterus were more pronounced. There was a marked dilatation of the veins on the outer surfaces of the thighs, marked cyanosis of the legs, and a few petechiæ on the thighs and buttocks. The cutaneous hyperæsthesia became so marked that the pressure of the bedclothes became unbearable. There was also severe deep pain in the legs. Towards evening the increase in the number and size of the petechiæ was pronounced and the thighs assumed a marbled appearance due to the prominence of the engorged veins of the skin.

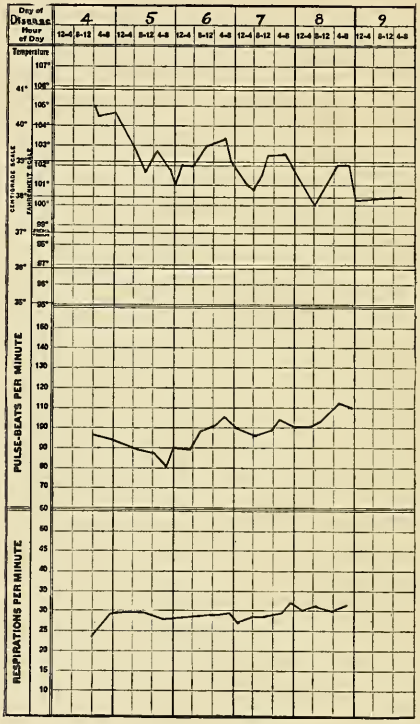

Charts of temperature, pulse and respiration of Case I. Woman, age 26. Death on ninth day of disease.

On May 6 in the early morning she was mildly delirious and almost moribund. Her arms and legs became dull red and cold. Death occurred at 3.00 P.M. Rigor mortis set in almost immediately. After death there was a marked blanching of the skin of the trunk and legs. The distended veins of the thighs had disappeared but dull red areas 0.3 to 0.7 cm. in diameter remained. The face remained cyanosed and bloated in appearance.

No post-mortem was permitted. Pieces of skin were removed from the arms, buttocks, thighs, legs and ankles. Incision of the skin of the thigh through the persistent red areas showed these to be due to extravasated blood in the corium and subcutaneous fat.

The urine was examined but once owing to menstruation, which was in progress upon admission. On May 5 the specific gravity was 1,021, color pale, perfectly transparent. There was the slightest possible trace of albumin, no sugar. No microscopic examination was made. The differential blood counts are given on page 32.

Throughout the illness, examination of the chest was negative. The behavior of the heart is shown in the chart, the pulse became progressively more feeble with increasing rapidity.

The heavy "aspirin" medication, 275 grains in all, was responsible for the relatively low temperature maintained after the first day in the hospital.

Two guinea-pigs inoculated each with five cubic centimeters of blood in citrate saline, taken on May 3, developed typical lesions and temperatures of spotted fever. From these guinea-pigs the strain was maintained for three generations while infecting ticks and then voluntarily abandoned.

Spotted fever Case I. Microscopic description. Eosin, methylene-blue and Giemsa stains (Figs. 53, 54 and 57). Skin from buttocks: There is marked injection of all blood vessels. There are striking acute lesions of blood vessels of all sizes. Arteries and veins of large size in the deep layer of the corium and subcutaneous fat contain lesions of the intima and often mural and occluding thrombi of fibrin and cells, and the walls are often infiltrated with leucocytes. Small vessels in the fat tissue and in the corium are thrombosed and surrounded by collections of cells. The papillary capillaries of the skin and capillaries surrounding coil glands are filled with large cells and surrounded by collections of cells. The vessels of the subpapillary plexus are similarly affected. The epidermis shows no apparent change. The coil glands often show marked vacuolization of the cells, and many contain only desquamated cells with pycnotic nuclei. Hair follicles and sebaceous glands show no apparent change.

The smallest lesions of arteries and veins consist of small masses of fibrin attached to the intima and usually completely surrounded by endothelial cells. Larger lesions consist of extensive masses of coarsely reticulated hyaline fibrin, some strands of which may extend into the media, enclosing polymorphonuclear leucocytes and large mononuclear phagocytic cells (endothelial cells) and granular nuclear remains. The surface of the fibrin is covered with large, flattened endothelial cells, continuous with the vascular endothelium and polymorphonuclear leucocytes. The media is usually heavily infiltrated with polymorphonuclear leucocytes and mononuclear phagocytic cells (endothelial cells). The adventitia and surrounding connective tissue often contains large numbers of large mononuclear cells, some of them phagocytic, lymphoid and plasma cells and polymorphonuclear leucocytes. Smaller arteries and veins are completely filled with large branching cells attached to the vessel wall, phagocytic cells and polymorphonuclear leucocytes in a fibrin meshwork (early organization). The capillaries of the papillæ and coil glands are sometimes occluded by fibrin and large mononuclear phagocytic cells (endothelial cells) and polymorphonuclear leucocytes; they are often surrounded by zones of similar cells. Other capillaries are patent, contain numerous large mononuclear phagocytic cells enclosing red blood corpuscles and other cells and are surrounded by narrow zones of lymphoid and plasma cells, mononuclear phagocytic cells and an occasional eosinphile.

The nerves for the most part show no lesions; a few, however, contain large mononuclear cells, mast cells and a rare polymorphonuclear leucocyte. One nerve trunk of large size contains a capillary occluded and surrounded by endothelial cells and polymorphonuclear leucocytes. In the fat lobules below the corium there are a few small areas of hemorrhage, occasionally in relation to a vessel with marked lesions. In a few vessels showing lesions there are numbers of minute paired organisms, sometimes round, sometimes lanceolate in shape, and usually surrounded by a narrow clear zone or halo. These organisms occur in swollen endothelium *in situ*, in

rounded endothelial cells, in fibrin and rarely packed in a smooth muscle fiber. The length of the pairs measures slightly less than one micron; the breadth is estimated at about one fourth of a micron.

Skin from thigh: The lesions are identical with those of the skin from the buttock. There are many vessels of large caliber in these sections, and several arteries and veins are found with beginning organization and canalization of the fibrin thrombi, and such vessels usually show no infiltration of the media. The minute parasites cannot be found in the vessels with these older lesions. A fair-sized vein in the subcutaneous fat, cut longitudinally, shows a valve covered on the proximal side with a thrombus composed of fibrin, large numbers of mononuclear phagocytic cells (endothelial cells) and polymorphonuclear leucocytes. In the endothelium of the vein adjacent to the thrombus are several pairs of the minute organisms.

Skin from arms: The lesions are similar to those described, though less numerous.

Skin from lower leg: The vascular lesions of the subcutaneous tissue of the leg are more numerous than from any of the other locations, though identical in nature. The minute parasites are found in the lesions in endothelium and smooth muscle. The subcutaneous fat shows more hemorrhages, and the connective tissus septa are œdematous. Many fat cells are shrunken and filled with faintly staining granular material, many are surrounded by large crescentic cells, occasionally multinucleated with foam-like cytoplasm. There are a few oval and round giant cells occupying spaces and filled with fat. Between fat cells there are occasional large mononuclear cells (endothelial cells) which have taken up red blood corpuscles and other cells, probably lymphoid cells.

Case II. Hayes. — This case was that of a stalwart, old white man, 75 or 76 years old, who lived on O'Brien Creek, a tributary of the Bitter Root River. He was employed in placing poisoned baits for ground squirrels, and was notoriously careless in regard to ticks, and took but little trouble to remove them from his person. Several days before the onset of his illness he complained of a particularly irritating bite over his right

scapula. The onset, as far as could be determined, began the evening of May 2 with severe pains in his legs and back and burning sensations of his feet and ankles, which he said felt as if they were parboiled. He did not report for work on May 3. On May 4 he claimed to have had dysentery. On May 5 he had nausea and vomiting but remained up. On May 6 he was found on the ground, delirious, too weak to walk to the well for which he had started. He was taken to St. Patrick's Hospital on the evening of May 6, where several ticks were detached from his body.

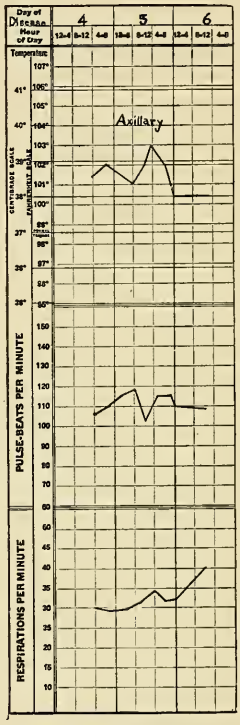

Charts of temperature, pulse and respiration of Case II. Male, age 75. Death on sixth day of disease.

A rash was first noticed on May 7 in the form of faint red, non-elevated areas .3 to .5 cm. in diameter, thickly scattered over his body but most marked on his arms, shoulders, thighs and legs. These areas disappeared upon pressure. The face was flushed in appearance in spite of a heavy coat of tan. The conjunctivæ were injected. He remained in a semi-conscious state, with lax muscles, insensible to ordinary stimuli, but capable of being roused sufficiently to answer questions.

On May 8 the rash was more pronounced. There was a yellowish cast to the skin and a slight general cyanosis of the skin of the legs and thighs.

He was completely unconscious and died quietly at 11.30 A.M. after several periods of stertorous respiration.

The blood counts fifteen minutes before death were: Red blood corpuscles, 6,072,000; White blood corpuscles, 2,100.

A differential white count made on May 7 is recorded on page 32.

Two guinea-pigs were inoculated on May 7, each intraperitoneally, with five cubic centimeters of blood in citrate saline solution. Both developed typical lesions and temperatures of spotted fever. Ticks were infected by feeding upon one of these guinea-pigs and from these ticks the strain was again established in Boston. (See Chart 4, page 59.)

Autopsy. Spotted fever, Case II. One and a half hours post-mortem. Missoula, Mont., May 8, 1917, at 1.00 P.M. (by daylight). — Body: Is that of a tall, well-developed and fairly well-nourished white man, 180 centimeters long. Body heat present. No rigor. Very slight post-mortem lividity in dependent parts. There is a marked arcus senilis on each cornea. On the left cornea there is a linear horizontal opacity three millimeters long. The pupil is eccentrically situated towards the inner margin; measures .2 millimeter. The iris is irregularly pigmented brownish. The right pupil measures .4 millimeter, is symmetrical. On the scalp over the right frontal bone posteriorly is a series of shallow linear abrasions of the skin, covering an area two by three centimeters. On the left side of the neck behind the sterno-cleido-mastoid muscle is an elevated circular lesion .4 centimeter in diameter, with a central excoriated and crusted brownish area .2 centimeter in diameter. The adjacent skin is not discolored. In the right axilla is a similar lesion. Over the pubis is a similar somewhat larger lesion, with a central excoriation .4 millimeter in diameter. (These lesions are said to be typical of the bites of *Dermacentor*.) Above and to the right of the pubic hair is a shallow ulcer (caused by the excision of the skin to which a tick was fastened). On the buttocks, arms, thighs and legs are a few dull red areas and innumerable punctate red spots. There are similar lesions on the sides and back of the abdomen. The pendent portion of the scrotum is discolored deep red. There is no œdema.

Incision of the skin in various places reveals an occasional reddish area in the subcutaneous fat just beneath the corium. Incision down to the tendons of the foot on the front of the ankle shows a marked capillary injection of the walls of the tendon sheaths. The subcutaneous tissues of the scrotum are infiltrated with sanguineous fluid. The ears and nasal sinuses are normal. The mouth is clean. Five teeth only are present, the left lower lateral incisor and canine, the right lower lateral incisor, canine and first bicuspid. There are no teeth on the upper jaw.

Peritoneal cavity: The subcutaneous fat of the abdomen is pale yellow, one centimeter deep, and not discolored. The muscles are firm, deep red in color. The peritoneal surfaces are everywhere smooth, glistening, moist, no free liquid; no adhesions. The appendix is six centimeters long, hangs dependent, has a mesentery to its tip. The mesenteric lymph nodes and retroperitoneal lymph nodes along the vertebræ are small and pale in color. The stomach and intestines are contracted. The colon contains a moderate amount of gas. The diaphragm reaches to the fifth rib on the right, the fifth interspace on the left.

Pleural cavities: The lungs are voluminous, pale, and at the instant of opening bulge forth from the chest. They collapse upon handling. The left cavity is free from adhesions and liquid. The right lung is adherent to the chest wall at the apex by loose, tough fibrous tissue. No free liquid.

Pericardial cavity: Contains about forty cubic centimeters of clear pale-yellow liquid. Normal.

Heart: Contracted in systole. On removal, dark-red liquid blood escapes from the great vessels in great quantity. This blood clotted in a few minutes in the chest cavities. The heart is normal in size. The myocardium is deep brownish red, firm in consistency and on section is perfectly uniform. The valves and endocardium are normal. Just above the aortic valve, in the aorta, are a few small pale elevations of the intima two or three millimeters in diameter. None are calcified.

Lungs: Both lungs are voluminous. The alveoli along the borders remain distended with air after collapse of the lungs as a whole. The left lung is pale purplish-gray, with moderate anthracosis. The posterior border is dull red. The consistency of the whole lung is soft, crepitant. On section the cut surfaces are pale grayish-pink and dry, posterior border red, due to post-mortem settling.

Right lung: The apex is distorted by irregular bands of cicatricial tissue. Embedded in the upper part of the upper lobe, beneath the apex, are two hard masses, one 1.5 by one centimeter, the other two by one centimeter. These on section have hard, calcified walls one to two millimeters thick, and are filled with gritty, clay-colored plastic material. The adjacent lung tissue is soft, crepitant, but is deeply pigmented grayish to black. The remainder of the right lung is similar to the left lung. The bronchi of both lungs are slightly injected, pink, and contain a small amount of tenacious froth. The bronchial lymph nodes are small, soft, black, uniform on section.

Spleen: The spleen is greatly enlarged, measures 16 by 10 by 7 centimeters. The capsule is smooth, tense, the borders are rounded. The color is dark red, almost black. The consistency is resilient and firm. On section the cut surfaces are smooth, very dark red, almost black. The trabeculæ and Malpighian corpuscles are not visible. On scraping the cut surface dark-red blood is yielded.

Liver: Normal in size. The color is reddish brown. On section the lobular markings are visible with difficulty. The consistency is normal. The gall bladder and ducts are normal and contain transparent yellowish-green bile.

Gastro-intestinal tract: The stomach and intestines are contracted and almost empty of contents. On the posterior wall of the stomach is a red area, .4 centimeter in diameter in the mucosa, otherwise no lesions found in œsophagus stomach and intestines. The colon contains a few solid particles of feces and a moderate amount of gas. The mucosa is normal.

Pancreas: Normal in size, color and consistency.

Kidneys: Normal in size. The capsules strip easily from smooth surfaces. The cortices average .6 centimeter in width and are pale in color. The pyramids are moderately injected. Pelves and ureters normal. Adrenals normal in size, color and consistency. Bladder normal. Prostate slightly enlarged symmetrically; measures 3 by 3.5 centimeters; firm. On section, each lateral lobe contains several small, dense nodules .2 to .3 centimeter in diameter.

Testicles and scrotum: The subcutaneous tissues of the scrotum are deep red and wet. The parietal tunica vaginalis is injected. The surfaces of the epididymis are deeply injected, and the areolar tissues are deep red and wet. On section the testicles appear normal except for small injected areas beneath the tunica. The first portions of the spermatic cord are deeply injected.

Aorta: There are numerous small, pale-yellowish, smooth, slightly elevated areas scattered throughout the intima; none are calcified or of soft consistency. The caliber of the aorta is normal.

Organs of the neck, and mouth cavity: The trachea is moderately injected. Larynx and pharyngeal mucosa are normal. The tonsils are small; normal. The posterior part of the tongue is covered with a grayish layer; otherwise normal. Thyroid gland normal in size, color and consistency.

Peripheral lymph nodes: The lymph nodes of the axillæ are slightly injected, not enlarged. Those of the inguinal region are pale, wet and slightly enlarged. Those along the carotid vessels are slightly injected.

Bone marrow: From the femur is entirely fatty, yellow in color.

Head: The hair is short, white, sparse. The subcutaneous tissue of the scalp is finely injected and presents a dusky red tracery of minute vessels. The calvarium is normal. Dura and sinuses normal. The Pacchionian bodies are small.

Brain: The arachnoid encloses an excess of clear, colorless liquid. The vessels of the pia arachnoid are deeply injected, over the whole brain, most markedly over the vertex, and over the inferior surface of the pons and medulla, and over the

superior worm of the cerebellum. The sulci of the frontal lobes are wide and filled with clear fluid. There is no flattening of convolutions and the consistency of the brain is normal. Nothing abnormal found on section of the hemispheres, basal ganglia, pons, medulla and cerebellum. The ventricles contain clear fluid, are not dilated. The choroid plexuses are normal. Vessels at base of brain, normal. Sinuses at base of skull are normal.

Anatomical diagnoses. — Acute splenitis. Exanthem of skin, with rare subcutaneous extravasations of blood. Healed pulmonary tuberculosis. Acute epididymitis and periorchitis.

Spotted fever Case II. Microscopic description. Eosin-methylene-blue and Giemsa stains (Figs. 55, 60, 61, 62, 66, 67 and 68). — Heart: A section through left ventricle wall and base of anterior group of papillary muscles. There are a few areas of dense fibrous tissue in the ventricle wall, enclosing fibers in various stages of atrophy. In a band of conduction fibers beneath the endocardium is a small collection of polymorphonuclear leucocytes, with a few large mononuclear cells (endothelial cells) and mast cells, all lying between the muscle fibers which appear to be uninjured. Attached to the endocardium, between two muscle columns, is a small thrombus, composed of finely meshed fibrin enclosing many large mononuclear cells, some of which are phagocytic, polymorphonuclear leucocytes and lymphoid cells. The intima adjacent to and beneath this thrombus is infiltrated with large mononuclear cells (endothelial cells), lymphoid and plasma cells, and a rare polymorphonuclear leucocyte. The epicardium and the endocardium in a few places where there is no thrombus, is similarly infiltrated. There is a marked increase in the perinuclear pigment of the muscle fibers. The arteries of the myocardium show moderate arteriosclerosis, but no acute lesions.

Lung (Fig. 67): There is moderate injection with blood; no exudate. The bronchi are normal. The alveolar walls are everywhere slightly thicker than normal, due to a striking increase of cells in the capillaries and between the capillaries and respiratory epithelium. The majority of the infiltrating

cells are large mononuclear (endothelial cells), a few of which have taken up red blood corpuscles and other cells. In a few places about veins this infiltration is very marked, and there are in addition to the endothelial cells many polymorphonuclear leucocytes and an occasional mast cell. One section out of four shows a few small veins occluded with coarse-meshed fibrin enclosing polymorphonuclear leucocytes and mononuclear phagocytic cells (endothelial cells); the walls of these veins contain migrating leucocytes. One large vein contains a cluster of large mononuclear cells attached to the endothelium. No parasites are demonstrable in these lesions. The arteries show no lesions. The contents of arteries and veins include a large number of mononuclear (endothelial) phagocytic cells. There is a moderate amount of carbon pigment in the connective tissue around large bronchi. The cells of the respiratory epithelium, where the alveolar walls are most markedly thickened, are cuboidal in shape.

Spleen (Fig. 62): The spleen is tremendously engorged with blood, and there are small areas which appear simply as pools of blood, without structure of the spleen remaining. The absence of lymphoid cells in the reticular tissue of the pulp is very striking, and this tissue is filled with red blood corpuscles and mononuclear phagocytic (endothelial) cells containing red blood corpuscles, polymorphonuclear leucocytes and nuclear detritus. Some of these phagocytic cells contain six to a dozen red blood corpuscles in varying stages of disintegration. Similar phagocytic cells occur in great abundance in the sinuses (pulp veins) of the spleen, and in the smaller veins, free and attached to the walls. There are numerous miliary sized collections of polymorphonuclear leucocytes in the pulp, in regions where collections of phagocytic cells and sinus walls (pulp veins) are necrotic. There are a few large cells of the lymphocyte series and many polymorphonuclear leucocytes scattered throughout the pulp. The Malpighian bodies consist of small collections of lymphoid cells about the central arteries, and show no lesions. They contain no foreign cells and show no evidence of activity (or germinal centers). The arteries show moderate hyaline change and thickening. No

acute lesions can be found in arteries or veins. The capsule contains numerous migrating polymorphonuclear leucocytes. The peritoneal epithelium is swollen and cuboidal. Careful searching fails to reveal parasites of any sort in the spleen.

Liver (Fig. 61): The organ is moderately injected throughout and markedly injected about the central (hepatic) veins. There is slight fat vacuolation of the liver cells in the central portion of the lobules, i.e., adjacent to the hepatic veins. The sinusoids contain numerous large mononuclear phagocytic (endothelial) cells, a small proportion of which contain red blood corpuscles, polymorphonuclear leucocytes and nuclear material. The lining cells of the sinusoids (Küpffer cells) are swollen, and a few show mitoses; occasionally they contain red blood corpuscles and leucocytes. The liver cells contain an increased amount of greenish granular pigment. There are occasional minute necroses of the liver columns, usually involving one to a few liver cells and shown by a hyaline, deeply eosin-staining, cytoplasm, pycnotic nuclei and invasion by polymorphonuclear leucocytes. The portal spaces, bile ducts and arteries and veins show no lesions. The veins contain many mononuclear phagocytic cells like those found in the sinusoids.

Pancreas: There is a considerable increase of fibrous tissue in the acini, fairly uniformly distributed. The islands of Langerhans are normal. There are no acute lesions. The blood vessels show no lesions; they contain numerous mononuclear leucocytes, a few of which are phagocytic. The ducts are normal.

Stomach: Two blocks from the pyloric end were examined. The mucosa, submucosa and muscularis of both the blocks are normal. In the subserous connective tissue from one location is a small artery with a mural thrombus composed of fibrin, platelets, mononuclear phagocytic cells and a few polynuclear leucocytes. This thrombus is applied to about one fourth the circumference of the vessel. The wall of the artery is otherwise normal. No other vessel lesions are to be found.

Duodenum: One block examined. The duodenum shows no lesions. The blood vessels are normal. Jejunum: Two blocks examined. There are no lesions. The blood vessels are normal. Ileum: Three blocks examined. There are no lesions. The blood vessels are normal. Colon: Two blocks examined. There are no lesions. The blood vessels are normal.

Kidney: There are no acute lesions of the kidney or blood vessels. The kidney tissue shows a few areas of fibrosis containing sclerosed glomeruli. The arteries show slight arteriosclerotic changes. The veins, capillaries and glomerular capillaries are normal.

Adrenal: The adrenal and blood vessels and the surrounding fat and blood vessels are normal.

Thyroid gland: The thyroid follicles and their contents are normal. The stroma in general is normal. A few medium-sized veins and several small ones show acute lesions. The larger veins contain mural thrombi, consisting of a small amount of fibrin, numerous mononuclear phagocytic (endothelial) cells and polymorphonuclear leucocytes. The endothelium is swollen adjacent to the thrombi. The media is infiltrated with polymorphonuclear leucocytes. In the attached swollen endothelial cells, and in smooth muscle cells of the media, are numerous exceedingly minute paired and single organisms, usually surrounded by a clear space or halo. Some smaller veins and a few capillaries are completely occluded with mononuclear phagocytic cells and polymorphonuclear leucocytes. The walls are heavily infiltrated with polymorphonuclear leucocytes, as is the adjacent connective tissue. In the latter location there are numerous large mononuclear cells (endothelial cells), some of which are phagocytic. Similar minute parasites occur in the small veins. The largest forms of these parasites have tapering ends and have about one fourth the dimensions of the pneumococcus. The pairs measure slightly less than one micron in length, the estimated width is about one fourth of a micron.

Aorta: The aorta shows moderate arteriosclerotic changes. There are no acute lesions. The vasa vasorum show no lesions.

Lymph nodes: Axillary nodes; two examined. Both lymph nodes show packing of the lymph sinuses with large mononuclear phagocytic cells (endothelial cells), which contain red blood corpuscles, lymphoid cells, and a few polymorphonuclear leucocytes. The endothelium of the sinuses is swollen and a few cells *in situ* show phagocytosis of the cells named above. The sinuses contain also numerous polymorphonuclear leucocytes, a rare eosinophile and a few mast cells. The lymphoid tissue, i.e., secondary follicles and medullary cords, show no lesions. The blood vessels of the nodes and adjacent areolar tissue show no lesions.

Inguinal nodes: Two examined. The inguinal nodes are similar to the axillary, though the endothelial cell reaction is more marked, as there are very many phagocytic cells in the medullary cords. The secondary follicles are small and irregular in shape.

Bronchial nodes: Two examined. These nodes show marked carbon pigmentation and small numbers of phagocytic cells in the sinuses, otherwise they are negative. The blood vessels of the surrounding areolar tissue show no lesions.

Mesenteric nodes: Five examined. The sinuses are packed with phagocytic cells similar to those of the peripheral lymph nodes. A rare sinus is filled with necrotic phagocytic cells and polymorphonuclear leucocytes. A small vein in the medulla of one lymph node contains a thrombus. A few of the secondary follicles in all nodes contain small central whorls of large flattened mononuclear cells in which are a few polymorphonuclear leucocytes.

Testis and epididymis: A section through body of testis, tunica albuginea and visceral tunica vaginalis. The seminiferous tubules are normal and show spermatogenesis. The tunica albuginea and tunica vaginalis are normal. There are striking lesions of large and small-sized blood vessels, arteries and veins, and a few œdematous and infiltrated areas of the interstitial tissues, in the substance of the testis. There are a few small areas of completely fibrosed seminiferous tubules surrounded by normal interstitial tissue. The lesions of arteries and veins vary from minute foci of swelling of the

endothelium, forming groups of a few cells to mural thrombi with extensive infiltration of the vessel wall with polymorphonuclear leucocytes. In the arteries small lesions consist of a collection of swollen endothelial cells, overlying a fragmented internal elastic lamina, beneath which are endothelial cells (large mononuclear cells) and polymorphonuclear leucocytes. Large lesions are covered with fibrin, in which are endothelial cells and polymorphonuclear leucocytes, overlying the internal elastic lamina which is usually fragmented and deeply stained with the basic stain. The media is infiltrated with large mononuclear cells, and polymorphonuclear leucocytes. In large mononuclear cells and in smooth muscle fibers are large numbers of minute paired round and ovoid bodies, which stain blue with the Giemsa stain. These bodies are usually surrounded by a clear zone or halo. The length of the largest pairs of ovoid forms is slightly less than one micron, while the estimated width is less than .25 micron. The packing of these parasites in smooth muscle cells is strikingly seen in tangential sections of affected arteries and veins where occasional cells are almost completely filled with them. In such instances, the nucleus of the smooth muscle cell stains deeply and homogeneously; the cytoplasm occasionally shows hyaline change. These parasites are also found in large numbers in endothelial cells lying just beneath the internal elastic lamina or in the fibrin above. They are also found in small numbers in the endothelium of the whole circumference of the vessels, and in the endothelium of vessels showing no reaction other than a slight swelling of the endothelium itself. Small veins and capillaries are occasionally found completely occluded by fibrin and mononuclear (endothelial) cells and polymorphonuclear leucocytes. Such vessels are surrounded by collections of mononuclear phagocytic cells (endothelial cells) in which are numerous polymorphonuclear leucocytes. The minute paired organisms are also found in these lesions, both within the lumen of the vessel and in endothelial cells in the perivascular zone of infiltration. Occasional, apparently normal capillaries contain a few pairs of the organisms in the lining endothelium.

Sections through the testis and epididymis. Four blocks examined. The testis shows vascular lesions as described above. The seminiferous tubules, tubules of the rete, the efferent ducts of the testis and the ducts of the epididymis are all normal. There is considerable œdema of the connective tissue of the epididymis; and between the separated connective tissue bundles are occasional meshworks of delicate fibrin strands, lymphoid cells, plasma cells and large mononuclear cells, some of which are phagocytic. The arteries and veins of the epididymis (tunica albuginea) show thromboses and endothelial cell proliferations as described in the testis.

Sections through the testis, pampiniform plexus and ductus deferens. Two blocks examined. The testis and its blood vessels are similar to the other sections. The ductus deferens shows no lesions. Arteries and veins of the plexus of all calibers show lesions of the intima and mural thrombosis, the minute paired organisms described are invariably present in the vessels showing lesions. In large veins there are collections of endothelial cells beneath the lining endothelium, the latter forming loops to enclose the cell groups. Some veins of medium size are nearly completely occluded by these cells. In vessels cut longitudinally showing this reaction, there are always small fibrin thrombi at some level; the minute parasites are found in these vessels in endothelial cells chiefly. The lymphatics of the epididymis and the plexus show no lesions; a few contain fair numbers of phagocytic mononuclear (endothelial) cells.

Section through the ductus deferens, epididymis and pampiniform plexus. Four blocks examined. These sections all exhibit the same extensive lesions of the blood vessels and constant presence of the minute parasite.

Prostate gland: The glands show considerable hyperplasia. There are no acute lesions. The blood vessels show no acute lesions. Bladder: Normal. The blood vessels are normal.

Brain: Cerebral cortex. Blocks from the frontal, paracentral, occipital and temporal regions were preserved. The pia arachnoid in all the above regions shows evidences of

œdema in the wide separation of the connective tissue fibers and in the presence of a few lymphoid cells, and a rare polymorphonuclear leucocyte, red blood corpuscle and amœboid phagocytic cells. The brain cortex and vessels show no lesions. The vessels are markedly injected with blood. Single veins in each of two regions — paracentral and occipital — show minute lesions of the intima in the form of collections of mononuclear cells (endothelial cells) a few of which are phagocytic and polymorphonuclear leucocytes on the surface of the intima and in the wall of the vessel.

Cerebellum: Two blocks examined; in one a single small artery shows a minute lesion — a thin deposit of fibrin and a few endothelial cells attached to the intima, in which are a few pairs of the minute organism. The cerebellar tissue is free from lesions. The blood vessels of the substance of the cerebellum show no lesions. The meninges are normal.

Medulla and pons: Sections through the medulla and floor of fourth ventricle show no lesions of nerve tissue or blood vessels. A section through the pons and meninges shows no lesions of blood vessels or nervous tissue.

Skin (Figs. 60, 66 and 68): Blocks were taken from the skin of the neck (tick bite), axilla (tick bite), arm, abdomen, back, buttock, thigh, legs and ankles.

Skin of neck, including tick bite; subcutaneous fat and muscle: The epidermis is missing over the lesion of the tick bite, where there is a fibrinous crust several millimeters long. The corium projects above the level of the epidermis and is completely necrotic in an irregular but sharply delineated area, which consists of bundles of hyaline collagen fibrils and basic staining elastic fibers widely separated by necrotic cells and detritus. The necrotic area is several millimeters long and extends downwards for about half the thickness of the skin. At the periphery of the necrotic area there is a small amount of fibrin and numbers of red blood corpuscles between the collagen bundles, as well as many polymorphonuclear leucocytes and a few mononuclear phagocytic cells (endothelial cells). Running into the necrotic area are several thrombosed necrotic walled arteries and veins, while surrounding adjacent

coil glands there are heavy zones of lymphoid and plasma cell infiltration in which are numerous large mononuclear cells, some of them phagocytic.

The epidermis shows no change, except at the edge of the tick bite, where it is thinned, as with any ulceration of the skin. The corium everywhere contains a few wandering cells, mostly large mononuclear amœboid cells, many containing brown, granular pigment. The blood vessels of the corium, subcutaneous tissue and muscle show striking changes, in the form of lesions of the intima, and thrombosis. Many of the papillary capillaries are occluded by polymorphonuclear leucocytes and mononuclear phagocytic cells (endothelial cells), and are surrounded by zones of large mononuclear cells and polymorphonuclear leucocytes.

Capillaries about the coil glands show similar lesions and perivascular infiltrations. Arteries and veins show lesions similar to those described in testis and pampiniform plexus, in corium, subcutaneous fat and muscle. The mural thrombi are most marked in the larger size arteries of the lower layer of the corium and subcutaneous tissue. Many fat cells in the subcutaneous fat lobules are shrunken, filled with granular material and surrounded by a layer of cuboidal epithelioid cells (endothelial cells), or narrow, crescentic multinuclear cells (giant cells). Between the fat cells are many similar cells and a few cells undergoing mitoses. The minute paired organisms described in lesions of other blood vessels occur in this region in capillaries with swollen endothelium, and in vessel walls with lesions within smooth muscle cells and endothelial cells.

Skin of axilla with tick bite: These sections present identical lesions with those from the neck.

Skin of arms: The epidermis, coil glands, sebaceous glands and hair follicles are normal. There are a few arteries and veins in the deeper layer of the corium, with mural thrombi and infiltrated walls. Numerous capillaries of the papillæ and vessels of the subpapillary plexus are filled with mononuclear cells (endothelial cells), and surrounded by zones of similar cells. Parasites are present in the vessel lesions as in the other sections.

Skin of abdomen: The papillary capillaries are practically normal; they contain numerous large mononuclear cells. The epidermis and appendages are normal. A single large artery just below the corium is almost completely occluded by a coarse-meshed hyaline fibrin thrombus, which has left a small eccentrically situated lumen, in part bounded by the vessel wall. The whole wall of the artery is infiltrated with polymorphonuclear leucocytes. The muscle fibers of the media in a small area are necrotic and the fibrin strands of the thrombus are continuous with fibrin in the media. The thrombus contains but few cells, polymorphonuclear leucocytes and large mononuclear phagocytic cells (endothelial cells). The endothelium of the artery is not distinguishable, as the hyaline fibrin lies upon the elastica or extends beneath it. Surrounding the artery in the adventitia is a zone of large mononuclear phagocytic cells and polymorphonuclear leucocytes with a small amount of fibrin. In the subcutaneous fat are several smaller vessels showing less advanced lesions. The minute parasite is present in small numbers in all the affected vessels.

Skin of thigh: There are lesions of the subcutaneous arteries with mural thrombi and occluding thrombi. The minute parasites are present in the vessel walls. The capillaries of the skin show slight lesions only.

Skin of buttock: The lesions of the deeper arteries of corium and subcutaneous fat are identical with those from the thigh.

Skin of leg and ankle: There are numerous thrombosed arteries in the subcutaneous tissue. The capillaries of the corium show lesions similar to those described above. In one section of skin from the leg there is hemorrhage into several fat lobules. The parasites are present as in the lesions from other locations.

Skin of scrotum: There is a more uniform involvement of the blood vessels of the skin and dartos than in skin from any other location. Vessels of all calibers are the seat of acute lesions and thromboses. There are many small arteries and veins showing early thromboses with enormous numbers of the minute parasites in smooth muscle fibers and n endothelial cells. The lesions vary in size and age, and

conform to the lesions of the vessels of the pampiniform plexus, testicle and epididymis. The epidermis in a few places shows a heaping-up of the horny layer and thinning of underlying layers over lesions of the corium consisting of œdematous areas containing much finely granular material and large numbers of closely packed cells, mononuclear leucocytes, and lymphoid cells. In such areas are capillaries occluded with large mononuclear cells and polymorphonuclear leucocytes and fibrin. These areas suggest beginning necrosis of the skin.

Fat stain. Scharlach R. — Heart: No fat. A large amount of lipochrome perinuclear pigment. Spleen: No fat. Liver: Small amount of fat about centers of lobular, i.e., hepatic veins, in small droplets. Kidneys: An occasional convoluted tubule contains numerous small fat drops. Adrenal: Contains much less than normal amount of lipoid material, the greater portions contain only an occasional droplet, but here and there in the fascicular zone are areas of dense red coloration due to cells packed with lipoid droplets.

Case III. — The clinical data on this case are meager; it is that of a Finnish laborer, 31 years old, who worked in the vicinity of Darby, Mont., in the southern (upper) end of the Bitter Root Valley. He was unable to speak English, but his illness was noticed first on May 12. The week previous, while at Darby, three ticks were known to have been attached on his leg and thigh. His first complaints were those of fever and aches. He was nauseated and vomited the day before admission to the Thornton Hospital at Stevensville, Mont.

He had a fine, punctate, erythematous rash all over his body when admitted the evening of May 17, five days after the onset. The rash on May 18 was most marked on the ankles, legs and buttocks. On the evening of May 18 he became delirious and developed a cough without sputum. On May 19 the rash was more pronounced but still disappeared upon pressure. A distinct yellowish cast to the skin appeared. The tongue was swollen, dry, bright red at the edges, with a heavy white coating over the middle and posterior portions. A transfusion of 450 c.c. of citrated blood was given from an immune donor.

On May 20, in the early morning, he became unconscious. The skin was now of a distinct yellowish color, and was mottled dull red over the whole body. These dull red areas increased in size during the day and ranged from a few centimeters to areas 10 x 25 cm. in diameter over the lower portions of the thighs. On stroking these areas with the fingernail the dusky lividity blanched after an interval of about five seconds, leaving a broad pale-yellow line in which the papillæ became slowly erect.

This condition persisted for about a minute. During the day deep-seated red spots 1 to 2 mm. in diameter, which did not disappear upon pressure, appeared on the elbows and buttocks. The pulse became very rapid and feeble, the respirations rapid, and the death occurred at 8.40 P.M.

Differential blood counts made in the sixth and seventh days of the disease are recorded on page 32.

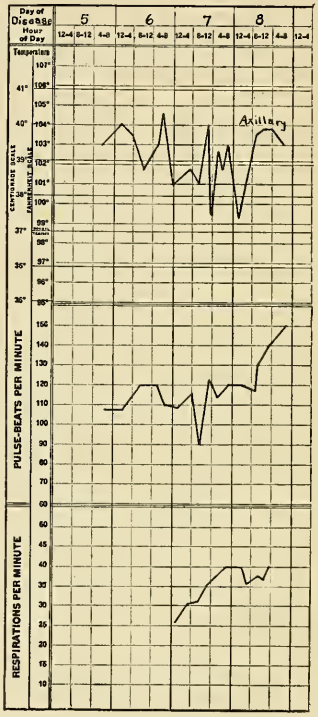

Charts of temperature, pulse and respiration of Case III. Male, age 31 years. Death on eighth day of disease.

Two guinea-pigs were inoculated May 18, one with one cubic centimeter, the other with two cubic centimeters of blood in citrate saline solution. Both developed the typical temperatures and lesions of spotted fever, and upon these guinea-pigs ticks were fed which afterwards, in Boston, communicated the disease to another guinea-pig. See record of Ticks XXXIII. and XXXIV., page 96.

Autopsy. Spotted fever Case III. Hamilton, Mont., May 20, 1917, at 9.30 P.M. (By tungsten light.) One hour post-mortem.

Body: Is that of a well-developed, muscular, well-nourished white man about 165 centimeters long. Rigor mortis is beginning in arms and legs. Body heat present. The skin everywhere is dusky reddish-yellow in color, and is mottled with large, irregular areas of deeper dull red. Over the lower legs, arms, chest and thighs a fine red rash is present, which disappears on pressure. The back and buttocks are bright red in color, due to post-mortem lividity(?). The buttocks are mottled with deep red-colored areas, which do not disappear upon pressure, .2 to .5 centimeter in diameter. The lower part of the right half of the scrotum is deep red in color. There is no œdema. The pupils are equal, .2 centimeter in diameter. The scleræ are deeply injected. Cornea clear and firm. On incision through the skin over the chest, back, thighs, abdomen, legs and ankles the subcutaneous fat is found injected with blood in small areas, and there are occasional small areas of fat which are colored reddish. The fascia lata and the tendon sheaths of the ankles are injected, and the overlying tissues of each are yellowish in color and contain free liquid (œdema).

Peritoneal cavity: The peritoneal surfaces are everywhere smooth, moist, glistening; there is no free liquid. No adhesions. The appendix is normal. The mesenteric lymph nodes are small, pale in color, normal in consistency.

Chest cavities: Inspected through the diaphragm. The left lung along the outer border of the lower lobe is adherent to the chest wall by loose, tough fibrous tissue. The right lung is free from adhesions. No free liquid in either cavity.

Pericardial cavity: Normal. No excess of liquid or exudate.

Heart: The left ventricle is contracted. The right ventricle is patulous, and the heart contains a few small, soft cruor clots and dark red liquid blood. The heart is normal in size. The valves and endocardium are normal. There are a few yellowish areas, found on section, in the myocardium,

particularly in the interventricular septum along the left border and adjacent wall of the left ventricle.

Lungs: Both lungs are voluminous, pink, with considerable black pigment distributed beneath the pleura in the interlobular septa. Both lungs are soft, crepitant throughout. On section the cut surfaces are dry; the vessels yield considerable dark red fluid blood.

Spleen: The spleen is markedly enlarged, size 10 by 8 by 6 centimeters. The edges are rounded. The capsule is tense, color dark bluish-red. On section the cut surfaces are very dark red. The trabeculæ and splenic corpuscles are not visible. The cut surfaces are firm, and yield blood on scraping. The consistency is firm, resilient.

Liver: Normal in size; estimated weight, 1600 grams. The color is brownish-red. Consistency normal. On section the lobules are faintly indicated by a paler reddish tracery. Gall bladder and ducts negative.

Gastro-intestinal tract: The stomach is contracted. The mucosa is flecked with small particles of brown granular material, free on the surface, and is considerably injected. The small intestines and colon are normal in appearance.

Pancreas: Normal in size, color and consistency.

Kidneys: Normal in size. Estimated weight, 300 grams. There is pronounced fœtal lobulation of both. In the outer surface of the right kidney is a cysto e centimeter in diameter, filled with clear, colorless liquid. The cortex averages .6 to .7 centimeter in width, and is grayish-red in color. The glomeruli are visible as colorless points. The pyramids are brownish-red in color, normal in appearance.

Adrenal glands: Normal in size, color and consistency, except for a few small bright yellow nodules two or three millimeters in diameter in the cortex of the left adrenal.

Genitalia: The subcutaneous tissues of the scrotum are wet and deeply injected, and in the right side there are areas of dark red, due to extravasation of blood. The testes are moderately injected, the epididymis swollen, wet and deeply injected. Testes on section are normal in appearance. The epididymes show dark red punctate areas.

Inguinal lymph nodes: Are large, the largest measuring 1.5 by 1 by .5 centimeters. All are purplish-gray and firm.

Anatomical diagnoses. — Generalized subcutaneous extravasations of blood. Hematogenous pigmentation of the skin. Acute splenitis. Acute epididymitis.

Spotted fever Case III. Microscopic description. Eosin-methylene-blue and Giemsa stains. — Heart: A section through the base of the anterior group of papillary muscles and ventricle wall. The muscle fibers of the ventricle wall show nothing abnormal. The fibers of the papillary muscle show in places a delicate vacuolization. There are also a few small groups of large amœboid mononuclear cells and lymphocytes between muscle fibers, or grouped about capillaries. The blood vessels, including those of the pericardium, show no change. The endocardium shows nothing abnormal.

Lungs: There is moderate injection of the blood vessels, no exudate. In the blood vessels, and in the alveolar walls, are large numbers of large mononuclear cells (endothelial cells), a few of which contain red blood corpuscles and nuclear detritus. There are no lesions of the blood-vessel walls. The respiratory epithelium in a few places is replaced by a cuboidal type of cell. There are a few areas of marked carbon pigmentation about large blood vessels and adjacent to the bronchi, accompanied by the usual fibrosis. The bronchi are free from exudation. In the larger bronchi the epithelium contains a considerable amount of coarsely granular greenish pigment, situated in the distal side of the nuclei in the cells.

Spleen: The spleen is tremendously engorged with blood, with small areas of hemorrhage into the pulp. The splenic corpuscles are small, in many instances being mere fringes of lymphoid cells around the central vessels. They contain few mitotic cells, and cells of the germinal center type are almost wholly absent. The central vessels are normal, and there is no exudate or collection of large cells such as occur in diphtheria and other toxic diseases. The splenic pulp has undergone striking changes. The lymphoid cells in the reticular tissue have almost wholly disappeared; in their places are

red blood corpuscles, polymorphonuclear leucocytes, and large mononuclear phagocytic cells (endothelial cells), many filled to distention with red blood corpuscles, others containing in addition lymphoid cells, polymorphonuclear leucocytes and densely staining nuclear remains. The polymorphonuclear leucocytes in a few areas appear in excess of other cells, but in general the predominating cells are red blood corpuscles and the phagocytic cells. The sinuses contain a large number of phagocytic cells (endothelial cells), similar to those in the reticular tissue, and many swollen cells attached to the sinus walls contain red blood corpuscles, chromatin detritus and polynuclear leucocytes. The veins contain many phagocytic cells similar to those described. The walls of arteries and veins show no lesions. The connective-tissue structures, i.e., trabeculæ and capsule, show no lesions. The peritoneal cells on the surface of the spleen are swollen and cuboidal in shape.

Liver: The sinusoids and larger blood vessels contain only a small amount of blood. The liver cells show slight fat vacuolization at the periphery of the lobules. There are occasional minute focal necroses involving single or very small groups of liver cells, evidenced by a change in staining to a deep eosin color of the cells, loss of nuclei and invasion by polymorphonuclear leucocytes. A single large area of necrosis, involving an area about one fourth the radius of a lobule, was found. In this area the liver columns are completely disorganized and there are many polymorphonuclear leucocytes and large phagocytic cells (endothelial cells), containing red blood cells and nuclear detritus. The liver cells in general are normal in appearance; a few show considerable brownish granular pigment. The sinusoids contain many mononuclear phagocytic cells (endothelial cells), mostly containing red blood cells, a few polymorphonuclear leucocytes and chromatin particles. The lining cells of the sinusoids (Küpffer cells) in many places are swollen, and contain red blood corpuscles and nuclear detritus; these cells often show several processes when situated at the forking of columns of liver cells. The larger blood vessels are normal. The

branches of the portal veins contain phagocytic cells (endothelial cells) in numbers almost equal to those in the veins of the spleen. The bile passages are normal. The connective tissue of the portal spaces contains a few polymorphonuclear leucocytes, and an occasional branch of a portal vein shows polymorphonuclear leucocytes migrating through their walls. The arteries and veins show no lesions. The capsule and peritoneum show no lesions.

Pancreas: The pancreas and its blood vessels are normal. Adjacent fat tissues and blood vessels are normal. The larger veins of the pancreas contain numerous mononuclear phagocytic cells (endothelial cells) similar to those in the vessels of liver and spleen. Sections of the pancreatic artery show no lesions.

Stomach: Three blocks examined. The blood vessels of the submucosa are markedly injected. The mucosa is normal except for an occasional capillary distended with polymorphonuclear leucocytes and phagocytic mononuclear (endothelial) cells. An occasional lymphoid follicle contains many polymorphonuclear leucocytes. One small vein, traversing the muscularis mucosæ, contains a small mural thrombus composed of granular material, polymorphonuclear leucocytes and endothelial cells. The vein wall at this point is infiltrated with polymorphonuclear leucocytes. A few small arteries in the submucosa show the earliest possible signs of a reaction, swollen endothelium and an occasional polymorphonuclear leucocyte in the wall. In several such arteries minute paired and single oval microörganisms can be seen (Giemsa stain) lying beneath the internal elastic lamina, and in the endothelium. Those lesions in the vessels would easily escape notice unless specifically looked for. The muscularis and serosa are normal.

Small intestine, jejunum, and upper part of ileum: Four blocks examined. No lesions of the small intestine and their blood vessels can be found. A few veins in the submucosa of the jejunum contain large numbers of large mononuclear leucocytes, a few of which are phagocytic and contain red blood cells and nuclear remains.

Kidney: There is marked injection with blood. A few glomeruli show accumulations of large mononuclear, occasionally phagocytic (endothelial) cells in the capillaries; there are also occasional polymorphonuclear leucocytes in these collections of cells. The capsular spaces contain small amounts of granular material. The tubules throughout the sections show slight dilatation and contain circular reticulum and granular detritus. Many collection tubules contain coarsely granular casts. The blood vessels show no lesions.

Adrenal: There is but little vacuolization of the cells of all zones. In the reticular zone, the cells of which stain solidly for the most part, there are abrupt transitions to greatly vacuolated cells which are separated from one another. In a few such areas there are many polymorphonuclear leucocytes, and a rare phagocytic mononuclear cell (endothelial cell), while the adrenal cells show evidence of necrosis in staining reactions and by invasion with leucocytes. In the medulla there are a few areas of lymphoid and plasma cell infiltration. The blood vessels show no lesions. Superior mesenteric artery: A cross section taken near its origin shows no lesions.

Lymph nodes: Inguinal nodes; three examined. The sinuses are filled with large mononuclear cells (endothelial cells), many of which are phagocytic and contain red blood corpuscles, lymphoid cells and nuclear detritus. The secondary follicles are small, distinguishable with difficulty from the medullary cords; a few show central collections of large mononuclear cells; some are flattened and concentrically arranged, others are rounded and phagocytic. Such groups contain numerous polymorphonuclear leucocytes. The medullary cords contain a few phagocytic cells and eosinophiles. The blood vessels show no lesions.

Mesenteric nodes: The mesenteric node is similar to the inguinal nodes in the presence of phagocytic mononuclear cells in the sinuses; they are, however, less numerous, and there are fewer red blood corpuscles free or within cells.

Retroperitoneal nodes — from the region of the cœliac axis: The sinuses are greatly distended, and filled with many mononuclear phagocytic cells (endothelial cells), numerous

red blood corpuscles and lymphoid cells, a few polymorphonuclear leucocytes and an occasional mononuclear eosinophile. Many of the phagocytic cells contain one to several red blood cells, brownish pigment, and often lymphoid cells and polymorphonuclear leucocytes. Large cells attached to the sinus walls are also phagocytic for the above elements. There is a small amount of brown granular pigment in the medullary cords, within cells.

Skeletal muscle from the thigh: A few muscle fibers show hyaline change and loss of striations comparable to those in typhoid. In a few fibers the hyaline change is sharply delineated by a transverse fracture, possibly artefact. The nuclei of the sarcolemma show no change. There is moderate œdema and infiltration of the connective tissue accompanying blood vessels (internal perimysium), and marked lesions of many blood vessels of all sizes, some of which are completely thrombosed. The smallest lesions of the vessels consist of groups of endothelial cells attached to the intima. In arteries such groups overlie swollen and fragmented portions of the internal elastic lamina, and the media is usually infiltrated with polymorphonuclear leucocytes and large mononuclear amœboid cells (endothelial cells). The muscle fibers of the media adjacent to the lesion of the intima are swollen, and in small arteries swollen fibers are found throughout the circumference. In these swollen arteries, in endothelial cells, and occasionally lying apparently free above and below the elastica, are large numbers of minute paired ovoid organisms. Occasionally, spherical masses of the organisms occur, as if completely filling an endothelial cell, while smooth muscle fibers are often completely filled with them. These organisms are surrounded each by a clear zone or halo, and when in compact masses seem to be embedded in reddish staining material (Giemsa stain). The largest pairs show tapering of the distal ends, and measure slightly less than one micron in length for the pair. The estimated width (with micrometer ocular) is about one fourth of a micron. The lesions in veins are similar to those in arteries; endothelial cell proliferation, degeneration of the intima and infiltration of the media.

In vessels apparently normal, high power examination reveals swollen endothelial cells of the intima enclosing the organisms described. More advanced lesions consist of fibrin deposits which occur as mural thrombi, or as occluding thrombi, according to the extent of the lesion of the vessel wall. Small-sized veins and capillaries are completely occluded by packed masses of phagocytic cells (enclosing red blood corpuscles, polymorphonuclear leucocytes and nuclear detritus) and polymorphonuclear leucocytes. Surrounding small vessels with lesions there are zones of large mononuclear cells (endothelial), some of which are phagocytic and polymorphonuclear leucocytes. Small dilated veins often contain many phagocytic endothelial cells, free in the lumen, and rarely these cells contain one or several pairs of the minute organisms. The œdematous connective tissue septæ contain a few large mononuclear cells, some phagocytic, some amœboid, and a rare mast cell.

Testis, epididymis, and pampiniform plexus (Figs. 51, 58 and 63): (1) Section through testis and epididymis. The testis shows no lesions of the seminiferous tubules or interstitial tissue. The former are actively spermatogenic. There are no large blood vessels in the sections. A few small arteries and veins show swollen endothelial cells and polymorphonuclear leucocytes in the walls. These lesions would escape notice unless specifically searched for. The swollen endothelium contains numerous pairs of organisms like those found in the vessels of the muscle. The tubules of the epididymis and the ductus deferens show no lesions. The blood vessels of the tunica albuginea and pampiniform plexus show widely distributed and very striking lesions, in arteries, veins and capillaries. These lesions vary from small clusters of large mononuclear cells attached to the intima and accompanied by infiltration of the media with polymorphonuclear leucocytes, to large mural thrombi of fibrin and cells overlying extensive necrosis of the media. In medium-sized veins there are festoon-like loops of the vascular endothelium, enclosing large phagocytic mononuclear cells and polymorphonuclear leucocytes and occasionally necrotic phagocytic cells, and

small masses of fibrin. Frequently the whole circumference of the vein is festooned with such accumulations of cells beneath the endothelium. The cells of the latter are swollen, and often contain pairs of the minute organisms. In capillaries there is marked thickening of the endothelium and filling of the lumen with large mononuclear phagocytic cells and polymorphonuclear leucocytes. Surrounding these capillaries are zones of large mononuclear cells (epithelioid in appearance). In these large mononuclear cells (endothelial cells) there are numerous minute paired organisms and smaller barely visible round forms. In the arteries the internal elastic lamina seems to form the center of the lesions. The smallest lesions consist of collections of endothelial cells overlying a fragmented and basic staining portion of the elastica, while externally (in the media) there may appear a few polymorphonuclear leucocytes. Large lesions show deposits of fibrin internally to and occasionally externally to the elastica. The fibrin in the lumen of the vessels is coarsely meshed and contains large mononuclear phagocytic cells and polymorphonuclear leucocytes, large mononuclear cells and a rare degenerated muscle fiber, shown by pycnotic nucleus and hyaline cytoplasm. In arteries showing slight lesions, there are festoon-like projections of endothelial cells similar to those in veins, while in other places the endothelium is thickened or absent. The minute paired organisms occur in greatest abundance in the arteries, packed in smooth muscle cells, some of which show hyaline change, in large mononuclear cells (endothelial cells) in the media, attached to the intima, and in the fibrin meshes of the thrombi. They also occur apparently free beneath the elastica, and in slightly swollen endothelial cells in regions otherwise normal. The packing of the organisms in smooth muscle cells is best seen in longitudinal sections of the cells in tangentially cut arteries. (2) Six different blocks, four of epididymis and two of ductus deferens, with pampiniform plexus. All of these slides show the same characteristic extensive lesions of blood vessels, while the tubules and ducts show no lesions. In one slide of the pampiniform plexus an artery is cut longitudinally,

and shows the entire intima elevated and enclosing clusters of large mononuclear phagocytic cells and polymorphonuclear leucocytes. Here and there are small mural fibrinous thrombi, the smallest of which can be seen to have taken origin upon necrotic phagocytic mononuclear cells. In the necrotic cells and adjacent to them there are always many of the minute paired organisms.

Skin (Fig. 70): Blocks from axilla, arms, abdomen, back, buttocks, thigh and leg were saved.

Arm and axilla: Arteries and veins in the subcutaneous fat and in the deeper layers of the corium show lesions of the intima with and without mural thrombi of fibrin, such as have been described in connection with the epididymis and pampiniform plexus. The papillary capillaries and the vessels of the subpapillary plexus show plugging with mononuclear phagocytic cells (endothelial cells), and polymorphonuclear leucocytes, and are surrounded by zones of similar cells and occasionally small areas of hemorrhage. Some of the capillaries and veins contain fibrin as well. The hemorrhages are most common about the vessels of the subpapillary plexus; they occur also about small veins in the deeper layers of the corium and in the subcutaneous fat lobules. In many instances vessels are found which are completely filled with large mononuclear cells, some containing red blood corpuscles, others polymorphonuclear leucocytes, while some are not phagocytic. The capillary network about the coil glands is usually the seat of similar lesions. Small arteries and veins with swollen endothelium, and one or two large cells (endothelial cells) attached to one point where there is a trace of fibrin upon the intima, are common. The minute parasites are constantly present in the lesions of arteries and veins in smooth muscle cells and in endothelial cells. These are more difficult to find in the plugged capillaries because of the abundant granular material derived from degenerated cells, but they can be invariably found within endothelial cells. The epidermis is normal, except for minute areas over papillæ with plugged capillaries and hemorrhage. In these locations the

epidermis is œdematous and infiltrated with polymorphonuclear leucocytes and occasionally is capped with an adherent clump of keratinized cells. A rare nerve trunk shows œdema and infiltration with polymorphonuclear leucocytes and mast cells; the latter are the more common. The subcutaneous fat shows a few areas of hemorrhage, while there are many places which are infiltrated with large mononuclear cells (endothelial cells), phagocytic for red blood corpuscles and other cells. The coil glands where the capillaries are plugged show marked swelling and vacuolization of the secretory cells; a few are infiltrated with polymorphonuclear leucocytes. The ducts are free from lesions.

Abdomen: The lesions are similar to those in the skin elsewhere but less marked, and there are no hemorrhages into the corium. The parasites are present in the lesions.

Thigh and leg: The character and extent of the lesions are similar to those in the skin from the arm. The parasites are present in the lesions.

Buttocks: The character of the lesions is similar to those elsewhere in the skin, but there is more extensive involvement of the papillary capillaries, and subpapillary vessels, and small necrotic foci in the corium occur around thrombosed vessels of small caliber. These foci are filled with large mononuclear phagocytic cells (endothelial cells). Small areas of hemorrhage are likewise more frequent in the papillæ, and there are occasionally minute necroses of the overlying epidermis. The parasites are present as in the other lesions.

Scrotum: Similar lesions of blood vessels of all sizes with presence of the parasite are found in the skin and dartos.

Scharlach R. stain. — Heart: There are large areas of fibers showing marked fat deposits in minute droplets, sufficient to give pink color to the fiber with low power. These areas are scattered throughout the thickness of the myocardium. There is moderate amount of perinuclear lipochrome. Spleen: No fat. Liver: Almost devoid of fat. A narrow zone of fat containing liver cells is found about the portal spaces.

The fat is in small droplets. Kidney: An occasional convoluted tubule contains a few small droplets of fat in the epithelial cells. Adrenal: The middle portion of the fascicular zone contains considerable lipoid material. The glomerular zone contains scattered groups of cells with lipoid droplets.

Case IV. — This case was that of a young male adult, a laboratory technician who presumably accidentally introduced the virus of Rocky Mountain spotted fever into his body eight days before the onset of symptoms, while making inoculations from guinea-pigs to guinea-pigs. His symptoms began eight days before death, with the onset of a sudden fever, intermittent headache occurring every two or three minutes, with remissions of the same duration. He had muscle pains in both thighs, was constipated and feverish. There was a slight cough with no sputum. The day following, seven days before death, he had a chill and noticed a rash which appeared first on his forearms.

On examination six days before death there was an "erythematous maculo-papular eruption over the upper extremities, the front and back of the chest and slightly on the palms of the hands and soles of the feet. The superficial lymph nodes were palpable throughout, but not greatly enlarged." There was an ankle clonus. The spleen was not palpable. The temperature was 104° F.

Shortly afterwards a slight conjunctivitis and puffiness of the face appeared. The eruption extended over the legs and feet and appeared in the mucous membrane of the mouth. Two days before death the eruption became petechial and the glandular enlargement more marked. The tongue became dry and brown. The pulse and respirations became rapid and a slight rigidity of the neck appeared the day before death.

Blood cultures during life were negative. The diagnosis of Rocky Mountain spotted fever was confirmed by guinea-pig inoculations.

An autopsy was made two hours after death. Rigor mortis was slight at the beginning of the autopsy, but complete when it was finished. The rash remained visible after death, but the erythematous eruption largely disappeared during the autopsy. Punctate hemorrhages into the skin were found most marked on the right side, on the abdomen, chest, thighs, shoulders and arms; a few were found on the palmar surface of the fingers and hands. The petechiæ were also found on the fornices of the conjunctivæ, mucosa of the hard palate and lip and on the glans penis. The skin of the scrotum was thick, red and desquamating.

The abdominal cavity contained about two hundred cubic centimeters of liquid blood, which came from a rupture at the lower pole of the spleen. The cavities of the chest were normal. The heart and lungs were normal. The spleen weighed seven hundred grams, was soft in consistency and bluish-red in color. "At its lower anterior pole there is a point of spontaneous rupture to which is attached a blood clot about the size of a hen's egg." On section the normal structures were barely visible, and the pulp was diffluent.

The liver weighed nineteen hundred grams and was not remarkable in appearance. The pancreas, kidneys, adrenal glands and gastro-intestinal tract were normal in appearance. The aorta was normal. The testes were not remarkable in appearance. The tunica vaginalis was normal. On section both testes showed a marked injection, but no hemorrhages. The thyroid and skeletal muscles were normal. The bone marrow (humerus) was red.

Spotted fever Case IV. Microscopic description. Eosin-methylene-blue and Giemsa stains. (Fig. 44.) Heart: There are three sections, including one through the base of a large papillary muscle. All show very slight œdema, but otherwise normal. The pericardium is normal. The blood vessels are normal.

Spleen: Very intensely engorged, with small hemorrhages and fibrin deposit in the pulp. The Malpighian bodies are represented in most instances by narrow fringes of cells around the central arteries. They show no evidence of proliferation. The lymphoid tissue of the pulp is completely replaced by red blood corpuscles and polymorphonuclear leucocytes; the latter occur in marked excess, and in many places they form small miliary-sized collections. They are also grouped in great numbers around the splenic veins and sinuses. Large mononuclear phagocytic cells are extremely numerous throughout the spleen, in the sinuses and in the reticular tissue. They contain large numbers of red blood corpuscles, polymorphonuclear leucocytes, lymphoid cells and nuclear detritus. The arteries show no lesions. The connective tissue structures are negative.

Liver: There is moderate injection. The sinusoids contain many mononuclear cells of large size, free and attached to the sinusoid walls. Many of these cells are phagocytic. They are occasionally in such numbers as to apparently occlude the sinusoids. Scattered throughout the liver are minute necroses consisting of from one to several liver cells, which have undergone a granular hyaline degeneration and are invaded by polymorphonuclear leucocytes. These necroses are scattered, without special reference to any one zone in the lobules. There is very moderate fat vacuolation, most pronounced at the periphery of the lobules. The bile ducts are normal. The bile capillaries show distinctly, by virtue of their cuticular borders; none contain inspissated bile. The blood vessels of the portal spaces show no lesions, except that small veins and capillaries are filled with large mononuclear cells.

Pancreas: Normal. Blood vessels of pancreas normal.

Kidneys: The glomeruli show in many instances an increase in nuclei, which is due to accumulation of large mononuclear cells (endothelial cells) in the capillaries, and to an occasional migrating polymorphonuclear leucocyte. A few glomeruli show a small amount of granular material between the capsule and the capillary tufts. The majority of capillaries in most glomeruli contain red blood corpuscles. Otherwise the kidney, including blood vessels, is normal.

Intestines: There are two sections of the ileum; both are normal. Blood vessels are normal.

Adrenal glands: Normal.

Blood vessels normal.

Thyroid gland: Normal.

Blood vessels normal.

Prostate gland: Gland and blood vessels normal.

Muscle (source?): An occasional fiber shows typical Zenker's degeneration, without cellular reaction. Such fibers are swollen, have lost their striation, and have a homogeneous waxy appearance, except where they have separated into irregular globular masses of hyaline material. In one of two sections examined, a medium-sized artery is partially occluded

by a fibrinous thrombus. The lumen contains numerous large mononuclear cells, and some of them are phagocytic (endothelial cells). Some of these cells are attached to the wall of the artery. The media is infiltrated with polymorphonuclear leucocytes, and surrounding the artery are a few large mononuclear cells (endothelial cells). In the intima and in longitudinal smooth muscle fibers of this artery there are numerous minute paired microörganisms characteristic of Rocky Mountain spotted fever. Other smaller blood vessels show no lesions.

Lymph node: Probably bronchial, because of carbon pigment. The sinuses are distended with blood, and contain also large numbers of large mononuclear cells, many of which are phagocytic and contain red blood corpuscles and lymphoid cells. The secondary follicles are small, but contain occasional mitotic figures.

Aorta: There are no acute lesions.

Testes and epididymis: The seminiferous tubules are normal, and show normal spermatogenesis. In a few places in the interstitial tissue surrounding blood vessels occluded by endothelial cells there are collections of similar cells, many of which are phagocytic, and polymorphonuclear leucocytes. In a few locations there are minute collections of red blood cells, some of which have been taken up by mononuclear phagocytes. The larger blood vessels in the substance of the testes contain large numbers of endothelial cells. A few show masses of endothelial cells attached to the intima, particularly in the veins. In the tunica there are numerous arteries and veins which show fibrinous mural thrombi. Such vessels contain large collections of endothelial cells, free and attached to the wall. In one instance there is an artery with the whole media infiltrated with fibrin and migrating cells with a perivascular collection of amœboid mononuclear (endothelial) cells and polymorphonuclear cells. In the vessel walls showing these lesions, both in endothelium and in smooth muscle cells, are great numbers of the minute paired microörganisms, such as have been described in the previous cases. Sections of the epididymis and pampiniform plexus

show many arteries and veins with similar lesions containing similar minute microörganisms. The tubules of the epididymis are normal.

Skin (Fig. 44): Sections of the skin and subcutaneous tissues from several different sources, including the scrotum, all show very marked lesions of blood vessels of all sizes, most striking, however, in arteries and veins of large size in the subcutaneous tissue and lower layers of the corium. These vessels contain fibrinous mural thrombi and large numbers of endothelial cells, free and attached to the vessel wall. There are many veins of intermediate size, which are completely filled with endothelial cells. The smallest lesions in arteries consist of endothelial cells attached to the intima, frequently accompanied by migrating leucocytes in the media. The internal elastic lamina is usually fragmented at the site of these lesions. The minute parasite is present in large numbers in endothelial cells, free and attached, and in smooth muscle cells in the media. There are many striking examples in these sections of smooth muscle cells filled with organisms. (Fig. 44.) With the highest powers the lanceolate shape and a surrounding clear zone or halo are easily seen. In many sections of the skin there are small veins filled with endothelial cells and polymorphonuclear leucocytes, whose walls are infiltrated with red blood corpuscles and fibrin. Surrounding such veins are small areas of hemorrhage, in which are many mononuclear phagocytic cells, containing red blood cells. Lesions of the latter sort are common in the vicinity of coil glands, which show marked degenerative changes. The epithelial cells are swollen, vacuolated, and often are desquamated and have pycnotic nuclei. Occasionally the remains of coil glands are encountered heavily infiltrated with polymorphonuclear leucocytes. The capillaries of the papillæ show lesions similar to those found near the coil glands, but to a less marked degree, and it is rare to find extravasation of blood in this region. Nerves that have become incorporated in the zones of infiltration surrounding blood vessels show occasional migrating mononuclear cells and mast cells between

the nerve fibers. Rarely there is a polymorphonuclear leucocyte within a nerve sheath. The epidermis in all locations shows practically no reaction. That of the scrotum shows slight thickening in small areas, probably due to œdema and proliferation.

Case V. — I am indebted to W. T. Thornton, M.D., of Missoula, Mont., for the notes and material of this case. The post-mortem was done by Dr. Thornton and the tissues preserved in accordance with my directions. No gross pathological conditions are recorded: a complete set of tissues was sent to me, including skin from the arms, trunk, thighs, legs, ankles and scrotum, so that the microscopical findings are of great value.

The case was that of a male adolescent who had been repeatedly bitten by ticks during the spring, so that the period of incubation was uncertain. The onset was gradual; no chill was noted and it was not until the rash appeared that the boy was regarded as sick. He was seen by Dr. Thornton on the fourth day of illness, when his temperature was 104° F., his pulse 120 and his body covered with a rash. He died on the eleventh day after a typical severe course of the disease, with "high temperature and delirium." There was no hyperæsthesia. Muscular rigidity of the extremities began on the fifth day, icterus was present on the sixth day, and became very marked before death.

The autopsy was done two hours after death. The case was regarded by Dr. Thornton, who has had considerable experience with the disease, as typical, and the microscopical findings are typical and confirmatory of the previous cases in regard to the characteristic histology and localization of the vascular lesions and the presence of the parasite.

Spotted fever Case V. Microscopic description. Eosin-methylene-blue and Giemsa stains. Heart: There are two sections of the left ventricle wall and one of the right ventricle wall. All show in the inner half of the myocardium and particularly in the muscle columns very rare minute lesions consisting of collections of mononuclear cells in and around capillaries. These cells are mostly amœboid in type, and a few are phagocytic (endothelial leucocytes). There are also a few polymorphonuclear leucocytes, lymphoid and plasma

cells and a very rare mast cell. In a few instances polymorphonuclear leucocytes are invading muscle fibers. The myocardium as a whole appears normal. The larger vessels, arteries and veins show no lesions. In the pericardium of the right ventricle there are several areas of infiltration with cells of the above type, and small arteries and veins are found containing many large mononuclear cells (endothelial cells), which in some instances are still attached to the vessel wall. No parasites can be found.

Lung: There are three sections. One shows large patches of bronchopneumonia. The exudate consists almost wholly of polymorphonuclear leucocytes and fills alveoli and bronchioles. There is no fibrin. There are numerous large mononuclear cells, not phagocytic (desquamated epithelium), and a rare phagocytic mononuclear cell. The capillaries in the alveolar walls are congested and contain many migrating polymorphonuclear leucocytes and amœboid mononuclear cells. In the alveoli the leucocytes contain many micrococci, morphologically identical with pneumococcus. The pleural surfaces are normal. The other two sections show no exudate. The capillaries in the alveolar wall contain a large number of mononuclear cells, a rare one of which is phagocytic (endothelial leucocyte). In a few locations there are collections of polymorphonuclear leucocytes in the alveolar walls. The pleura is normal.

Spleen: Intensely injected. The Malpighian bodies are small, irregular in size and contain very few mitotic lymphocytes. The pulp is nearly completely devoid of lymphocytes and the reticular tissue contains chiefly red blood cells, numerous polymorphonuclear leucocytes, and large mononuclear phagocytic cells enclosing red blood cells and polymorphonuclear leucocytes. The sinuses are filled with blood and contain many large mononuclear phagocytic cells distended with red blood cells, though some contain polymorphonuclear leucocytes and lymphoid cells. There are numerous migrating polymorphonuclear leucocytes in the sinus walls. The arteries and veins show no lesions. The connective tissue structures are normal.

Liver: There is moderate injection. The striking feature of the organ is the presence of many mononuclear phagocytic cells, free in the sinusoids, or attached to the sinusoid wall, and containing chiefly red blood corpuscles, but also occasional polymorphonuclear leucocytes. There are no necroses of any size. A rare liver cell shows hyaline change and invasion by polymorphonuclear leucocytes. The bile ducts are normal and the bile capillaries are not distended. In the portal spaces occasional arteries and veins show slight lesions in the form of endothelial cell collections on the intima, and presence of migrating leucocytes in the media. Several arteries of small size show numerous minute paired microörganisms, like those described in the preceding case in smooth muscle cells and in endothelial cells. There are no thromboses, but the connective tissue of the portal spaces containing these vessels with lesions is infiltrated with mononuclear amœboid cells (endothelial leucocytes) and polymorphonuclear leucocytes. Capillaries and lymphatics are frequently filled with endothelial cells, and a rare capillary contains in the lining endothelium a few of the minute parasites.

Kidney: Normal, except for an occasional large mononuclear cell in the glomerular capillaries. The blood vessels of all sizes are normal.

Testis and epididymis: Many seminiferous tubules show no signs of activity, and the lumina contain cells with pycnotic nuclei; on the other hand, occasional tubules show many mitoses, but rarely contain spermatozoa. A very rare tubule shows complete loss of spermatogenic cells. The interstitial tissue is slightly œdematous, and there are many small areas of large mononuclear cells grouped about small blood vessels, which are filled with similar cells (endothelial cells). There are a few small hemorrhages into the interstitial tissue and these areas contain phagocytic cells filled with red blood corpuscles. Small arteries and veins show marked thickening of the lining endothelium, and in the cells of the latter are occasional pairs of the minute paired microörganisms. A few arteries and veins of the tunica albuginea and of the pampiniform plexus show fibrinous mural thrombi overlying

lesions of the intima, which are characterized by clusters of endothelial cells and occasional polymorphonuclear leucocytes. The media always contains a few migrating leucocytes, and the smooth muscle fibers show vacuolization and rarely actual necrosis. The small microörganisms are present in the endothelial cells and smooth muscle fibers in small numbers. Small arteries and veins and capillaries contain many mononuclear cells, often phagocytic and containing red blood corpuscles.

Stomach: Normal. The blood vessels show no lesions.

Intestines: Sections of the jejunum and ileum are normal. The blood vessels show no lesions.

Skin: Sections of the skin and subcutaneous fat from the arms, legs, trunk, ankles and scrotum all show similar lesions of the blood vessels. The larger arteries and veins show occasional small lesions in the form of endothelial cell proliferation of the intima and migrating leucocytes in the media. These lesions are occasionally the site of small fibrinous mural thrombi. Small vessels are frequently filled with mononuclear cells, some of which are phagocytic. The most marked changes are in the capillaries of the corium, about coil glands and in the papillæ; in these locations the capillaries are filled with mononuclear cells, and are surrounded by groups of amœboid and phagocytic cells (endothelial cells), with occasional polymorphonuclear leucocytes, mast cells and lymphoid cells. In many instances the capillary wall is difficult to identify because of the packing of cells. In the skin of the scrotum there is intense injection of the blood vessels, and rarely a small hemorrhagic zone occurs about capillaries. The coil glands in general show degenerative changes, vacuolization, pycnotic nuclei and even complete disintegration, with infiltration of polymorphonuclear leucocytes. In sections of the skin from all of the above locations, the minute paired microörganisms occur in the vessel walls, in endothelium and in smooth muscle; occasionally in large numbers in smooth muscle cells, in arteries and veins showing only slight proliferation of the endothelium.

A few nerves in relation to vessels with perivascular reaction show a rare amœboid wandering cell, or mast cells between the nerve fibers.

Voluntary muscle: A fragment of muscle from the arm shows vascular lesions like those of the skin and subcutaneous tissues.

XVIII. SUMMARY.

Ricketts and his associates were the first to show the hereditary transmission of the virus in ticks. I have been able to verify the presence of the virus in the eggs of ticks, and to demonstrate the parasite morphologically in ova and in spermatozoa from ticks. The susceptibility of the small mammals of the Rocky Mountain states and the finding of immune animals have been shown by Ricketts and McClintic. It seems reasonable to suppose that alternation between mammals and tick occurs frequently. On the other hand, it seems probable that the virus may be maintained in many generations of ticks without introduction from a mammalian source, but that this may last indefinitely cannot be assumed. J. L. Todd has found that the spirochæte of African relapsing fever eventually disappears from *Onithodorus*. (Personal communication.) The existence of local foci of infection would indicate that hereditary transmission of the virus in ticks is an important factor in maintaining the virus in nature. The tick does not travel great distances except when attached. The range of the small mammals on which the larval or nymph stage feed is restricted, and therefore the carrying of infected ticks from locality to locality, can only be accomplished by the larger animals. As the adults engorge in the early spring months on range animals, this probably does not play a very important part in the dissemination of the ticks. Engorged females, on dropping, seek cover, and deposit their eggs wherever chance has placed them. Engorged females dropping from cattle in transport must rarely find conditions suitable for the hatching and rearing of the larvæ.

These factors must tend to retard the extension of the areas occupied by infected ticks. The sudden appearance of the disease in eastern Montana in 1915 can best be explained by the introduction of infected ticks upon transported animals.

The movements of animals with the disease could hardly account for such a wide extension. Human cases may be disregarded as a source of the virus, because of the relatively small number of individuals acting as hosts, and because patients with the disease are not accessible to ticks, while ticks attached to their persons are almost invariably destroyed.

Mammalian "carriers" of the disease have not been discovered. In all experimental animals the blood ceases to be infective after the subsidence of fever. It is, however, permissible on theoretical grounds to consider the possibility of the disease existing in a chronic form in some of the wild mammals which are hosts to the tick.

The question of the consistent difference in virulence of the disease in man in different districts is impossible of explanation, and its study requires extensive investigation into the duration of infectivity and character of the disease in all animals acting as tick hosts. Rapidly repeated passages of the virus during a long period in a single species of animal peculiar to, or particularly abundant in, a given locality, would, conceivably, modify the virulence for man. For this reason a careful study of the disease in rabbits in relation to the lower mortality of the disease in man in eastern Montana, as compared with the mortality in western Montana, is highly desirable. Parker[44, 45] has shown that the rabbit acts as host to all stages of the tick, a fact which proves the possibility of more numerous passages of the virus through this animal.

The susceptibility of the larger animals, horses, cattle and sheep, to the disease, has received but scant attention, and requires investigation. The finding of infective ticks upon the mountain goat suggests another much needed line of research. The possibilities of an immune therapy necessarily lie in the discovery of a large-sized susceptible animal.

Rocky Mountain spotted fever as a disease assumes new interest and importance now that its nature is known. The remarkable specificity of the parasite for the peripheral blood vessels in all experimental animals and in man is of significance in relation to the manner of transmission.

The lesions of the blood vessels are due to the presence of the parasite and constitute the distinctive pathology of the disease, and warrant the definition — "An acute specific infectious endangiitis, chiefly of the peripheral blood vessels . . .,"—which I have given. The character and evolution of the rash with the cutaneous sequelæ (necrosis or gangrene) are explained by the blood vessel lesions. The hyperæsthesia and probably the restlessness of the patients are explained by the secondary involvement of nerves in the inflammatory reaction surrounding blood vessels with lesions.

The lesions are at first essentially proliferative (endothelium), followed by necrosis of small groups of cells, and the chief cellular reaction, both locally in response to the presence of the parasite, and in general, presumably in response to toxins, is endothelial. The respiratory symptoms may be due in part to a central action of toxins, but it is also reasonable to ascribe some effect to the accumulation of endothelial cells in the pulmonary capillaries.

The icterus is due to red blood corpuscle destruction, and as no evidence of an intracorpuscular stage of the parasite can be obtained, is probably of toxic origin. Fused masses of red corpuscles in the spleen are probably a stage preliminary to their destruction, an assumption which is further supported by the accumulation of hemosiderin in endothelial cells. Evidence of bile stasis in the liver is completely lacking in all varieties of material studied.

There are two diseases which clinically have a strong resemblance to Rocky Mountain spotted fever, and which will probably eventually be classified in a group, the chief characteristics of which are included in my definition of Rocky Mountain spotted fever. These diseases are typhus fever and Tsutsugamushi disease, or Japanese river fever or flood fever; a brief comparison of each with Rocky Mountain spotted fever follows.

Typhus fever and Rocky Mountain spotted fever. — Typhus fever, of all diseases, is most like Rocky Mountain spotted fever, and if the two should exist at the same time in the same

community a differential diagnosis without animal inoculation would be impossible. The course of the two diseases and the characteristics of the rash in each are almost identical. Like the virus of Rocky Mountain spotted fever, that of typhus is not filterable, and Nicolle and Blaizot[79] find indications of the same susceptibility to physical agents, for they find that the virus of typhus will survive but six days on ice and but two days at 37° C.

The pathological anatomy of typhus is not distinctive. The spleen is not uniformly enlarged as in spotted fever. The histology of the skin lesions has been described recently by a number of authors, and resembles in many respects that of spotted fever.

There are a few clinical differences which may be mentioned here. Typhus fever is transmitted by the body louse. The incubation period is longer than in the case of Rocky Mountain spotted fever, usually about twelve days. The rash makes its appearance on the chest and shoulders and extends over the trunk, before appearing on the arms and legs, in almost the reverse order of the rash in Rocky Mountain spotted fever. In typhus, enlargement of the spleen is absent or less marked than in spotted fever. Icterus, which is almost constant in spotted fever, is absent in typhus.

Defervescence of the fever in typhus takes place more quickly and is usually regarded as occurring by crisis.

Secondary infections and pneumonia are more common after typhus.

In recent years the bacterium-like bodies in lice first described by Ricketts[85] and Hegler and von Prowazek,[76] and named *Rickettsia prowazekii* by da Rocha-Lima,[86] have received much attention, and much support as the causative agent of typhus fever, by da Rocha-Lima, Sergent, Foley and Vialatte,[87] Proescher,[82] Toepfer and Schuessler,[88] Toepfer,[89] Otto and Dietrich[81] and others.

However, a large number of microörganisms have been described as the causative agent of typhus. M. Rabinowitsch,[84] in 1913, cultivated a minute "cocco-bacillus," which

is now regarded by some as identical with Rickettsia. Nicolle, Blanc and Conseil[78] found cocco-bacilli in five per cent of lice collected from districts where there was no typhus.

Brumpt[72] found Rickettsia bodies in a large per cent of lice from healthy persons, and proved that these lice were not capable of transmitting typhus fever by allowing fifty of them to feed upon himself on two or three occasions. Other workers have found Rickettsia in non-infective lice, and recently Arkwright, Bacot and Duncan[90] have described Rickettsia in lice fed upon trench fever patients.

The etiological significance of Rickettsia bodies in lice and in the blood of typhus patients is not yet proved, and as described by Ricketts, von Prowazek and da Rocha-Lima, they have a significant resemblance to the parasite of Rocky Mountain spotted fever. The recent finding of lesions of the endothelium in the blood vessels of the skin by Fraenkel,[74, 75] Aschoff,[70] Poindecker,[83] Bauer,[71] von Chiari[73] and Jaffé[77] in man, and by Neill[80] in guinea-pigs, makes it seem probable that the pathology of typhus is very similar to that of Rocky Mountain spotted fever, and therefore that the etiological relationship of Rickettsia, at least as observed in the blood of patients, deserves serious consideration. The demonstration of the organism in the vascular lesions of typhus would do much to settle the question.

Rocky Mountain spotted fever and Tsutsugamushi disease, or Japanese flood or river fever. — The similarity between these two diseases has long excited attention. Ashburn and Craig[3] in 1908 published a comparative study, with the conclusion that they were not identical, though presenting many points of resemblance. The resemblances, as well as the differences between the two, are made accessible for a more complete comparison by the recent paper of Kitashima and Miyajima.[92] Tsutsugamushi disease clinically presents a very strong resemblance to Rocky Mountain spotted fever. It is transmitted by the bite of the larva of an acarinen, commonly called the akamushi mite, about whose scientific name there has been considerable discussion. The acarinen in question

has been considered to be a trombidium, and was named *Trombidium akamushi* by Brumpt. The life cycle has recently been studied by Miyajima and Okumura,[93] who point out differences between the akamushi mite and trombidium, and its similarity to another genus — *Leptus*. They accordingly propose the name *Leptus akamushi*.

The virus of Tsutsugamushi disease, according to Kitashima and Miyajima, like that of spotted fever, is not filterable, and is extremely susceptible to chemical and physical agents.

Tsutsugamushi disease, like Rocky Mountain spotted fever, is limited to certain districts infected with its intermediate host, *Leptus akamushi* (*Trombidium akamushi*), namely the provinces of Akita and Niigata in Japan. A similar disease in Java is transmitted by the larval stage of a mite whose habitat is in districts flooded at certain seasons of the year.

The mortality, like that of spotted fever, varies in different districts, but unlike the latter, it varies from season to season in the same districts; and ranges from fourteen per cent to fifty-five per cent. As in the case of spotted fever, it is less fatal in the young. The majority of fatal cases die within twenty days; in Kitashima's and Miyajima's series of three hundred out of three hundred sixty-eight fatal cases, ninety-four died within ten days. The incidence is naturally highest among those exposed to the bites of the mite, and hence in land laborers.

The incubation period is seven to ten days, but may be as long as twelve to fourteen days. The prodromal symptoms and onset are similar to those of Rocky Mountain spotted fever. The fever reaches a maximum in three to four days, 40° to 41° C., and is of the continuous type and lasts one to three weeks, falling by lysis. The rash appears on the fifth to ninth day and does not become hemorrhagic as in the case of spotted fever, it usually disappears within a week. The pulse remains slow as compared with Rocky Mountain spotted fever, 90 to 100, and is full and strong, varying in proportion to the fever.

In favorable cases recovery is complete by the fourth to fifth week. Two symptoms occur in Tsutsugamushi disease

which are absent in Rocky Mountain spotted fever, a general painful swelling of the peripheral lymph nodes and necrosis of the skin at the site of the mite bite.

Nothing distinctive in the pathological anatomy has been described. The spleen becomes enlarged. The white blood count is at first below normal and later above normal for a short period.

Monkeys and guinea-pigs are susceptible to experimental inoculation; the latter, however, do not give a characteristic reaction as does the monkey. The field mouse, *Microtus montebelli*, is also susceptible, and is believed to be the important natural mammalian host of the virus.

The analogies between Rocky Mountain spotted fever and Tsutsugamushi disease are many. The chief differences, besides that of locality and nature of the intermediate host, are in the milder character of the rash, lymph node enlargement, and necrosis of the site of the mite bite in the latter.

A summary of the data upon which the conclusion has been reached that the microörganism described is the causative agent of Rocky Mountain spotted fever includes the following facts.

1. The constant occurrence of a microörganism of distinctive size and morphology in the lesions characteristic of the disease in man, monkey, rabbit and guinea-pig.

2. The constant presence of an identical microöorganism exhibiting undoubted evidences of developmental phases in ticks of proved infectivity, and the absence of similar forms in proved non-infective ticks.

3. The ability to recognize this specific microörganism in the tissues and eggs of infective ticks in the presence of bacteria occasionally present in abundance in ticks of the species concerned.

The failure to cultivate this parasite is balanced by the proof furnished of its multiplication in and inseparability from infective ticks, and its absence in non-infective ticks. The bacilli seen by Ricketts in large numbers in the tissues and

eggs of non-infective as well as infective ticks are not to be confused with any phase of the spotted fever parasite. Ricketts did describe one form of this parasite which he found in blood films, namely, the lanceolate form.

The reasons for concluding that the parasite of Rocky Mountain spotted fever is not a bacterium, in the ordinary sense of the term, are:

1. Its morphological sequence in infected nymphs, and the presence of only one morphological type in the blood of mammals.
2. Its staining reactions and its appearance under dark field illumination.
3. Its extreme susceptibility to physical and chemical agents.
4. Its specificity for the peripheral blood vessels, with the production of an identical type of lesion and disease course in all susceptible mammals.

Bacteria which are the causes of epidemics often show a striking specificity for certain tissues, for example, the meningococcus in epidemic cerebrospinal fever, the pneumococcus in pneumonia, and the typhoid bacillus in typhoid fever. In each of these diseases a preliminary invasion of the blood stream has been proved, yet the bacteria thrive best and produce their deleterious effects in certain tissues only. These bacteria, while pathogenic for animals, do not reproduce the diseases as they occur in man. Meningitis, it is true, can be produced by direct inoculation into the meninges of meningococcus cultures, or of numerous other pathogenic bacteria, while it is impossible to reproduce lobar pneumonia and typhoid fever in animals by any means. The viruses of rabies, poliomyelitis and vaccinia, on the other hand, if introduced into susceptible animals, do reproduce the diseases which they cause in man.

Classification with the protozoa also presents difficulties, chief of which is the lack of definite morphological proof, a difficulty largely dependent upon the minute size of the

parasite. Protozoa are for the most part highly specialized in their host requirements, particularly those protozoa which are intracellular. The hemo-flagellates exhibit greatest versatility in this respect, but not comparable with that of the spotted fever parasite, with its wide range of mammalian hosts.

Three definite morphological types of the spotted fever parasite can be recognized: (1) An extra-nuclear bacillus-like form without chromatoid granules, relatively large and only present in ticks during the initial multiplication of the parasites; (2) a relatively small rod-shaped form with chromatoid granules, probably the same form seen within nuclei in sections of ticks, and rarely in smooth muscle cells in the blood vessels of mammals; and (3) a relatively large lanceolate paired form present in ticks and in the blood and lesions in mammals. This lanceolate form is characterized by its "chromatoid" staining reaction, and according to the evidence at hand, is the form in which the virus is passed between the tick and mammalian hosts. The other two forms described are multiplicative stages, and can only be demonstrated occasionally and with difficulty in mammalian hosts.

The name *Dermacentroxenus rickettsi* is proposed for this parasite.

XIX. BIBLIOGRAPHY.

Rocky Mountain Spotted Fever.

1. Anderson, John F. Spotted fever (tick fever) of the Rocky Mountains. U. S. Pub. Health and Marine Hosp. Service, Hyg. Lab. Bull., No. 14, 1903.

2. Ashburn, P. M. *Piroplasmosis hominis* (?) — spotted fever of Montana. Lancet-Clinic, liv, April 22, 1905.

2A. Ashburn, P. M. A suggestion as to the treatment of the "spotted fever" of Montana. Lancet-Clinic, liv, May 20, 1905.

3. Ashburn, P. M., and Craig, Charles F. A comparative study of Tsutsugamushi disease and spotted or tick fever of Montana. Philippine Journ. of Science, ii, No. 1, Section B, Medical Sciences, 1908.

4. Banks, N. A revision of the ixodidæ, or ticks, of the United States. U. S. Dept. of Agriculture, Bureau of Entomol., Technical Series, No. 15, 1908.

5. Banks, N. The scientific name of the spotted fever tick. Journ. Am. Med. Assoc., lv, No. 18, 1574, 1910.

6. Birdseye, Clarence. Some common mammals of western Montana in relation to agriculture and spotted fever. U. S. Dept. of Agriculture, Farmers' Bulletin, 484, 1912.

7. Bishopp, F. C., and King, W. V. Additional notes on the biology of the Rocky Mountain spotted fever tick. Journ. Economic Entomol., vi, No. 2, 1913.

8. Christophers, S. R. The anatomy and histology of ticks. Scientific memoirs by officers of the medical and sanitary departments of the Government of India, N. S., No. 3, 1906.

9. Cooley, R. A. Tick control in relation to the Rocky Mountain spotted fever. A report of coöperative investigations conducted by the Bureau of Entomology and the Montana Experiment Station, Montana Agricultural College. Experiment Station Bull., No. 85, 1911.

10. Cooley, R. A. The spotted fever tick (*Dermacentor venustus*, Banks) and its control in the Bitter Root Valley, Mont. — a review. Journ. Economic Entomol., viii, No. 1, 1915.

11. Cooley, R. A. Control of the Rocky Mountain spotted fever tick in Montana. Second biennial report of the Montana State Board of Entomology, 1915–1916.

12. Cooley, R. A. Third biennial report of the Montana State Board of Entomology, 1917–1918.

13. Cumming, James G. Rocky Mountain spotted fever in California. Journ. Infect. Dis., xxi, No. 5, 1917.

14. Davis, Benjamin Franklin. Unfinished experiments of Dr. Howard T. Ricketts on Rocky Mountain spotted fever. Contributions to Medical Science, by Howard Taylor Ricketts, Univ. of Chicago Press, 1911, 409.

15. Davis, Benjamin Franklin, and Petersen, William F. Complement deviation in Rocky Mountain spotted fever. Journ. Infect. Dis., viii, 330, 1911.

16. Fantham, H. B., Stephens, J. W. W., and Theobald, F. V. The animal parasites of man. Wm. Wood & Company, London and New York, 1916.

17. Foot, N. C. Rocky Mountain spotted fever in the domestic rabbit. Journ. Med. Research, xxxix, No. 4, 1919.

18. Fricks, L. D. Rocky Mountain spotted (or tick) fever. Sheep grazing as a possible means of controlling the wood tick (*Dermacentor andersoni*) in the Bitter Root Valley. U. S. Public Health Service, Weekly Reports, xxviii, No. 32, 1913.

19. Fricks, L. D. Rocky Mountain spotted fever. A report of its investigation and of work in tick eradication for its control during 1913. U. S. Public Health Service, Weekly Reports, xxix, No. 8, 1914.

20. Fricks, L. D. Rocky Mountain spotted fever. Some investigations made during 1912 by Passed Assistant Surgeon T. B. McClintic. U. S. Pub. Health Service, Weekly Reports, xxix, No. 17, 1914.

21. Fricks, L. D. Rocky Mountain spotted fever. A report of its investigation and of measures undertaken for its eradication during 1914. U. S. Pub. Health Service Reports, xxx, No. 3, 1915.

22. Fricks, L. D. Rocky Mountain spotted fever. A report of laboratory investigations of the virus. U. S. Pub. Health Service, Weekly Reports, xxxi, No. 9, 1916.

23. Fricks, L. D. Rocky Mountain spotted fever. Some points in its diagnosis and prevention. U. S. Pub. Health Service, Weekly Reports, xxxi, Suppl., No. 28, July, 1916.

24. Fricks, L. D. U. S. Pub. Health Service, Weekly Reports, xxxii, September 21, 1917.

25. Heinemann, P. G., and Moore, Josiah J. Experimental therapy of Rocky Mountain spotted fever. Journ. Infect. Dis., x, No. 3, 1912.

26. Hunter, W. D., and Bishopp, F. C. Some of the more important ticks of the United States. U. S. Dept. of Agriculture, Yearbook for 1910.

27. Hunter, W. D., and Bishopp, F. C. The Rocky Mountain spotted fever tick, with special reference to the problem of its control in the Bitter Root Valley in Montana. U. S. Dept. of Agriculture, Bureau of Entomology Bull., No. 105.

28. King, W. V. Experimental transmission of Rocky Mountain spotted fever by means of the tick. Preliminary note. Pub. Health Rep., U. S. Pub. Health and Marine Hosp. Serv., 1906, xxi, July 27.

29. Kelly, Frank L. Rocky Mountain spotted fever — its prevalence and distribution in Modoc and Lassen counties, California. A preliminary report. Calif. State Journ. of Med., 1916, xiv, 407.

30. Le Count, E. R. A contribution to the pathological anatomy of Rocky Mountain spotted fever. Journ. Infect. Dis., viii, 421, 1911.

31. Maver, Maria B. Transmission of spotted fever by the tick in nature. Journ. Infect. Dis., viii, 322, 1911.

32. Maver, Maria B. Transmission of spotted fever by other than Montana and Idaho ticks. Journ. Infect. Dis., viii, 327, 1911.

33. Maxey, Ed. E. Some observations on the so-called spotted fever of Idaho. Medical Sentinel, vii, No. 10, 1899.

34. Maxey, Ed. E. Rocky Mountain spotted (tick) fever; with special reference to casual factors, mortality and geographical distribution in Idaho. Medical Sentinel, xvi, December, 1908.

35. McCalla, F. P. Direct transmission from man to man of the Rocky Mountain spotted (tick) fever. Medical Sentinel, xvi, No. 2, 1908.

36. McClintic, Thomas B. Investigations of and tick eradication in Rocky Mountain spotted fever. U. S. Pub. Health and Marine Hosp. Serv., Weekly Reports, xxvii, No. 20, 1912.

37. McCullough, G. T. Spotted fever. Medical Sentinel, x, No. 7, 1902.

38. Michie, Henry C., Jr., and Parsons, Houston H. Rocky Mountain spotted (tick) fever. Report of an investigation in the Bitter Root Valley of Montana. Medical Record, lxxxix, No. 7, 1916.

39. Moore, Josiah J. Time relationships of the wood tick in the transmission of Rocky Mountain spotted fever. Journ. Infect. Dis., viii, 339, 1911.

40. Neumann, R. O., and Mayer, Martin. Wichtige tierische Parasiten und ihre Uberträger. J. F. Lehmann, Münich, 1914.

41. Nuttall, George H. F.; Warburton, Cecil; Cooper, W. F., and Robinson, L. E. Ticks — a monograph of the ixodoidea. Part 2, 1911, University Press, Cambridge, England.

42. Nuttall, G. H. F. Observations on the biology of ixodidæ. Parasitology, vii, No. 4, 1915.

43. Patton, Walter Scott, and Cragg, Francis William. A textbook of medical entomology. Christian Literature Society for India, London, Madras and Calcutta, 1913.

44. Parker, R. R., and Wells, R. W. Some facts of importance concerning the Rocky Mountain spotted fever tick (*Dermacentor venustus*, Banks) in eastern Montana. Montana State Board of Entomology. Second Biennial Report for 1915–1916, 45.

45. Parker, R. R. Second report on investigations of the Rocky Mountain spotted fever tick in eastern Montana. Montana State Board of Entomology. Third Biennial Report for 1917–1918, 41.

46. Parker, R. R. Some results of two years' investigations of the Rocky Mountain spotted fever tick in eastern Montana. Journ. Economic Entomol., xi, No. 2, 1918.

47. Ricketts, H. T. The study of "Rocky Mountain spotted fever" (tick fever ?) by means of animal inoculations. A preliminary communication. Journ. Amer. Med. Ass., xlvii, 33, 1906.

48. Ricketts, H. T. The transmission of Rocky Mountain spotted fever by the bite of the wood tick (*Dermacentor occidentalis*). Journ. Amer. Med. Ass., 1906, xlvii, 358.

49. Ricketts, H. T. Further observations on Rocky Mountain spotted fever and *Dermacentor occidentalis*. Journ. Amer. Med. Ass., xlvii, 1067, 1906.

50. Ricketts, H. T. Further experiments with the wood tick in relation to Rocky Mountain spotted fever. Journ. Am. Med. Ass., xlix, 1278, 1907.

51. Ricketts, H. T. Observations on the virus and means of transmission of Rocky Mountain spotted fever. Journ. Infect. Dis., iv, 141, 1907.

52. Ricketts, H. T. The rôle of the wood tick (*Dermacentor occidentalis*) in Rocky Mountain spotted fever, and the susceptibility of local animals to this disease. A preliminary report. Journ. Am. Med. Ass., xlix, 24, 1907.

53. Ricketts, H. T. A summary of investigations of the nature and means of transmission of Rocky Mountain spotted fever. Trans. Chicago Path. Society, 1907.

54. Ricketts, H. T., and Gomez, L. Studies on immunity in Rocky Mountain spotted fever. Journ. Infect. Dis., v, 221, 1908.

55. Ricketts, H. T. A microörganism which apparently has a specific relationship to Rocky Mountain spotted fever. A preliminary report. Journ. Am. Med. Ass., lii, 379, 1909.

56. Ricketts, H. T. Some aspects of Rocky Mountain spotted fever as shown by recent investigations. The Wesley M. Carpenter lecture of the New York Academy of Medicine, 1909. Med. Record, lxxvi, 842, 1909.

57. Robinson, L. E., and Davidson, J. The anatomy of *Argas persicus* (Oken, 1818). Parasitology, vi, Nos. 1, 3 and 4, 1913–1914.

58. Rucker, W. C. Rocky Mountain spotted fever. U. S. Pub. Health Serv., Weekly Reports, xxvii, No. 36, 1912.

59. Salmon, D. E., and Stiles, Ch. Wardwell. Cattle ticks (ixodoidea) of the United States. U. S. Dept. of Agriculture, Bureau of Animal Industry, 17th Annual Report for 1900, 1902.

60. Samson, Katharina. Zur anatomie und Biologie von Ixodes ricinus L. Zeitsch. f. Zool., xciii, No. 2, 1909.

61. Spencer, W. O. Mountain or spotted fever as seen in Idaho and eastern Oregon. Medical Sentinel, xv, No. 11, 1907.

62. Stewart, J. L., and Smith, W. F. Clinical phases of Rocky Mountain spotted fever. Medical Sentinel, xvi, December, 1908.

63. Stiles, Ch. Wardwell. A zoölogical investigation into the cause, transmission, and source of Rocky Mountain "spotted fever." U. S. Pub. Health and Marine Hosp. Serv., Hyg. Lab. Bull., No. 26, 1905.

64. Stiles, Ch. Wardwell. The correct name of the Rocky Mountain spotted fever tick. Journ. Am. Med. Ass., lv, No. 22, 1909, 1910.

65. Stiles, Ch. Wardwell. The taxonomic value of the microscopic structure of the stigmal plates in the tick genus *Dermacentor*. U. S. Pub. Health and Marine Hosp. Serv., Hyg. Lab. Bull., No. 62, 1910.

66. Tuttle, T. D. Some indications for state control of Rocky Mountain tick fever. Medical Sentinel, xvi, December, 1908.

67. Wilson, Louis B., and Chowning, William M. The so-called "spotted fever" of the Rocky Mountains. A preliminary report to the Montana State Board of Health. Journ. Am. Med. Ass., xxxix, No. 3, 1902.

68. Wilson, Louis B., and Chowning, William M. Studies in *Pyroplasmosis hominis* ("spotted fever" or "tick fever") of the Rocky Mountains. Journ. Infect. Dis., 1904, i, No. 1.

69. Wood, W. W. Spotted fever as reported from Idaho. Report of the surgeon-general of the army to the Secretary of War, 1896.

Other References. — Typhus.

70. Aschoff, L. Ueber anatomische Befunde bei Fleckfieber. Med. Klinik., xi, No. 29, 1915.

71. Bauer, E. Zur Anatomie und Histologie des Flecktyphus. Münch. Med. Wochenschr., lxiii, No. 15, 1916.

72. Brumpt, E. Au sujet d'un parasite (*Rickettsia prowazeki*) des poux l'homme considéré, à tort, comme l'agent causal du typhus exanthématique. Bull. Soc. Path. Exotique, xi, No. 3, 1918.

73. von Chiari, R. F. Die Veränderungen der Bindehaut des Auges bei Fleckfieber. Wien. Klin. Wochenschr., xxx, No. 47, 1917.

74. Fraenkel, E. Ueber Fleckfieber und Roseola. Münch. Med. Wochenschr., lxi, No. 2, 1914.

75. Fraenkel, E. Zur Fleckfieberdiagnose. Münch. Med. Wochenschr., lxii, No. 24, 1915.

76. Hegler, C., and von Prowazek, St. Untersuchungen über Fleckfieber (Vorlaüfiger Bericht). Berlin. Klin. Wochenschr., l, No. 3, 1913.

77. Jaffé, R. Zur Pathologischen Anatomie des Fleckfiebers. II. Mikroskopische Untersuchungen mit besondern Berücksichtigung ganz frisches und ganz alter Fälle. Med. Klinik., xiv, No. 23, 1918.

78. Nicolle, C., Blanc, G., and Conseil, E. Quelques points de l'étude experimentale du typhus exanthématique. Compt. Rend. Acad. Sci., clix, No. 19, 1914.

79. Nicolle, C., and Blaizot, L. Nouvelle recherches sur le typhus exanthématique (conservation et siège du virus). Compt. Rend. Acad. Sci., clxi, No. 21, 1915.

80. Neill, M. H. Experimental typhus fever in guinea-pigs. A description of a scrotal lesion in guinea-pigs infected with Mexican typhus. U. S. Pub. Health Serv., Weekly Report, xxxii, No. 28, 1917.

81. Otto, R., and Dietrich. Beiträge zur "Rickettsein" Frage. Deut. Med. Wochenschr., xliii, No. 19, 1917.

82. Proescher, Fr. Zur Etiologie des Fleckfiebers. Berlin. Klin. Wochenschr., lii, No. 31, 1915.

83. Poindecker, Hans. Zur Diagnose des Fleckfiebers in Felde. Münch. Med. Wochenschr., lxiii, No. 5, 1916.

84. Rabinowitsch, Marcus. Ueber den Flecktyphuserreger. Münch. Med. Wochenschr., lx, No. 44, 1913.

85. Ricketts, H. T. The etiology of the typhus fever (*Tabardillo*) of Mexico City. Journ. Am. Med. Ass., liv, 1373, 1910.

86. da Rocha-Lima, H. Zur Aetiologie des Fleckfiebers. Berlin. Klin. Wochenschr., liii, No. 21, 1916.

87. Sergent, Edm., Foley, H., and Vialatte, C. Sur des formes microbiennes abondantes dans le corps de poux infectés par le typhus exanthématique et toujours absentes dans le poux témoins non-typhiques. Compt. Rend. Soc. Biol., lxxvii, No. 21, 1914.

88. Toepfer, H., and Schuessler, H. Zur Aetiologie des Fleckfiebers. Deut. Med. Wochenschr., xlii, No. 38, 1916.

89. Toepfer, H. Der Fleckfiebererreger in der Laus. Deut. Med. Wochenschr., xlii, No. 41, 1916.

Other References. — Miscellaneous.

90. Arkwright, J. A., Bacot, A., and Duncan, F. Martin. The Association of rickettsia with trench fever. Journ. Hyg., xviii, No. 1, 1919.

91. Goodpasture, E. W., and Burnett, F. L. The pathology of pneumonia accompanying influenza. U. S. Naval Medical Bull., xiii, No. 2, 1919.

92. Kitashima, T., and Miyajima, M. Studien über die Tsutsugamushi-Krankheit. Kitasato Arch. of Exper. Med., ii, Nos. 2 and 3, 1918.

93. Miyajima, M., and Okomura, T. On the life cycle of the "Akamushi." Kitasato Arch. of Exper. Med., i, No. 1, 1917.

94. Smith, Theobald. A characteristic localization of *Bacillus abortus* in the bovine fetal membranes. Journ. Exper. Med., xxix, No. 5, 1919.

95. Tyzzer, Ernest Edward. A fatal disease of the Japanese waltzing mouse, caused by a spore-bearing bacillus (*Bacillus piliformis* N. Sp.). Journ. Med. Research, xxxvii, No. 2, 1917–1918.

96. Wolbach, S. B. The distribution and morphology of *Spirocheta duttoni* and *Spirochæta kochi* in experimentally infected ticks (*Ornithodorus moubata*). Journ. Med. Research, xxx, No. 1, 1914.

97. Wolbach, S. B., Chapman, W. H., and Stevens, H. W. Concerning the filterability of trypanosomes. Journ. Med. Research, xxxiii, No. 1, 1915.

XX. DESCRIPTION OF PLATES I. — XXI.

PLATE I., FIG. 1. — A typical ranch or farm on the west side of the Bitter Root Valley. To show the character of the country, and unmelted snow in the month of May.

FIG. 2. — Photograph of a heavily tick-infested region. Mouth of a canyon, west side of Bitter Root Valley.

PLATE II., FIGS. 3 and 4. — Wire gauze cages sewn to adhesive plaster as used in feeding ticks.

FIG. 5. — Cage applied to abdomen of a guinea-pig.

FIGS. 6 and 7. — Two stages in the necrosis of the ear of a rabbit recovering from Rocky Mountain spotted fever.

PLATE III., FIG. 8. — Unfed larva of *Dermacentor venustus*, 8 diameters.

FIG. 9. — Engorged larva of *Dermacentor venustus*, 8 diameters.

FIG. 10. — Unfed nymph of *Dermacentor venustus*, 8 diameters.

FIG. 11. — Engorged females, *Dermacentor venustus*, natural size.

FIG. 12. — Unfed female, *Dermacentor venustus*, 8 diameters.

FIG. 13. — Unfed male, *Dermacentor venustus*, 8 diameters.

FIG. 14. — Engorged nymph of *Dermacentor venustus*, 8 diameters.

FIG. 15. — Engorged female, with eggs, *Dermacentor venustus*, natural size.

PLATE IV., FIG. 16. — Male, *Dermacentor venustus*, ventral side.

FIG. 17. — Female, *Dermacentor venustus*, ventral side.

PLATE V., FIGS. 18 and 19. — Dorsal and ventral dissections of partially fed females, *Dermacentor venustus*.

Explanation of numbers and letters:

1. Salivary glands.
2. Genital aperture.
3. Brain.
4. Vagina.
5. Uterus.

6. Oviduct.
7. Malpighian tube.
8. Rectal sac.
9. Anal aperture.
10. Ovary.
11. Hind gut or rectum.
A. Antero-lateral division of intestines.
B. Anterior diverticulum.
C. Lateral diverticulum.
D. Posterior diverticulum.
E. Internal branch of posterior diverticulum.
F. External branch of posterior diverticulum.
G. Mid-intestine.
H. External branch or diverticulum of posterior lateral division of intestine.
I. Internal branch or diverticulum of posterior lateral division of intestine.

PLATE VI., FIG. 20. — Initial form of the parasite of Rocky Mountain spotted fever, Tick XLVIII. Smear of intestinal content, 2,000 diameters.

FIG. 21. — Minute rod form of the spotted fever parasite, showing chromatoid granules, Tick LXXIX. Smear of intestinal content, 2,000 diameters.

FIG. 22. — Smear of intestinal content, Tick LXXXI. Minute form of the parasite with chromatoid granules.

FIG. 23. — Smear preparation from eggs of a tick which had partly engorged upon a horse in the Bitter Root Valley. Shows the bacilli which are common in the eggs and tissues of *Dermacentor venustus*, and probably the cause of Ricketts's confusion, 2,000 diameters.

FIG. 24. — Drawings from thick film preparations from monkeys and guinea-pigs, showing the lanceolate forms of the Rocky Mountain spotted fever parasite. 1,500 diameters.

FIG. 25. — Schematic enlargement from a thick film preparation of the Rocky Mountain spotted fever parasite, to show differential staining.

FIG. 26. — Lanceolate forms of the parasite in eggs of Tick XXXII. 2,000 diameters.

FIG. 27. — Section of Malpighian tube of Tick LXXXI. Giemsa's stain. Intra-nuclear forms of the parasite in a greatly distended nucleus. 1,500 diameters.

FIG. 28. — Smear preparation of salivary gland of Tick XI. Shows lanceolate and minute forms of the parasite. 1,500 diameters.

FIG. 29. — Smear preparation of teased tissues from skin of Guinea Pig 15, Strain I. Shows rod and lanceolate forms of the parasite. 1,500 diameters.

PLATE VII., FIG. 30. — Smear preparation, Tick XXXIV., Malpighian tube, showing lanceolate and minute rod forms with chromatoid granules. Photomicrograph 2,000 diameters.

FIG. 31. — Section of nerve trunk, Tick XXI., Giemsa's stain, showing parasites. Photomicrograph 2,000 diameters.

FIG. 32. — Same as FIG. 27. Photomicrograph, 2,000 diameters.

FIG. 33. — Smear preparation, Tick XIII., salivary gland, minute rod forms with chromatoid granules. Photomicrograph, 2,000 diameters.

FIG. 34. — Smear preparation, Tick XLVIII., intestinal contents. Initial form of parasite. Photomicrograph, 2,000 diameters.

FIG. 35. — Smear preparation, Tick LXXXI., intestinal contents. Minute rod form with chromatoid granules. Photomicrograph, 2,000 diameters.

PLATE VIII., FIG. 36. — Section of salivary gland acinus, Type 1, Tick XIII., Giemsa's stain, showing the parasites in gland cells and in lumen of gland. 1,500 diameters.

FIG. 37. — Section of intestine, Tick XI., Giemsa's stain, showing parasites in wall of intestine, and within a muscle fiber. 1,500 diameters. Compare with photograph, FIG. 43.

FIG. 38. — Section of salivary gland acinus, Type 2, Tick XIV., showing parasites. 1,500 diameters.

FIG. 39. — Section of nerve trunk, Tick XXI., 1,000 diameters. Compare with photomicrograph, FIG. 31.

FIG. 40. — Section of leg muscle, Tick XIV., showing parasites. 1,500 diameters.

PLATE IX., FIG. 41. — Section of salivary gland duct, Tick XIV., Giemsa's stain, showing minute forms of parasite. Photomicrograph, 2,000 diameters.

FIG. 42. Section of Malpighian tube, Tick XIV., showing a nucleus distended with the parasites. Photomicrograph, 2,000 diameters.

FIG. 43. — Same as FIG. 37. Photomicrograph at 2,000 diameters of muscle fiber filled with the minute forms of the parasite.

FIG. 44. — Tangential section of an artery, skin of scrotum, Human Case IV., showing a smooth muscle fiber filled with the lanceolate form of the parasite. Photomicrograph, 2,000 diameters.

PLATE X., FIG. 45. — Section, Guinea Pig 11, Strain I., to show the perivascular accumulation of large mononuclear cells, an arteriole from the epididymis.

FIG. 46. — The lumen of the arteriole of FIG. 45, showing smooth muscle fibers filled with the parasites. 2,000 diameters.

PLATE XI., FIG. 47. — Section of a vein of the skin from a monkey, showing acute thrombosis and distribution of the parasites. 1,000 diameters.

FIG. 48. — Section of an arteriole of the skin, Guinea Pig 11, Strain I., showing smooth muscle fibers containing the lanceolate form of the parasite. 2,000 diameters.

PLATE XII., FIG. 49. — Section of an arteriole of the skin of the scrotum of a guinea-pig, showing occlusion due to endothelial cell proliferation. 1,000 diameters.

Fig. 50. — Parasites in the intima of an artery of the testes, Monkey 1. 1,500 diameters.

Plate XIII., Fig. 51. — Longitudinal section of an artery of the epididymis, Human Case III., Giemsa's stain, 125 diameters. Beginning thrombus formation.

Fig. 52. — Guinea Pig 29, Tick X. strain series. The scrotal lesion, with beginning necrosis.

Plate XIV., Fig. 53. — Skin of leg, Case I., showing vascular lesions.

Fig. 54. — Skin of buttock, Case I., showing vascular lesions.

Fig. 55. — Skin of thigh, Case II., showing vascular lesions.

Plate XV., Fig. 56. — Parasites in mononuclear cell (endothelial cell) in blood film, Human Case II. Photomicrograph 2,000 diameters.

Fig. 57. — Arteriole, skin, Case I., showing perivascular infiltration and mural thrombus.

Fig. 58. — Arteriole, epididymis, Human Case III.

Plate XVI., Fig. 59. — Section through tick bite, Hayes Guinea Pig 3, showing lanceolate form of parasite in endothelial cells in œdematous connective tissue. Giemsa's stain, 1,500 diameters.

Fig. 60. — Intima of an artery of the skin from the ankle of Human Case II., showing early thrombosis and a group of the parasites in an endothelial cell.

Plate XVII., Fig. 61. — Liver, Human Case II., showing focal necrosis, 1,000 diameters.

Fig. 62. — Spleen, Human Case II., 1,000 diameters.

Plate XVIII., Fig. 63. — Artery, testes, Human Case III., showing early lesions, with parasites in endothelium and beneath internal elastica. 1,000 diameters.

Fig. 64. — Arteriole of skin, Guinea Pig 11, Strain I. 2,000 diameters.

Fig. 65. — Artery, skin, Monkey 1, showing early lesions and the parasites beneath internal elastica. 1,000 diameters.

Plate XIX., Fig. 66. — Arteriole, skin of scrotum, Human Case II., Giemsa's stain, showing distribution of the parasites and early reaction. 1,500 diameters.

Fig. 67. — Section through alveolar wall of lung, Case II., to show the accumulation of endothelial cells. 750 diameters.

Fig. 68. — Parasites in smooth muscle fibers. From a tangentially-cut section of an artery of the testes, Human Case II.

Plate XX., Fig. 69. — Artery, skin, Guinea Pig 10, Strain I., shows the parasites in smooth muscle fibers. Photomicrograph reduced from 2,000 diameters.

Plate XXI., Fig. 70. — Artery, skin of scrotum, Human Case III., showing endothelial proliferation and a smooth muscle fiber containing the parasites. Photomicrograph reduced from 2,000 diameters.

ACKNOWLEDGMENTS.

For the suggestion and invitation to study the disease in the Bitter Root Valley and for traveling expenses I am indebted to the Montana Department of Health and the Montana State Board of Entomology. It gives me pleasure to express my thanks and indebtedness to the following gentlemen:

To Prof. R. A. Cooley, state entomologist and secretary of the Board of Entomology, and Dr. W. F. Cogswell, secretary of the State Board of Health of Montana and chairman of the Board of Entomology, for many kindnesses; to Drs. H. C. Smith, F. D. Pease, and W. H. Harrison of Missoula for very generous and self-sacrificing provision of laboratory facilities; to Surgeon L. D. Fricks of the Public Health Service for ticks and strains of the virus; to W. V. King, Ph.D., U. S. Bureau of Entomology, for friendly assistance and ticks; to R. R. Parker, Ph.D., of the Montana State Board of Entomology, for ticks; to Dr. N. C. Foot, for assistance in maintaining the virus in guinea-pigs; to Dr. F. D. Pease of Missoula, Dr. Fritz E. Buchen and Dr. R. F. Owens of Hamilton, and Dr. W. T. Thornton of Stevensville, for the opportunity of studying cases, and much assistance.

The drawings were made by Miss Etta R. Piotti, with the remarkable accuracy characteristic of her work.

1

2

Wolbach. Spotted Fever.

3



4

5

6

7

Wolbach

Spotted Fever.

8

9

10

11

12

14

13

15

16

17

18

19

21

22



20

24

23

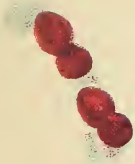

25

26

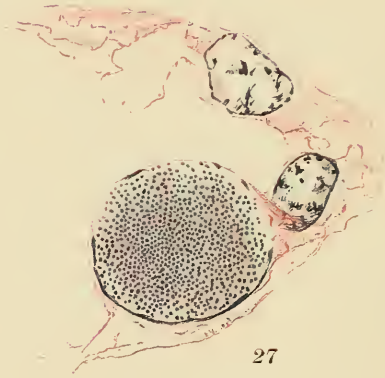

27

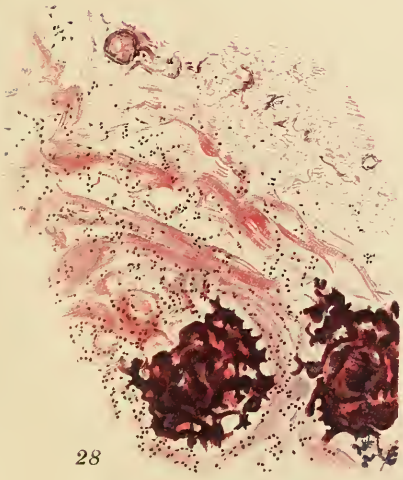

28

Wolbach.

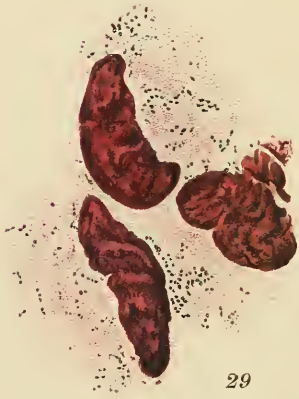

29

Spotted Fever.

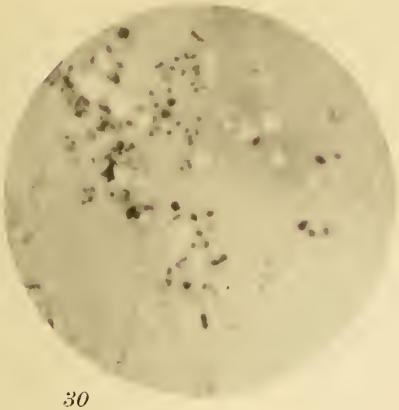

30



31

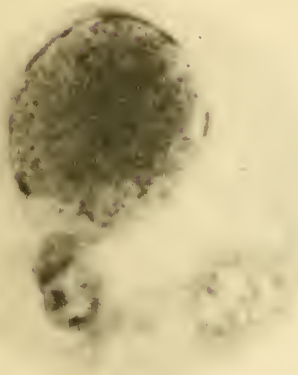

32

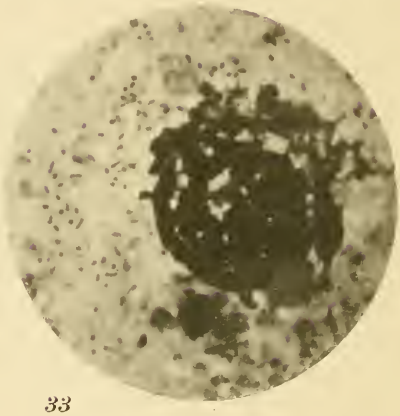

33

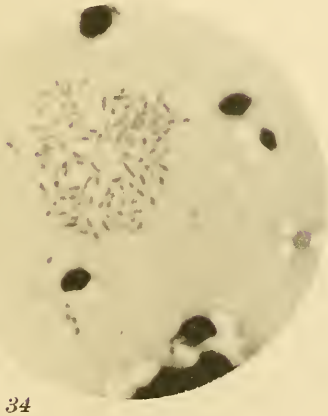

34

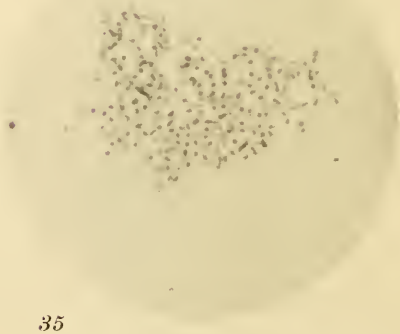

35

36

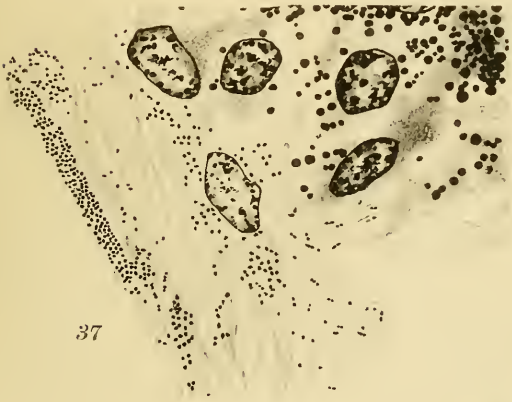

37

38

39

40

Wolbach. Spotted Fever.



41

42

43

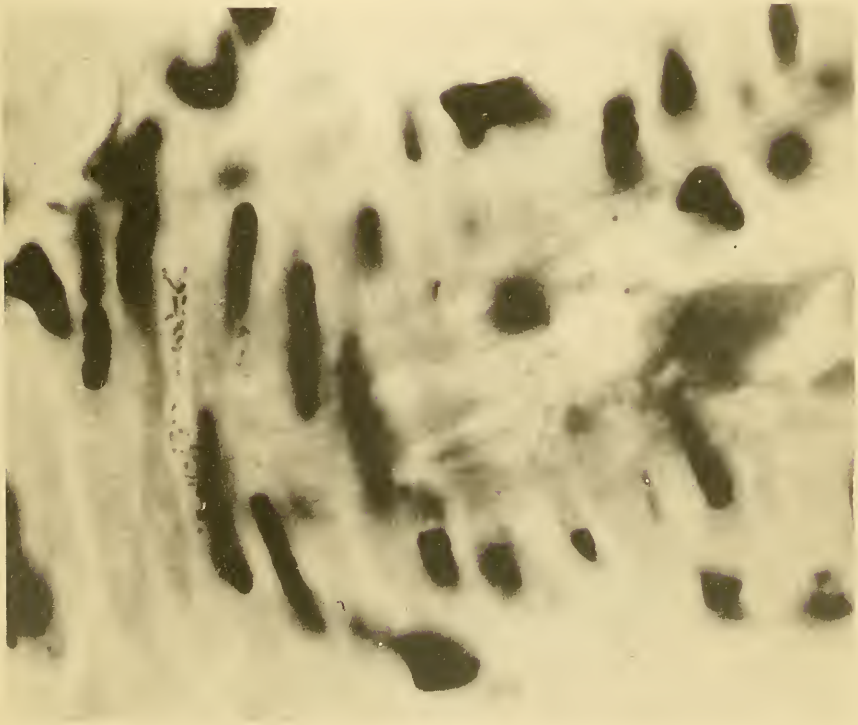

44

Wolbach. Spotted Fever.

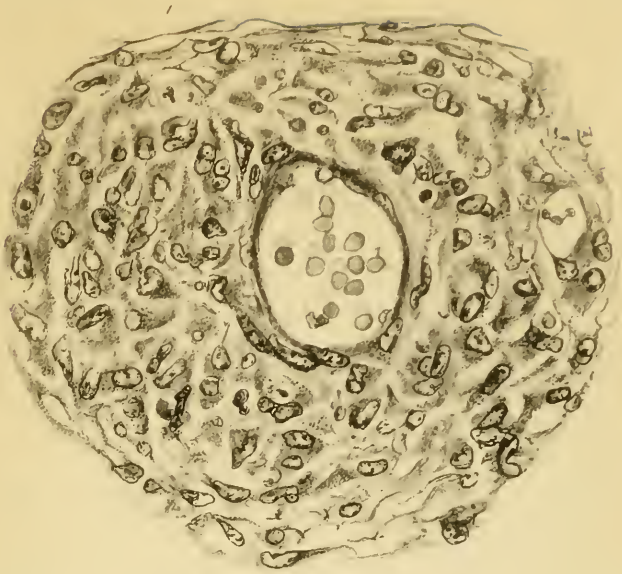

45

46

Wolbach. Spotted Fever.

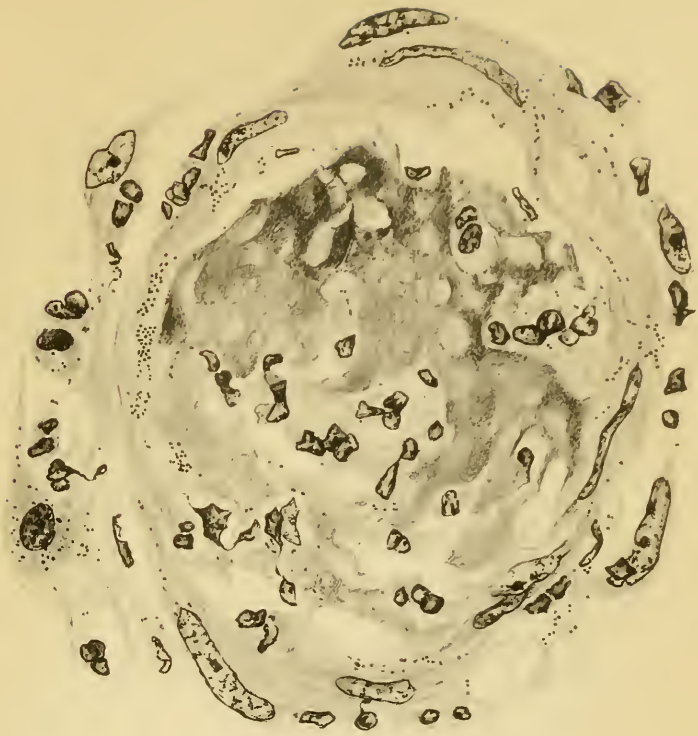

47

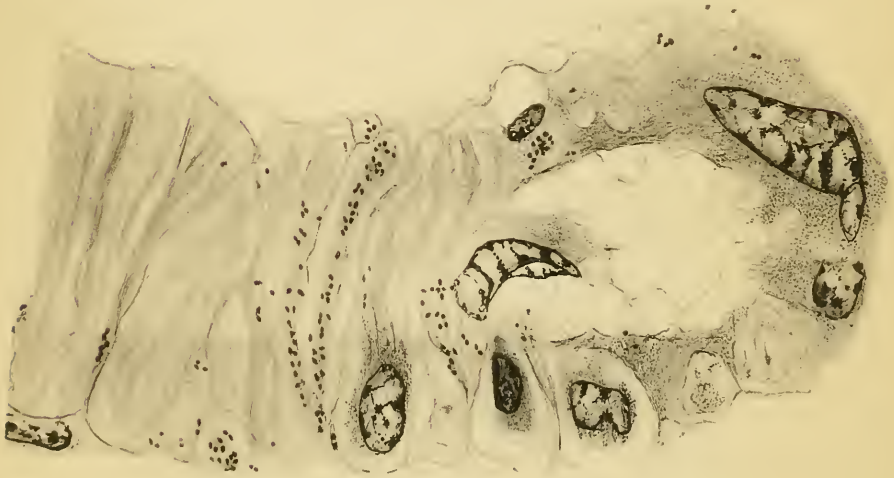

48

Wolbach. Spotted Fever.

49

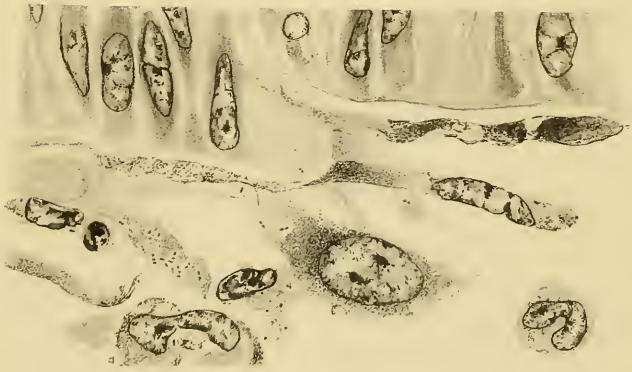

50

Wolbach. Spotted Fever.

51

52

Wolbach. Spotted Fever.

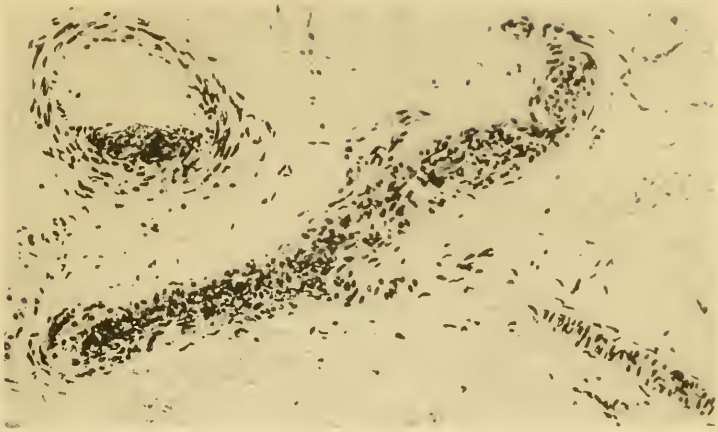

53

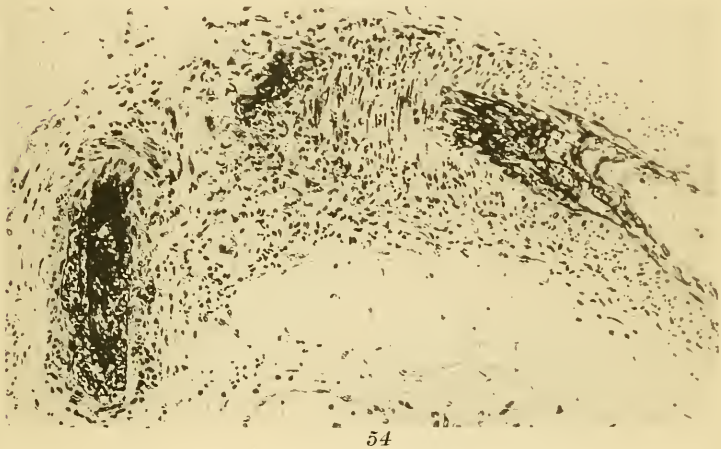

54

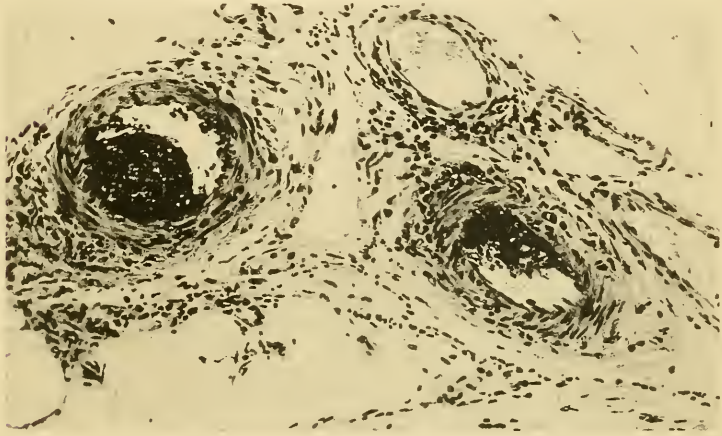

55

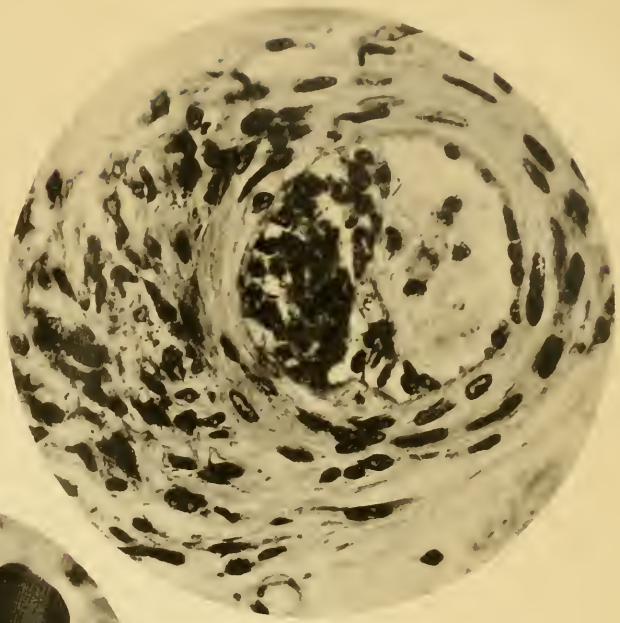

57

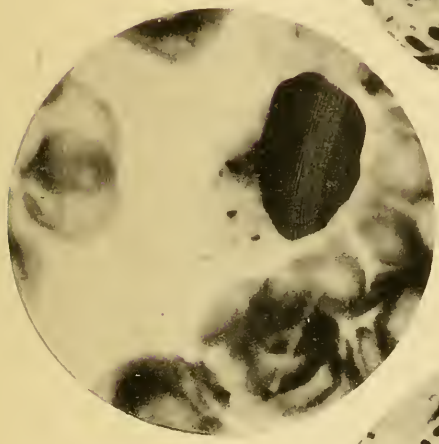

56

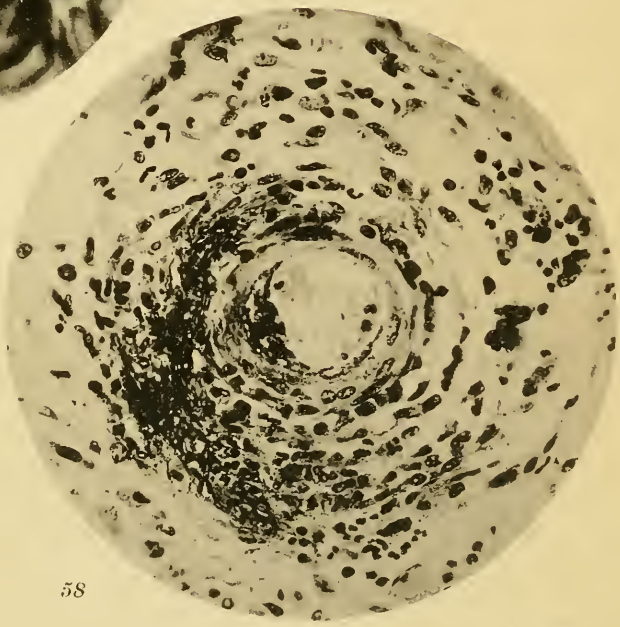

58

Wolbach. Spotted Fever.

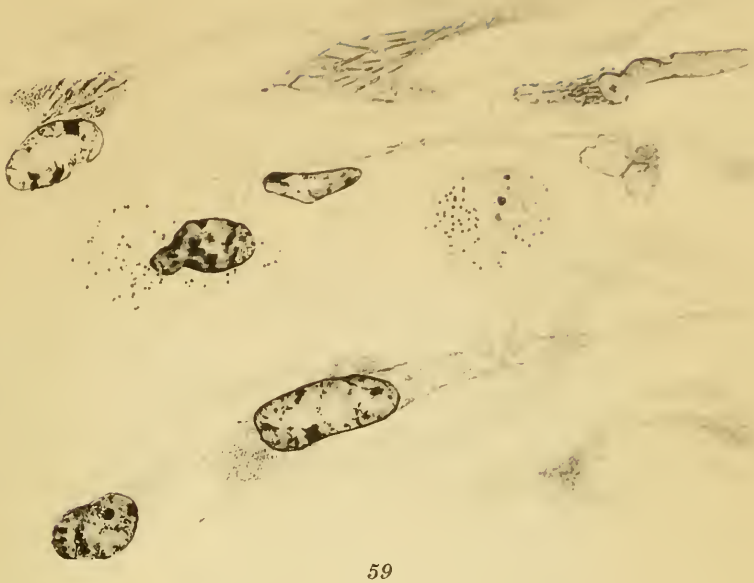

59

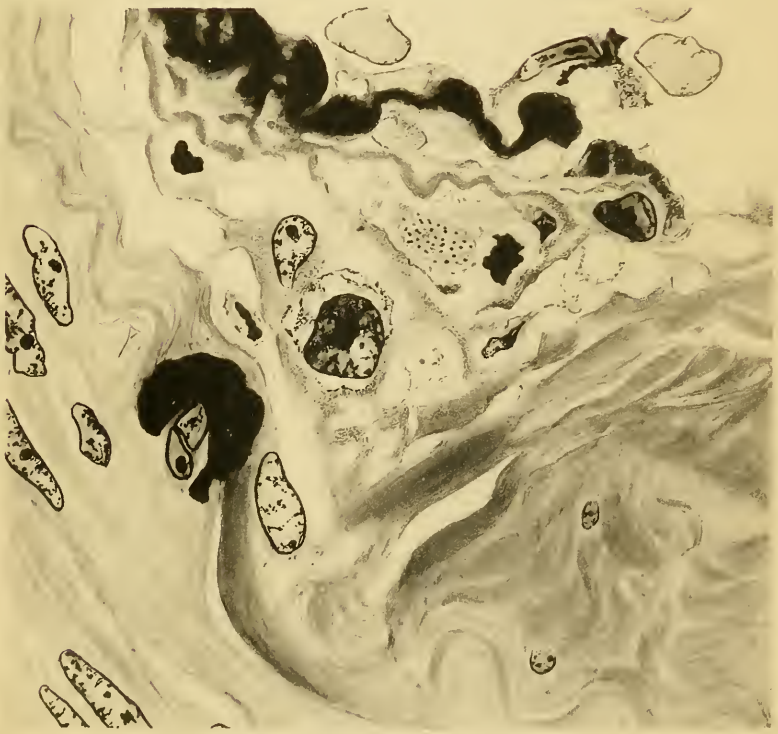

60

Wolbach. Spotted Fever.

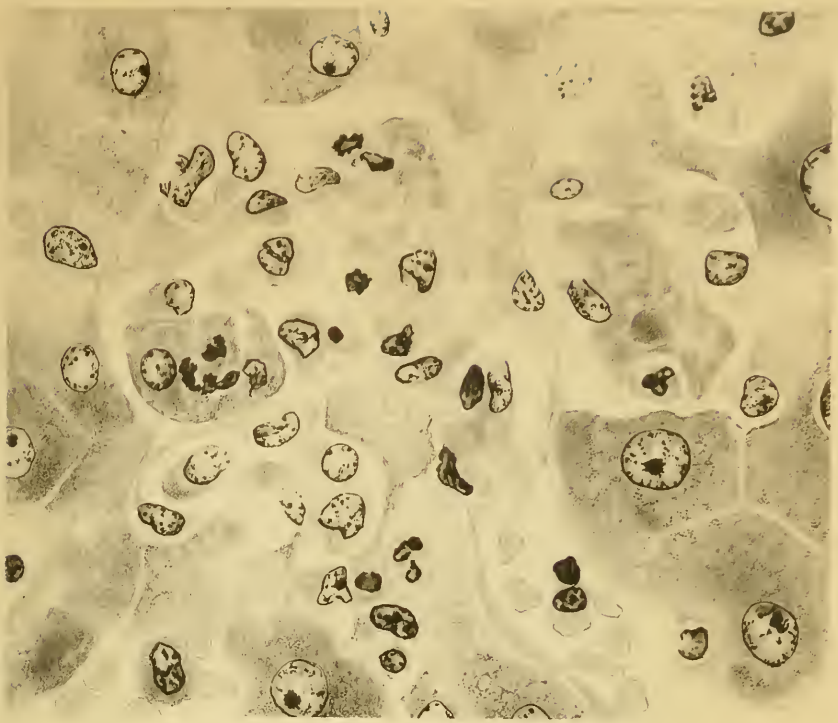

61

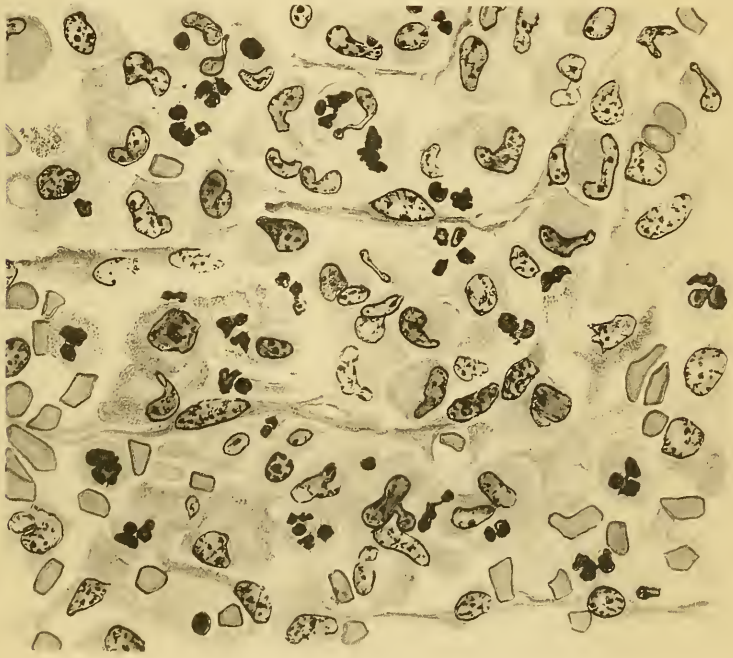

62

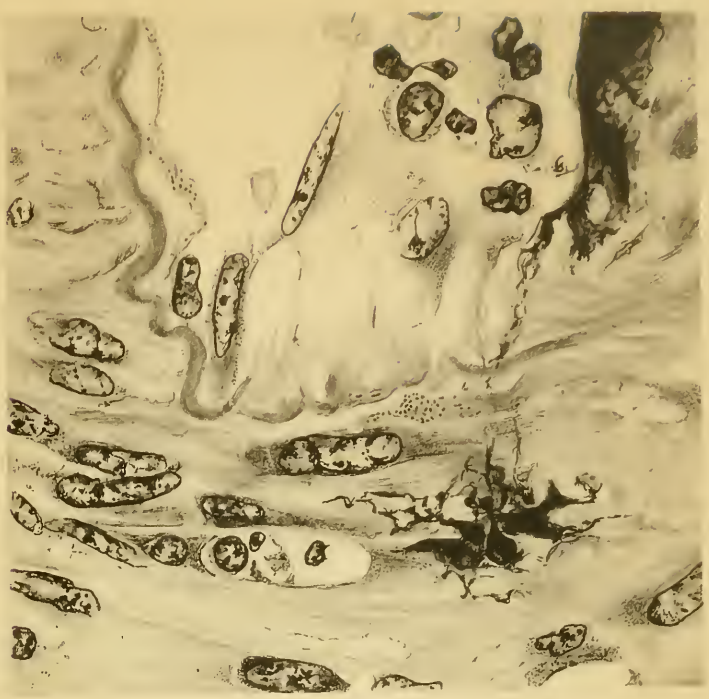

63

64

65

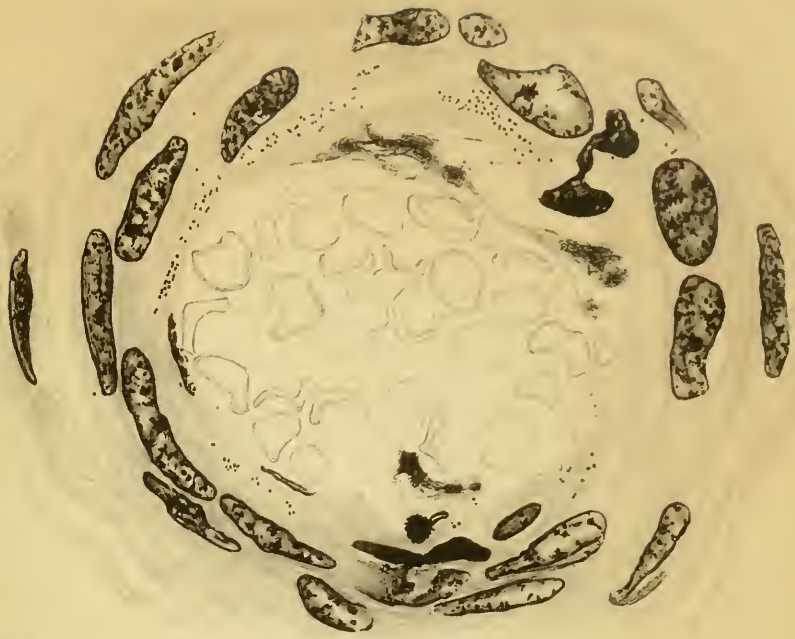

66

67

68

Wolbach. Spotted Fever.

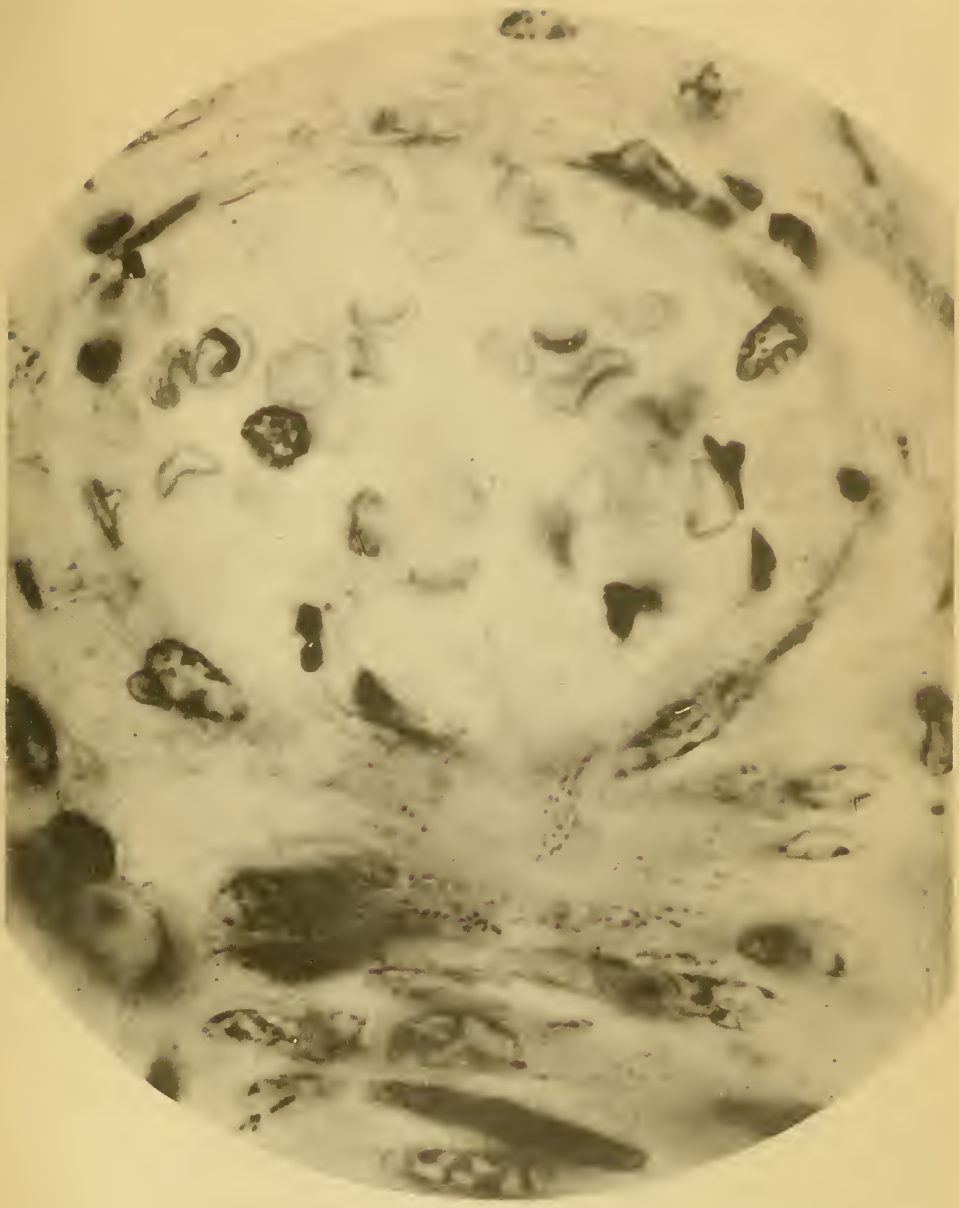

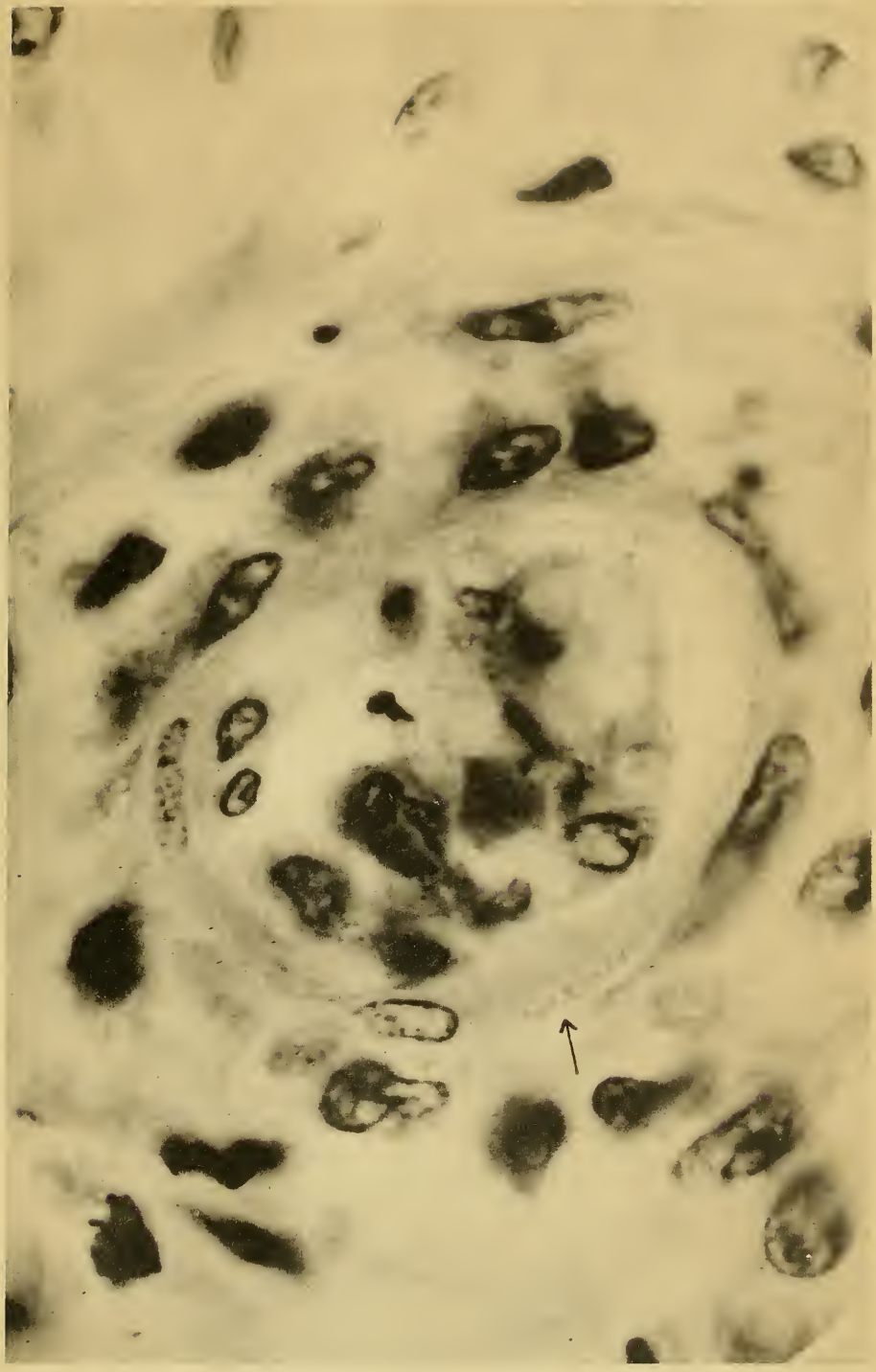

Date Due

11/1/33			
SEP 14 1946			